

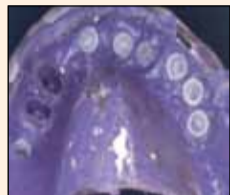DENTAL TRIBUNE

The World's Dental Newspaper • Indian Edition

Published in India

www.dental-tribune.com

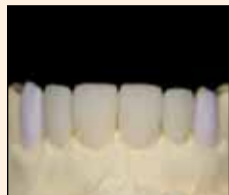Vol. 1 No. 4



Impression and Registration

Impression and registration for full-arch implant dentures

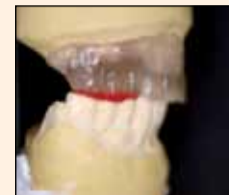Page 4



Daily Digital Dentistry

Welcome to the "Block Party"

Page 8



Implantology

The most important years in implantology
A very personal retrospect

Page 17

Sleep deprivation affects facial appearance

by Dental Tribune International

STOCKHOLM, Sweden: Researchers at the Karolinska Institute in Stockholm have found that sleep deprivation affects features relating to the mouth, eyes and skin. They also suggested that these features function as cues of sleep loss to other people and may thus have significant social consequences.

In order to investigate the facial cues by which individuals recognise that someone is sleep deprived, the researchers photographed the faces of five men and five women after eight hours of normal sleep and after 31 hours of sleep deprivation. Afterwards, 20 male and 20 female participants with an average age of 25 rated the photographs with respect to fatigue, facial cues and sadness.

Overall, the faces of sleep-deprived individuals were perceived as having more wrinkles or fine lines and droopier corners of the

mouth, the researchers reported. The participants also stated that those who had slept less had droopier eyelids, redder eyes, eyes that were more swollen, darker circles under the eyes and paler skin. In addition, sleep-deprived individuals appeared sadder than after normal sleep, and this apparent sadness was related to looking fatigued.

"Since facial regions, such as the eyes and mouth in particular, contain a lot of information on which humans base their interactions with each other, how fatigued a person appears may affect how others behave toward him or her," said Tina Sundelin, lead author and a doctoral student at Stockholm University's Department of Psychology.

The study, titled "Cues of fatigue: Effects of sleep deprivation on facial appearance", was published in the September issue of the SLEEP journal.^[1]



Facial appearance can affect judgement of attributes such as trustworthiness, aggressiveness and competence. (Photo: Kiefer pix/Shutterstock)

Coconut oil could reduce dental caries



Irish researchers have found that coconut oil has potential as a marketable antimicrobial for inclusion in health-care products. (Photo courtesy of magicinfo/Shutterstock)

ATHLONE, Ireland: Researchers think that coconut oil may be of great interest to the oral health industry in the future because a new study has found that its natural antibiotic properties strongly inhibit the growth of bacteria that cause oral infections. The researchers suggest that the oil could be integrated into commercial dental consumer products to combat tooth decay.

In particular, the researchers discovered that coconut oil that had been treated with enzymes similar to those found in the digestive tract was most effective in blocking the development of most strains of Streptococcus bacteria, including Streptococcus mutans, which is a major cause of tooth decay.

Additional tests revealed that

the same enzyme-modified variant of coconut oil was also harmful to Candida albicans, the yeast that causes oral thrush, among others.

"Dental caries is a commonly overlooked health problem affecting 60 to 90 per cent of children and the majority of adults in industrialised countries," said Dr Damien Brady, who lectures in Microbiology, Environmental Science and Veterinary Medicine. "Incorporating enzyme-modified coconut oil into dental hygiene products would be an attractive alternative to chemical additives, particularly as it works at relatively low concentrations," he added.

The research was carried out at the Athlone Institute of Technology's Bioscience Research Institute.

The findings were presented on 3 September at the Society for General Microbiology's autumn conference at the University of Warwick.^[2]

Dolonex[®]

piroxicam[®]

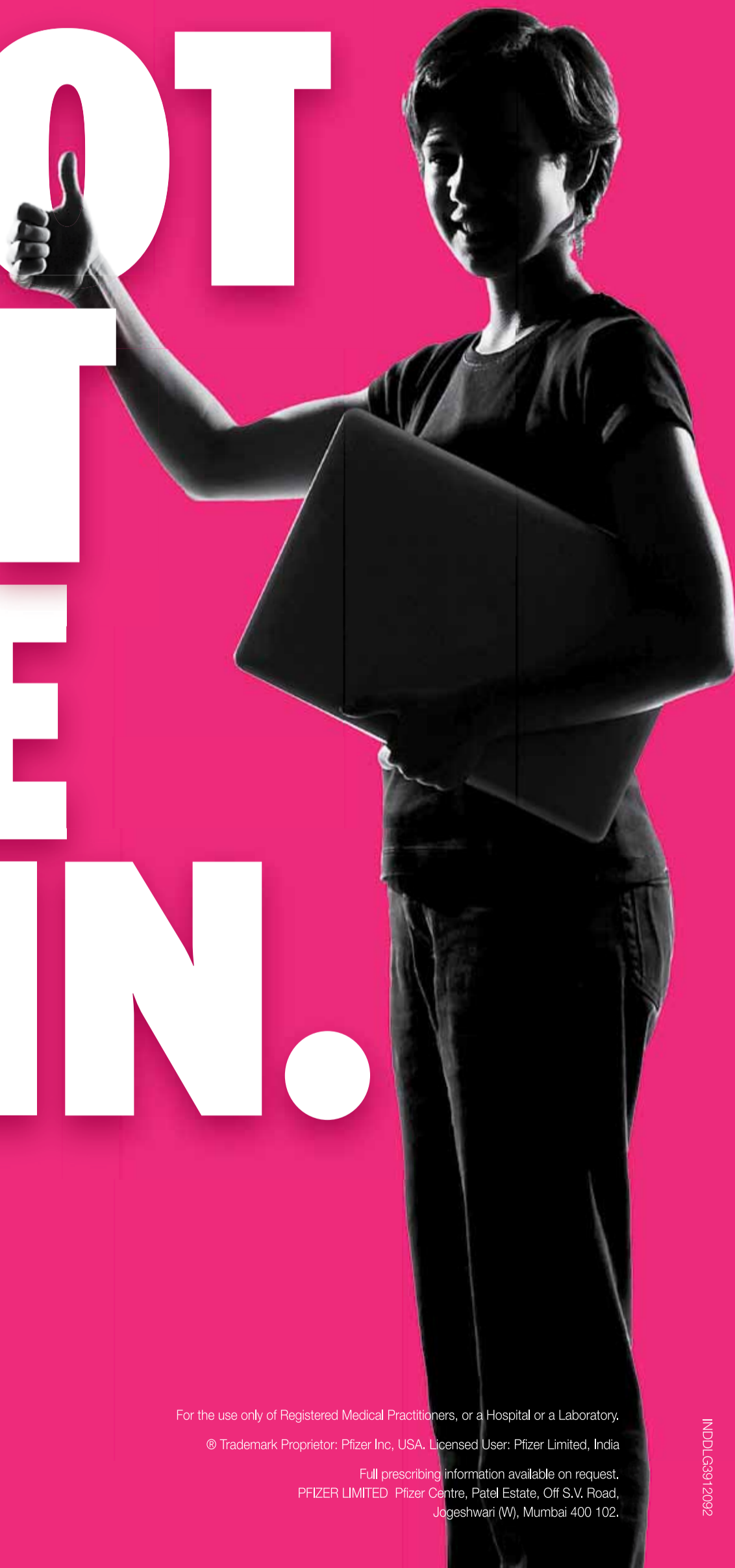IM 40 mg/
2 ml

DT 20 mg

Gel 5 mg/
gm

HELP YOUR PATIENTS

**ROOT
OUT
THE
PAIN.**



Working together for a healthier world™

For the use only of Registered Medical Practitioners, or a Hospital or a Laboratory.

© Trademark Proprietor: Pfizer Inc, USA. Licensed User: Pfizer Limited, India

Full prescribing information available on request.
PFIZER LIMITED Pfizer Centre, Patel Estate, Off S.V. Road,
Jogeshwari (W), Mumbai 400 102.

INDDLG912092

Interview: 'The patient should be told the truth'



(DTI/Photo courtesy of UCL Eastman Dental Institute, UK)

Daniel Zimmermann, DTI

Detecting and managing potentially malignant diseases of the mouth still pose challenges to dental professionals worldwide. In Istanbul, Dental Tribune ONLINE had the opportunity to speak with FDI presenter Prof. Stephen Porter from the UCL Eastman Dental Institute in London about new risk factors, prevention strategies and why actor Michael Douglas is not a good poster boy for changing awareness of throat and mouth cancer.

Dental Tribune ONLINE: A recent study on Turkish dental patients in central Anatolia has shown that only one in two people are aware of oral cancer. Are these results representative of most people's knowledge about the condition nowadays?

Prof. Stephen Porter: It is not uncommon for individuals not to be aware that cancer can arise in the mouth. Indeed, there are studies indicating that even patients without cancer who attend clinics that specialise in mouth cancer are unaware of the possibility. This trend regarding a lack of awareness occurs across the globe, although it varies between countries.

With celebrities like actor Michael Douglas struggling publicly with the disease, do you think awareness of malignant diseases of the mouth is increasing?

Undoubtedly, it will increase. When a celebrity announces that he or she has a particular disorder, there is often an upsurge of referrals by concerned individuals. In the UK, this was perhaps best illustrated when Freddie Mercury declared that he had HIV. There was a substantial rise in the number of persons seeking advice and/or testing for the disease in the aftermath.

A fair number of famous people have had oral cancer, including Sigmund Freud, Ulysses S. Grant

and TV producer Aaron Spelling to name but a few. In the UK, journalist and first husband of TV cook Nigella Lawson John Diamond wrote a series of articles detailing the progress of his disease and its treatment that informed many of the impact this disease can have on an individual and his or her family.

Unfortunately, the Michael Douglas situation has perhaps confused the exact role of the human papillomavirus (HPV) in mouth cancer. Certainly, it can cause mouth cancer and it can be acquired through orogenital contact, but there is no evidence that such contact will lessen any subsequent risk of contracting mouth cancer.

Oral cancer figures are rising worldwide. What are the reasons for this, and does it fulfil the criteria for an epidemic, as it has been called in some media reports?

An epidemic is defined as new cases of a disease in a given human population over a particular period. It often has an emotive element to it. Oral cancer certainly is on the increase in the developed world, although the number of new cases is falling in some parts of the globe, notably parts of India.

The rise in some countries is gradual but sustained. Smoking tobacco and/or drinking alcohol are the two factors that traditionally have given rise to mouth cancer. In addition, individuals are now acquiring cancer-causing (oncogenic) types of HPV, probably via orogenital contact. This burst of infectious disease, or indeed sexually transmitted infection, is not a new phenomenon, but it has become much more manifest in the last 30 years. So, what is new is probably that oncogenic types of HPV are just more common in the sexually active population than in the past.

The exact risk that it carries is unclear but it has been suggested that the risk of HPV-related mouth and/or throat cancer climbs when someone has had more than nine different sexual partners.

What other factors besides smoking, drinking and HPV are currently being investigated, and what is their malignant potential?

People chew betel nut preparations (e.g. paan masal and gutka) in parts of India, Pakistan, Bangladesh and surrounding areas. These cause initial fibrosis of the oral tissue, termed "submucous fibrosis", which carries a high risk of causing oral cancer of possibly 30 per cent. Submucous fibrosis can arise even in young individuals and is irreversible, and thus patients are likely to have a lifelong risk of mouth cancer, even if they stop the causative habit. The nightmare scenario is that when examining a patient with submucous fibrosis the mouth opening can be so small that a clinician may be unable to see the cancer.

Mouth cancer can also arise in patients who have rare genetic disorders, such as Fanconi anaemia and dyskeratosis congenita, but the most common oral disorder that is considered to be potentially malignant is oral lichen planus. This is a global disorder that typically occurs in middle-aged and older women. It is a chronic immune disorder that may cause painless white patches that sometimes are accompanied by painful erosions or ulcers. It affects about 1 to 2 per cent of the population and is the most common disorder to affect the lining of the mouth (the oral mucosa).

It has been suggested that 1 to 2 per cent of patients with oral lichen planus will develop mouth cancer, but this risk is highly unpredictable because it does not appear to be consistently associated with the duration or type of treatment of the lichen planus, nor the age or sex of the patients, nor their alcohol or tobacco habits. The good news, perhaps, is that 98 to 99 per cent of patients with oral lichen planus will not contract mouth cancer.

Isolated white or red patches on the oral mucosa (sometimes termed "leukoplakia" and "erythroplakia") have malignant potential as well, but these are actually uncommon, particularly the latter, compared with oral lichen planus.

Besides new treatment concepts, prevention remains the most effective strategy against oral cancer. Why do so many dentists still appear to overlook obvious signs of the disease, and do current screening procedures have shortcomings?

The great majority of patients ultimately found to have mouth cancer will have been referred to a specialist service because a dentist or other dental professional will have noticed something abnormal. He or she might not have known what it was, but they did the correct thing by referring the patient to a specialist.

Screening for possible mouth cancer is straightforward. It is just

a matter of examining the neck and mouth carefully. However sometimes dentists do not know what to look for, as they have probably never seen more than one type of oral cancer in their professional lives.

Similarly, mouth cancer is more likely in socio-economically deprived groups than the wealthy. Socially disadvantaged people have a tendency not to attend health care providers, including dentists, on a regular basis nor to take up possible screening opportunities for common diseases and therefore have a variable awareness and practice of disease prevention strategies, whether concerning oral health or general health.

Clearly, the best option for screening would be opportunistic screening, where health care staff examine patients in risk groups for a particular disease, but this requires people to want to attend a clinic and to appreciate the possible benefits of such attendance for their health and well-being.

Is there any evidence that regular screenings could help prevent oral cancer?

There is no evidence that a particular frequency of dental examination will lessen the risk of mouth cancer. However, the more regularly a person is examined, the greater the

chance that emerging malignant or potentially malignant disease will be detected and that any lesion present will be small.

However, overzealous review is likely to be wasteful and thus all patients should be advised that if they become aware of a change in their gingivae or oral mucosa that persists for more than three weeks and has no obvious local cause, or example a sharp tooth or filling, they should seek advice from their dentist.

In its 2008 policy statement, the FDI stresses the important role of dental professionals in the detection of oral cancer and patient education. To what extent are dental professionals fulfilling this role?

The majority of patients ultimately found to have oral cancer will have been identified by a dentist or other dental professional; thus, dental professionals are fulfilling this role to a great extent. However, dental professionals should also be able to provide advice about oral cancer prevention, for example tobacco and alcohol cessation, and information on where additional advice can be obtained, for example tobacco cessation services.

The current rule of thumb is that the more people smoke and the longer that habit the greater the risk

International Imprint

Licensing by Dental Tribune International Publisher Torsten Oemus

Group Editor
Daniel Zimmermann
newsroom@dental-tribune.com
+49 341 48 474 107

Clinical Editor
Magda Wojtkiewicz

Online Editors
Yvonne Bachmann
Claudia Duschek

Copy Editors
Sabrina Raaff
Hans Motschmann

Publisher/President/CEO
Torsten Oemus

Director of Finance & Controlling
Dan Wunderlich

Business Development Manager
Claudia Salwiczek

Media Sales Managers
Matthias Diessner (Key Accounts)
Melissa Brown (International)
Peter Witteczek (Asia Pacific)
Maria Kaiser (USA)
Weridiana Mageswki (Latin America)
Hélène Carpentier (Europe)

Marketing & Sales Services
Esther Wodarski
Nicole André
Accounting
Karen Hamatschek
Anja Maywald
Executive Producer
Gernot Meyer

Dental Tribune International
Holbeinstr. 29, 04229 Leipzig, Germany
Tel.: +49 341 48 474 302 | Fax: +49 341 48 474 173
www.dental-tribune.com
info@dental-tribune.com

Regional Offices

Asia Pacific
Dental Tribune Asia Pacific Limited
Room A, 20/F, Harvard Commercial Building,
105-111 Thomson Road, Wanchai, Hong Kong
Tel.: +852 3113 6177 | Fax: +852 3113 6199

The Americas
Tribune America, LLC
116 West 23rd Street, Ste. 500, New York, N.Y.
10011, USA
Tel.: +1 212 244 7181 | Fax: +1 212 244 7185

Dental Tribune Indian Edition

Published by Jaypee Brothers Medical Publishers (P) Ltd., India

© 2013, Dental Tribune International GmbH. All rights reserved.

Dental Tribune India makes every effort to report clinical information and manufacturer's product news accurately, but cannot assume responsibility for the validity of product claims, or for typographical errors. The publishers also do not assume responsibility for product names or claims, or statements made by advertisers. Opinions expressed by authors are their own and may not reflect those of Dental Tribune International.

Chairman DT India
Jitendar P Vij
jaypee@jaypeebrothers.com
Director
P N Venkatraman
venkatraman@jaypeebrothers.com

Dental Tribune India

Published by: **Jaypee Brothers Medical Publishers (P) Ltd.**
4838/24, Ansari Road, Daryaganj
New Delhi 110002, India
Phone: +91 11 43574357
Email: jaypee@jaypeebrothers.com
Website: www.jaypeebrothers.com

Impression and registration for full-arch implant dentures

Author_Prof. Gregory-George Zafiropoulos, Germany

Introduction

Usually, a full denture is delivered following tooth extraction or implant insertion of a fully edentulous arch. A denture is usually used until the final restoration is performed. A well-designed full denture should fulfill the following criteria: 1) correct vertical height and maxilla-mandibular relationship; 2) accurate occlusion; 3) appropriate choice of teeth with regard to shape, length, width and position; 4) adequate lip support, and 5) proper function and aesthetics to meet the patient's expectations. The final restoration should fulfill or surpass these requirements. Obtaining a correct impression and accurately evaluating the interocclusal relationship (e.g., interocclusal distance, occlusal recording and determination of the exact position of the placed implants) are often challenging and time-consuming tasks.¹

The aim of the current report is to present an impression and registration technique that allows the transfer of the interocclusal relationship, occlusal recording and esthetics that were initially applied to produce a full denture as a template for the reconstruction of the final full-arch implant.

Materials and Methods

Following multiple extraction of a non-salvageable rest dentition and the placement of six dental implants in positions #4, #5, #6, #11, #12, #13, a full denture was fabricated. After the extraction sites had healed and denture sores were eliminated, the function and esthetics of the denture was optimized. If necessary, angulations, shape and color of the denture teeth and the shape of the denture base were corrected (Fig. 1a). The resulting denture was used by the patient until the final restoration was delivered. For the final restoration of the maxilla, an implant-retained denture with telescopic crowns as attachments was planned.

After the implant was uncovered, the denture was modified to allow sufficient space for the healing abutments. A duplicate of the denture

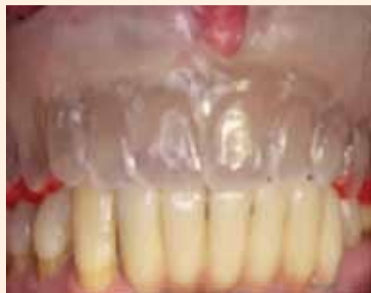

Figure 1C: Trial of the DentDu.

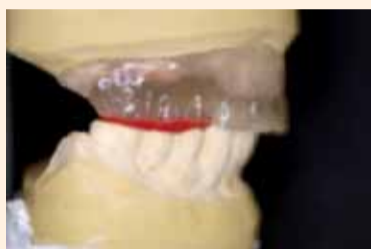

Figure 2A: Placement of the DentDu in the articulator.



Figure 2B: Pick-up impression system. On the left: titanium impression post (placed on the implant). On the right: plastic impression sleeve (will be left in the impression).

(DentDu) was made out of clear resin (Paladur, Heraeus, Hanau, Germany, Fig. 1b). A trial of the DentDu was performed and minor occlusal discrepancies were corrected (Fig. 1c). Bite records were taken in centric occlusion with modeling resin (pattern resin®, GC, Alsip, IL; Fig. 1c), using the casts of the original denture. Afterwards, the DentDu was placed in an articulator and a controlling of the occlusion was made (Fig. 2a) with the bite records. A pickup transfer system consisting of a titanium impression post and a plastic impression sleeve was employed (Dentegris, Duisburg, Germany, Fig. 2b). The DentDu was carefully modified by creating internal clearance in the area of the implants so that it could be applied as an individualized custom tray. This permitted it to be fully seated when the impression posts were in place. Impressions were generated by a polyether material (Impregum, 3M ESPE, St. Paul, MI). During this process, the DentDu was kept in centric occlusion using the bite records (Fig. 3a).

The titanium impression posts were connected with the implant analogues and with the plastic impression sleeves (Dentegris), which were embedded in the impression material (Fig. 3b). A master cast was then fabricated and articulated with the help of the bite records (Fig. 3c, Figs. 4a & 4b).

Customizable abutments (Dentegris) were taken to fabricate the implant abutments. Parallelism, angulation, position and shape of the implant abutments were determined using a silicon key fabricated from a

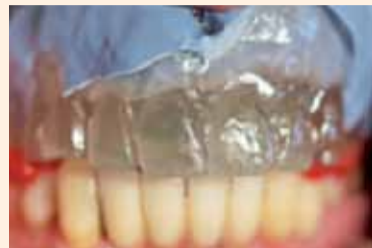

Figure 3A: Taking the impression with the DentDu. The bite records were used to determine the exact position.

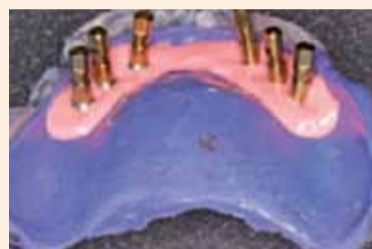

Figure 3B: Fabrication of the master cast.

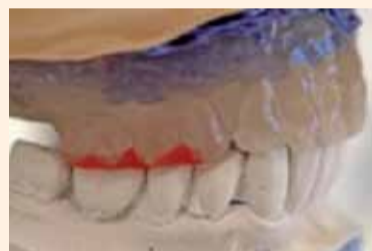

Figure 3C: Placement of the cast into the articulator using the bite registrations.

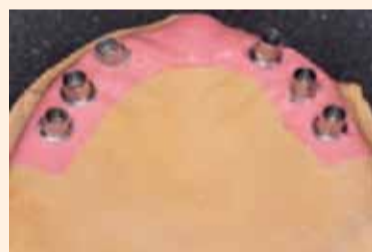

Figure 4A: Master cast.

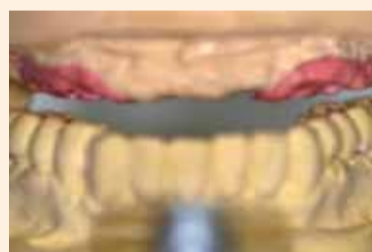

Figure 4B: The master cast is placed into the articulator.



Figure 5: The customized implant abutments are fabricated using a matrix of C-silicone.

matrix of C-silicone (Zeta-labor, Zhermack SpA, Badia Polesine, Italy, Fig. 5). The dentist and the dental technician relied on two alternatives for customized abutments selection: 1) UCLA customizable abutments (UCLA, Dentegris) for casting with a gold alloy (for example, Portadur P4, Au 68.50 %, Wieland, Pforzheim, Germany, Fig. 6a) or 2) platinum-



Figure 6A: Gold customized abutments.



Figure 6B: Chromium cobalt (CrCo) customized abutments.



Figure 6C: Electroformed gold copings.

iridium customizable abutments (PTIR, Dentegris) for casting with a chromium cobalt (CrCo) alloy (for example, Ankatit, Anka Guss, Waldaschaff, Germany, Fig. 6b).

After casting, the customized implant abutments were grinded, polished and served as the basis for the fabrication of electroformed puregold copings with a thickness of 0.25 mm (AGC Galvanogold, Au > 99.9 %, Wieland, Fig. 6c).²⁻⁴ The framework was then constructed via CAD/CAM. To ensure proper functioning of the framework, a plastic mock-up and a temporary fixed denture (TFD) were milled (ZENOPMMA, Wieland). The customized implant abutments, the electroformed copings, the mock-up and the TFD were delivered by the dental laboratory for the next clinical session.

The abutments were transferred, positioned on the implants and

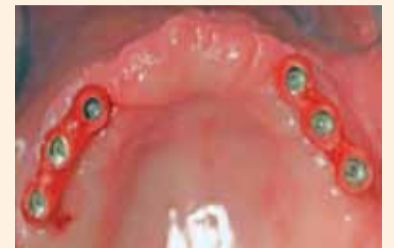

Figure 7A & B: The customized abutments are mounted on the implants using a transfer key.

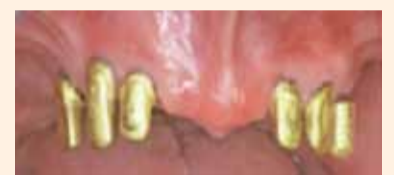

Figure 7C: Electroformed gold copings in situ.

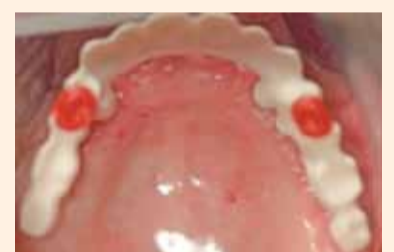

Figure 8A & B: Trial of the mock-up.

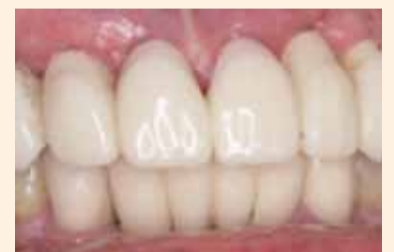

Figure 8C: Temporary fixed denture in situ.

torqued to 35 Nm using a resin transfer key (pattern resin, GC; Figs. 7a & b). From this point on, the customized abutments remained fixed in order to avoid any possible inaccuracies. The electroformed copings were placed on the implant abutments (Fig. 7c). The mock-up was placed over the electroformed copings and the occlusion was checked with the bite records (Figs. 8a & b). A final impression with a polyether impression material (Impregum, 3M ESPE) was taken with electroformed copings. The mock-up was further set up and used for the fabrication of a new (final) master cast. After the impression was taken, the TFD was fixed on the implant abutments using temporary cement (TempBond, Kerr, Orange, CA). It was then left in place until the delivery of the final restoration (Fig. 8c).

The new master cast was articulated with the help of the gold copings and the mock-up. The metal framework

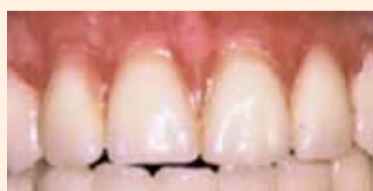

Figure 1A: Full denture in situ.

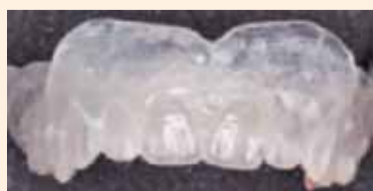

Figure 1B: Duplicate (DentDu) of the interim denture.

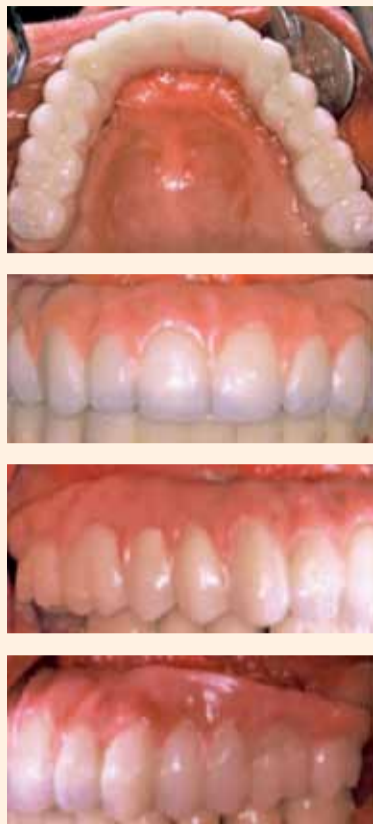

Figure 9A–D: Final telescopic crown retained implant denture, palatal; (a), anterior teeth (b), right side (c), left side (d).

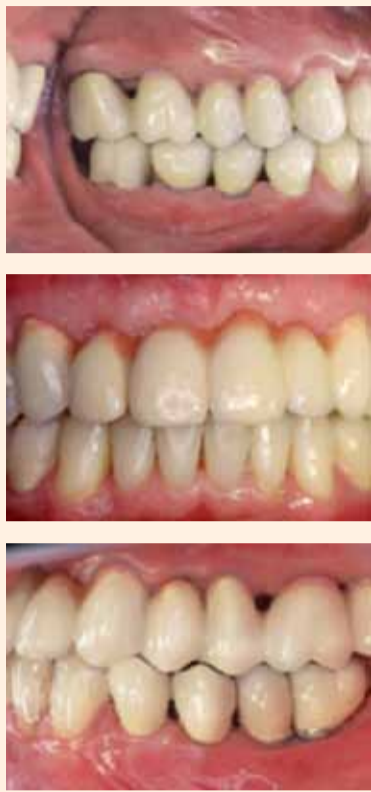

Figure 12A–C: A case of fixed-implant retained denture for the maxilla full-arch rehabilitation, right site (a), anterior area (b), left site (c).

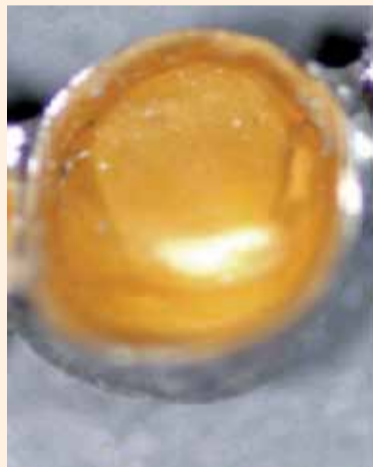


Figure 10: Placement of the electroformed copings into the frame.

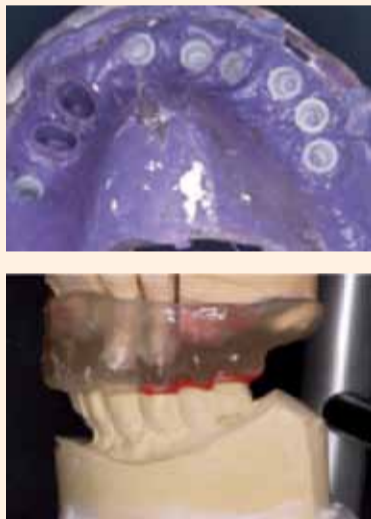

Figure 13A–C: Impression of a case with natural dentition (teeth #11 and #12) and implants. Master cast in the articulator with a duplicate of the over-denture in place (b). Gold copings fixed on the remaining teeth #11 and #12 and customized implant abutments mounted on the implants (both of them served as primary telescopes (c).

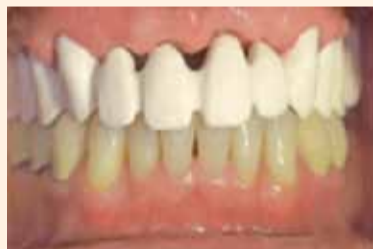

Figure 11A & B: A case of fixed implant retained denture for the maxilla full-arch rehabilitation: trial of the mock-up (a) and the milled temporary fixed denture is placed on the abutments (b).

was milled (here: Titanium Zenotec TI, Wieland, Fig. 9a). The veneering of the superstructure was made using a light-cured indirect ceramic polymer (Ceramage, SHOFU, Menlo Park, CA, Figs. 9a–d). The electroformed gold copings were fixed in

the metal framework using a self-curing compomer cement (AGC Cem, Wieland, Fig. 10).

The above-described procedures can be also performed in cases in which a fixed denture was planned for the rehabilitation of the full-arch (Figs. 11a & b, Figs. 12a–c) and in cases where part of the natural dentition is periodontally stable and can be applied as abutments. In these cases, the immediate full denture can be

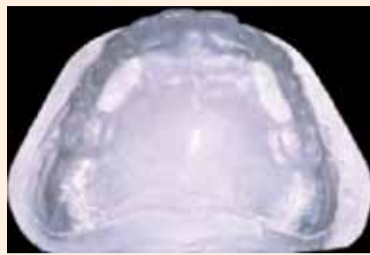

Figure 14: DentDu modified for open-tray impression technique.

designed as a cover denture. From this cover denture, a DentDu could be fabricated and further used as described above (Figs. 13a–c).

Porcelain is a possible material for veneering of fixed-denture frameworks. If the angulation of the implants does not allow for taking impressions in the above-described way and an open-tray impression is preferable, fenestrations can be fabricated into the DentDu (Fig. 14).

Discussion

The reconstruction of the fully edentulous arch with implant-retained dentures necessitates thorough planning and a precise and passive fit of the suprastructure. A previous study demonstrated that a passive fit between the implant superstructure and the underlying abutments is essential for the long-term success of the implant prosthesis.⁵ To achieve a passive fit, an accurate positioning of the implant replicas in the master cast must be assured. The impression technique and the splinting of the implant copings are factors which may contribute to errors in the final positioning of the implant analogs, thus leading to inaccuracies in the fit of the final superstructure.^{5–10} Furthermore, the angulation or proximity of the implants may inhibit proper seating of the impression copings and/or caps, which may also have a detrimental effect on the registration of the implant position.¹¹

The precise recording of the maxillo-mandibular, e.g. interocclusal, relationship is a prerequisite for achieving proper occlusion and a successful treatment outcome.¹⁰ The initially delivered denture allowed for the correction of the interocclusal relationship, tooth shape and color and angulations during the entire healing period. In this way, the patient was able to acclimatize to the function and esthetics of the denture. In the method described in this report, an accurate impression and recording of the full denture was achieved by using a duplicate as a custom tray for the impression. Therefore, it was not necessary to repeat all the steps usually needed for recording the interocclusal relationship, e.g. wax-up, etc., at the time of the fabrication of the final restoration.

If an open-tray impression is preferred, only minor changes to the procedure are necessary. This method is based on a previous publication.¹² In cases such as this, it is advisable to fabricate two DentDus. The impression can be taken by the first DentDu; the second DentDu is used for the remaining steps. Customized abutments are applied instead of a bar, galvano copings allow a precise transfer coping, and secondary telescopes as well as different technologies are employed for the transfer of implant positions and for the construction of the superstructure.

Customized implant abutments allows for better angulations and shape, for improved occlusal force transmission from the crown to the implant and the bone, and also for facilitating the fabrication of an esthetically pleasing implant-supported denture. Ways in which abutment design contributes to improved esthetics include changes in the location of the crown and changes in the dimension and/or form of the restorative platform.

Additionally, features of the abutment design contribute to the health and dimensional stability of the soft tissue. Current attempts to objectively define implant-restoration esthetics have focused on periimplant mucosal parameters.^{13,14} The introduction of the UCLA abutment provided a custom solution for implant restorations. This direct-to-implant restoration concept provided adaptability. Through waxing and casting, the height, diameter and angulations can be addressed in order to provide a wide range of clinical solutions for problems associated with limited interocclusal distance, interproximal distance, implant angulations and related soft tissue responses.¹⁵

The customized implant abutments served as primary telescopes, and the electroformed copings served as secondary telescopes in cases where a removable denture with telescopic crowns was used as the attachment. Electroformed gold copings are associated with several advantages, in conjunction with both removable and fixed restorations. The galvano-forming and electroforming process yielded a precisely-fitted secondary coping for the implant abutment with a gap of only 12–30 µm. The gold electroformed coping saves space and is made of high-quality material.^{2–4} Using gold copings for the impression allows for the exact transfer of the form, angulations and position of the inserted customized implant abutments.

With the help of the milled mock-

up, the future fit of the CAD/CAM fabricated framework can be evaluated and necessary changes in the shape of the restoration and occlusion can be made. Making these changes on the mock-up was easier and less time consuming than making them on the metal framework itself, and it was then possible to transfer them directly to the final framework. Furthermore, the mock-up almost “splinted” the electroformed gold copings during the impression, allowing for the exact transfer of the abutment position. At the same time, the vertical height and interocclusal relationship were recorded. The delivery of a milled temporary restoration permitted a slow and non-progressive loading of the implants, which then leads to bone remodeling.¹⁶ Abutments were left in place after mounting. Combined with the fabrication of a new cast, this further decreased the risk of inaccuracies during the transfer process.

Conclusion

The method described here can be used for full-arch restorations with both fixed and removable implant supported dentures. Accurate impressions can be accomplished and occlusion, vertical dimensions, as well as implant positions can be transferred while facilitating the full-arch restoration process. In addition, this technique resulted in a reduction of the required chair time.

Disadvantages of this technique lie in the fact that the quality of laboratory technician's work meets higher demands than usual, and that the clinician also needs to acquire some additional skills. Further disadvantages of this method include the need for a highly qualified technical lab and higher technical costs relative to those associated with prefabricated titan implant abutments.

To date, this method has not been applied in conjunction with immediate implant loading. However, dentists and patients have come to expect this level of rehabilitative accuracy, precision, long-term success and aesthetics.¹⁷

Editorial note: A complete list of references is available from the publisher.

Contact Info

Dr Gregory-George Zafiropoulos
Blaues Haus, Sternstr. 61
40479 Dusseldorf, Germany
zafiropoulos@prof-zafiropoulos.de
www.prof-zafiropoulos.de

of mouth cancer. The same applies to alcohol. There are some nuances as regards the type of tobacco or alcohol that may affect risk but these are really not of notable concern when communicating a disease prevention message. Of significance is that the risk of cancer developing if someone smokes and drinks is much higher

than if someone smokes or drinks (i.e. there is a synergistic rather than additive effect).

Of course, many dentists will indicate that they have no experience of having seen oral cancer or having managed any patient who has previously had such disease. However, there

are some simple rules. If a lesion is solitary, has been present for more than three weeks and has no local cause, the patient should be referred. Any lesion that strikes a dental professional as odd and/or destructive warrants referral.

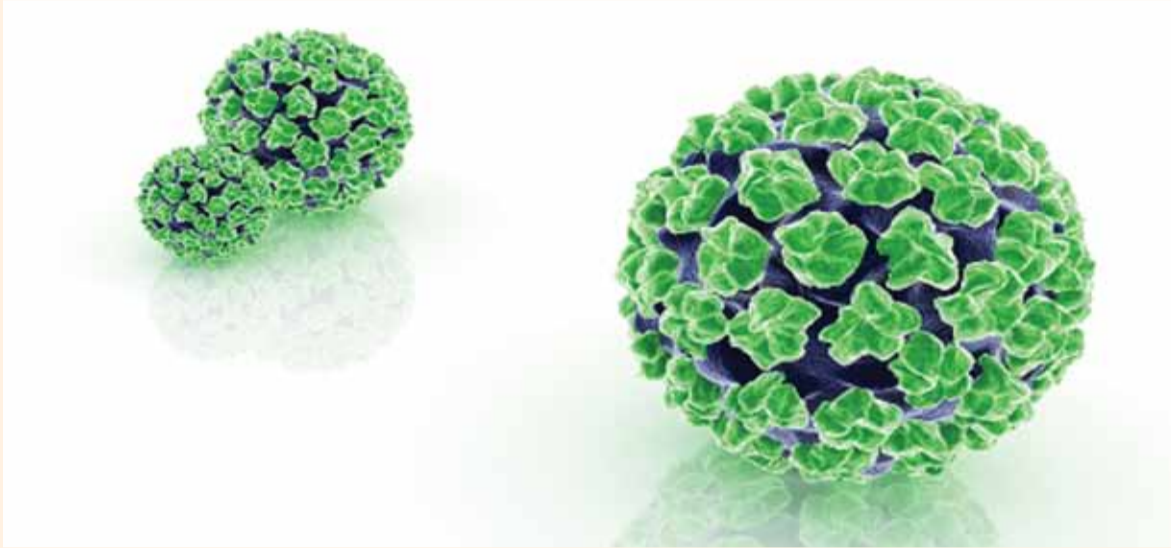
Dentists should always keep an

accurate and contemporaneous record of what is observed during clinical examination and be familiar with the contact details of local oral cancer specialists (typically oral and maxillofacial surgery or oral medicine).

Finally, the patient should be

told the truth, i.e. that the dental professional has concerns that a lesion is possibly malignant or premalignant, and is thus referring the patient for further investigation.¹⁸

Study established poor oral health as risk factor for oral HPV infection



According to the Centers for Disease Control and Prevention, HPV is the most common sexually transmitted virus in the U.S. (Photo: dream designs/Shutterstock)

HOUSTON, USA: Although human papillomavirus (HPV) infection has been increasingly associated with a rising number of cancers of the oropharynx worldwide, no study has examined the role of oral health in oral HPV infection to date. Now, researchers from the U.S. have found that people with poor oral health and those with an oral disease are significantly more likely to contract oral HPV infections.

The study involved 3,439 participants aged 30 to 69 for whom data on oral HPV and oral health were available from the nationally representative 2009–2010 National Health and Nutrition Examination Survey. By analyzing the data, researchers at the University of Texas Health Science Center at Houston found that study participants who reported poor oral health had a 56

percent higher prevalence of oral HPV infection. Those with periodontal disease or related dental problems had a 51 percent and a 28 percent higher prevalence, respectively. In addition, the researchers found a link between the number of teeth lost and oral HPV infection.

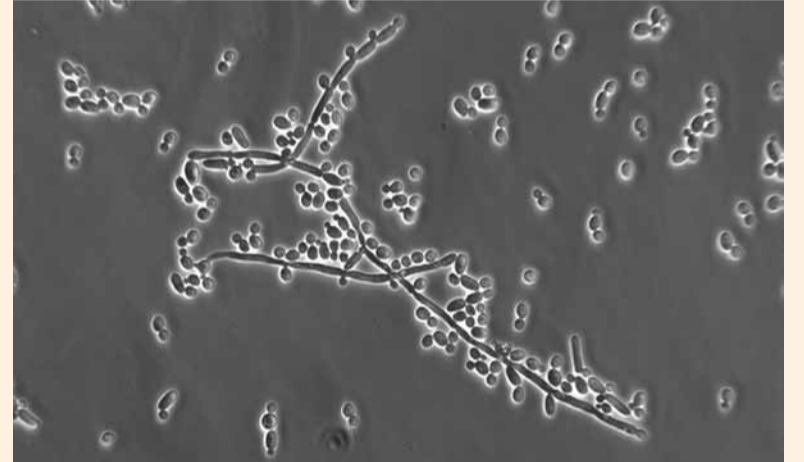
The findings suggest that poor oral health is an independent risk factor of oral HPV infection, irrespective of smoking and oral sex practices, the scientist said. "Public health interventions may aim to promote oral hygiene and oral health as an additional measure to prevent HPV-related oral cancers," they concluded. However, further research is needed to provide a better understanding of this relationship.

According to the researchers, oral HPV infection is the cause of

40 to 80 percent of oropharyngeal cancers. Oropharyngeal cancer was a relatively uncommon cancer, traditionally associated with heavy tobacco smoking and heavy alcohol consumption. However, over the past few decades, its occurrence has increased dramatically in many parts of the world, especially in Europe and North America, and in young adults in particular. Previous studies have already suggested that this increase is due to the growing number of HPV infections.

The study, titled "Examining the Association Between Oral Health and Oral HPV Infection," was published online on Aug. 21 in the Cancer Prevention Research journal ahead of print.^[1]

Researchers identify role of mouth cells in Candida infection



C. albicans is a common fungus living in and on many parts of the human body. It can colonise and infect individuals with compromised immune systems. (Photo: Andre Nantel/Shutterstock)

LONDON, UK: Candida albicans is a species of yeast that causes a number of infections in the human body. In addition to causing oral thrush and sore mouth, these micro-organisms can lead to serious illness or death. New research that provides a better understanding of how mucosal surfaces in the mouth respond to C. albicans to prevent tissue damage was presented recently.

The study was conducted by researchers at King's College London. In laboratory tests, they exposed oral epithelial cells, a mucosal layer of cells that line the mouth, providing a barrier against microbes, to *C. albicans* in vitro and looked at particular gene expressions 6 and 24 hours after infection.

The phosphoinositide 3-kinase pathway, a molecular signalling pathway, was activated about 5 minutes after the

specimen had come into contact with *C. albicans*, preventing the fungus from invading. The researchers suggested that the pathway is involved in priming epithelial cells to prevent future damage.

The researchers believe that the pathway may be an attractive target for new therapeutics. By boosting its activity, it may be possible to reduce tissue damage, suggested Dr David Moyes, research associate at the college.

According to the researchers, *Candida* infections are the third-most commonly acquired blood-borne infections, resulting in an estimated 50,000 deaths annually.

Moyes presented the findings at the Society for General Microbiology's Autumn Conference, which finishes today at the University of Sussex.^[1]

Thailand wins bid for 2015 FDI Annual World Dental Congress



FDI president Dr Orlando Monteiro da Silva and Lt. Gen. Phisal Thepsithar, President of the Thailand Dental Association. (Photo: Claudia Duschek, DTI)

BANGKOK, Thailand/ ISTANBUL, Turkey: For the third time in five years, the Annual World Dental Congress of the FDI World Dental Federation will be held in an Asian country. An agreement between the Geneva-based dentists' organisation and the Dental Association of Thailand (DTA) to organise the 2015 edition in Bangkok was signed last week at this year's FDI congress in the Turkish capital of Istanbul, Dental Tribune ONLINE has learned.

It will be the first time that the South-East Asian country will host the prestigious international dental event. According to DTA President-elect Dr Adirek S. Wongsu, who spoke to Dental Tribune on Friday, his organisation has bid to host the congress in Thailand each year since 1999. It will be a unique event that will not only highlight the rapid development of dentistry in Thailand, but also bring all professions in dentistry together,

he said. Preparations have already commenced and more information will be released in the upcoming months.

The congress in Bangkok will follow the 2014 edition, which is being organised by the Indian Dental Association and hosted in New Delhi. The FDI's most recent congresses in Asia were held in Hong Kong and Singapore. The Korean Dental Association won the bid to organise this year's congress in Seoul in South Korea but the event there was cancelled, and hosted instead by the Turkish Dental Association last week in Istanbul.

The DTA is currently organising its own dental event, the Thailand International Dental Congress, to be held in November this year. According to Wongsu, the event attracts around 3,000 dental professionals each year. Thailand has a workforce of 12,000 dentists.^[1]



ADX14 Sydney Dental Exhibition

AUSTRALIA'S PREMIER DENTAL EVENT

21-23 MARCH 2014 — SYDNEY, AUSTRALIA

- Australia's Largest Dental Exhibition ▪
- All Major Brands And Product Categories ▪
- Discounted Airfare And Accommodation ▪
- Extensive Professional Skills Program ▪

www.adx.org.au

ADX14 Sydney — See more, buy more and learn more

Australia's premier event for all with an interest in dentistry is **ADX14 Sydney**. Over three days, it affords all dentists and allied oral healthcare professionals the opportunity to visit a world-class dental exhibition, and also take part in a dental skills program full of practical solutions and vital insights into the latest innovative products and patient care options.

ADX14 Sydney Key Features —

- World-class exhibition featuring suppliers of quality dental products.
- Anticipated attendance of around 7,500 professionals from the dental community.
- Representatives from government, universities and other stakeholders within the Australian healthcare sector.

International visitors have access to tailored support services to help you apply for a visa and finalise your travel arrangements. Visit the **ADX14 Sydney** website to check out exclusive discounts on airfares and accommodation.

Use your attendance at **ADX14 Sydney** as a chance to visit the Sydney Opera House, climb the Harbour Bridge and visit the world-famous Bondi Beach. Why not take a quick tour to visit a national park to see kangaroos, koalas - all less than two hours away.

The **ADX14 Sydney** dental exhibition is organised by the Australian Dental Industry Association (ADIA), the nation's peak body for suppliers of quality dental products.

ADX14 Sydney — See more, buy more, learn more.

www.adx.org.au



Request for further information —
Simply complete this form to learn more about the exciting opportunities at the **ADX14 Sydney** dental exhibition.

Contact person —

Business —

Postal address —

Telephone —

Email —

Send me information about —

- [...] **ADX14 Sydney visitor**
[...] **ADX14 Sydney exhibitor**

H0813

Please return this form to —

Australian Dental Industry Association
GPO Box 960, Sydney, NSW, 2001 Australia
f: +61 9319 5381
e: sydney@adx.org.au

Welcome to the “Block Party”

Author_Dr Curtis Jansen, USA

Restorative clinicians have been spoiled in the past regarding materials for direct and indirect restorations. We’ve had the great luxury of seeing an ad in a journal, getting an offer in the mail or online, or attending a CE course about a new product, technique or service, and then immediately or the next day, we could take action. If we saw a new restorative material for fabricating restorations, we would simply write the request on a lab slip for the new material and expect to get it back in a couple weeks.

Think of the poor laboratory technician on the other end, reading perhaps for the first time, the method you want used to fabricate your restoration or a specific new material or a mix of materials and techniques. Remember, a laboratory slip or prescription is a work authorization, and if you write one, the laboratory technician has to comply. If we change our minds for the next restoration, we simply prescribe something else. I’m sure technicians sometimes feel as if they’re chasing their tails with all the new materials, techniques and requests. Consider the investment in materials, systems, training and the learning curve they have to endure every time a new material is prescribed.

To the relief of patients, dentists, team members and technicians comes CAD/CAM dentistry and a little bit of sense and sensibility regarding dental materials. Dental material manufacturers need to invest in the technology, methodology and product design, as well as the material evolution to the restoration (blocks, mandrels, discs), in order to introduce a new material for CAD/CAM dentistry. Then, in collaboration, dental CAD (computer-aided design) and dental CAM (computer-aided manufacturing) developers must work with that material to produce consistent optimized results. This takes time and effort. Only those materials proven through economic evaluation, clinical validity and

proven demand will make it to the final stages and into the software of the CAD systems and into the mills of the CAM systems and ultimately into our patients mouths.

CAD/CAM also requires the dentist to take more control of all facets of patient care; it requires more thought than a whim and a handwritten prescription to choose the

right material. CAD/CAM requires thinking through the restorative and aesthetic process before proceeding with a restoration, all better things for the dental professional as a whole. As more and more laboratories and dentists invest in digital dentistry, everyone gains.

I’m “all in” for “daily digital dentistry.” I have digital impression-

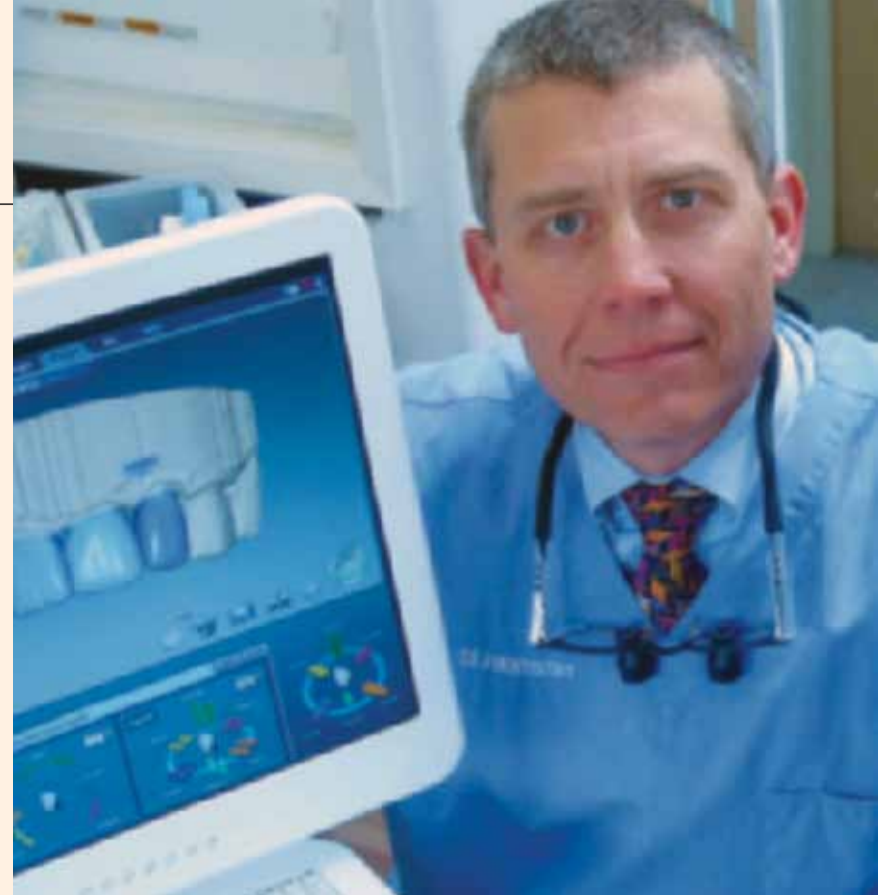
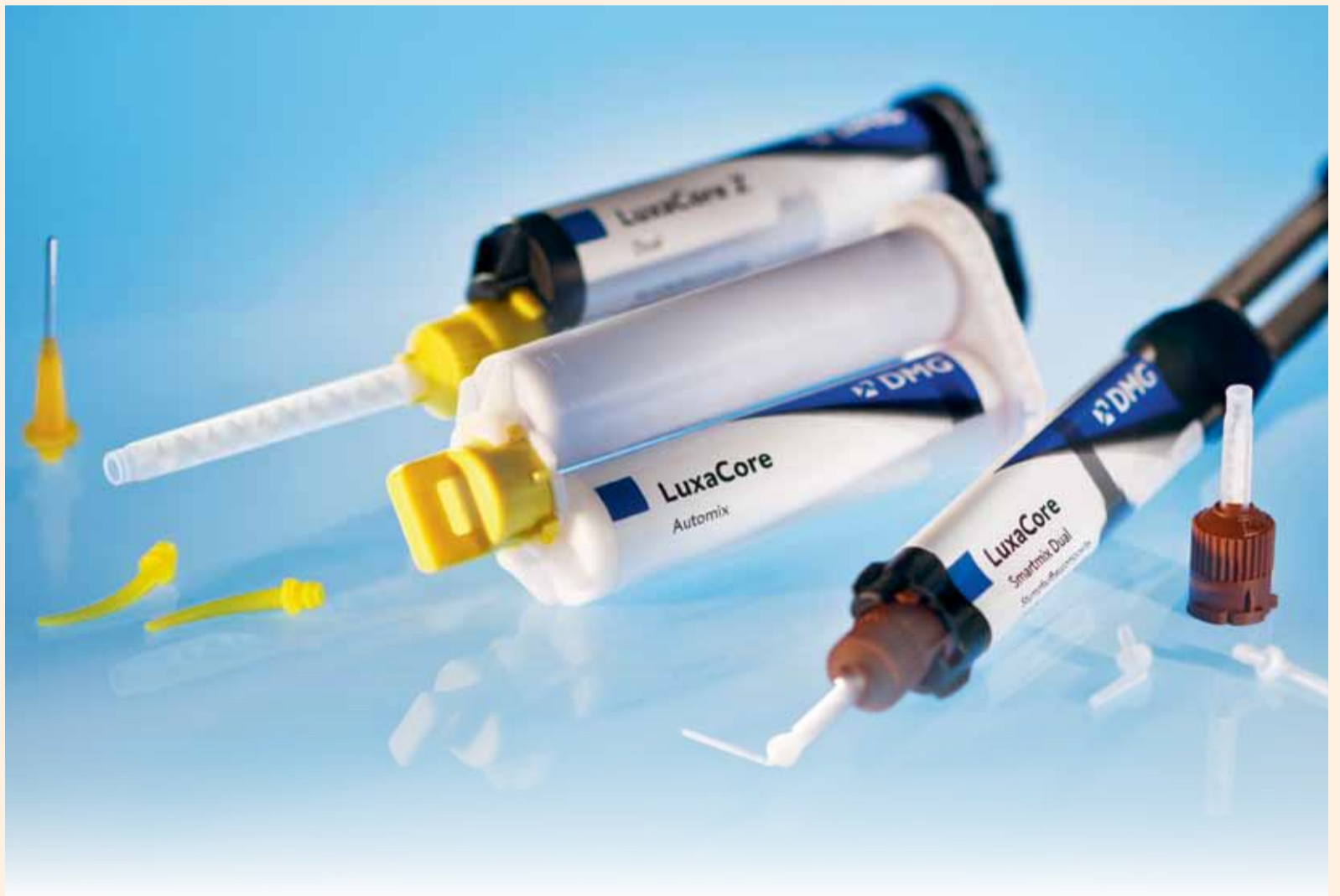
Figure 1: Chairside CAD/CAM System. (Photos/Provided by Dr Curtis Jansen)



Yet even closer to nature – LuxaCore Z.

No other core build-up material comes closer to the natural properties of dentine than the new LuxaCore Z-Dual: This premium composite for core build-ups and post cementations cuts like dentine. LuxaCore Z-Dual is the first material of its category that combines true

DMG-patented nano technology and zirconium dioxide. With LuxaPost, the new glass fiber reinforced and pre-silanized composite post, DMG offers the perfect partner for LuxaCore Z-Dual. www.dmg-dental.com

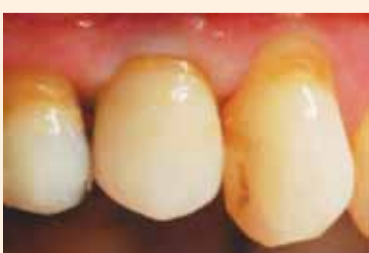
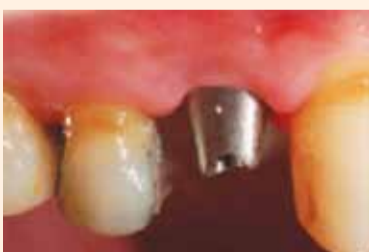
Figure 2&3: Lava Ultimate is ideal for implant superstructures.



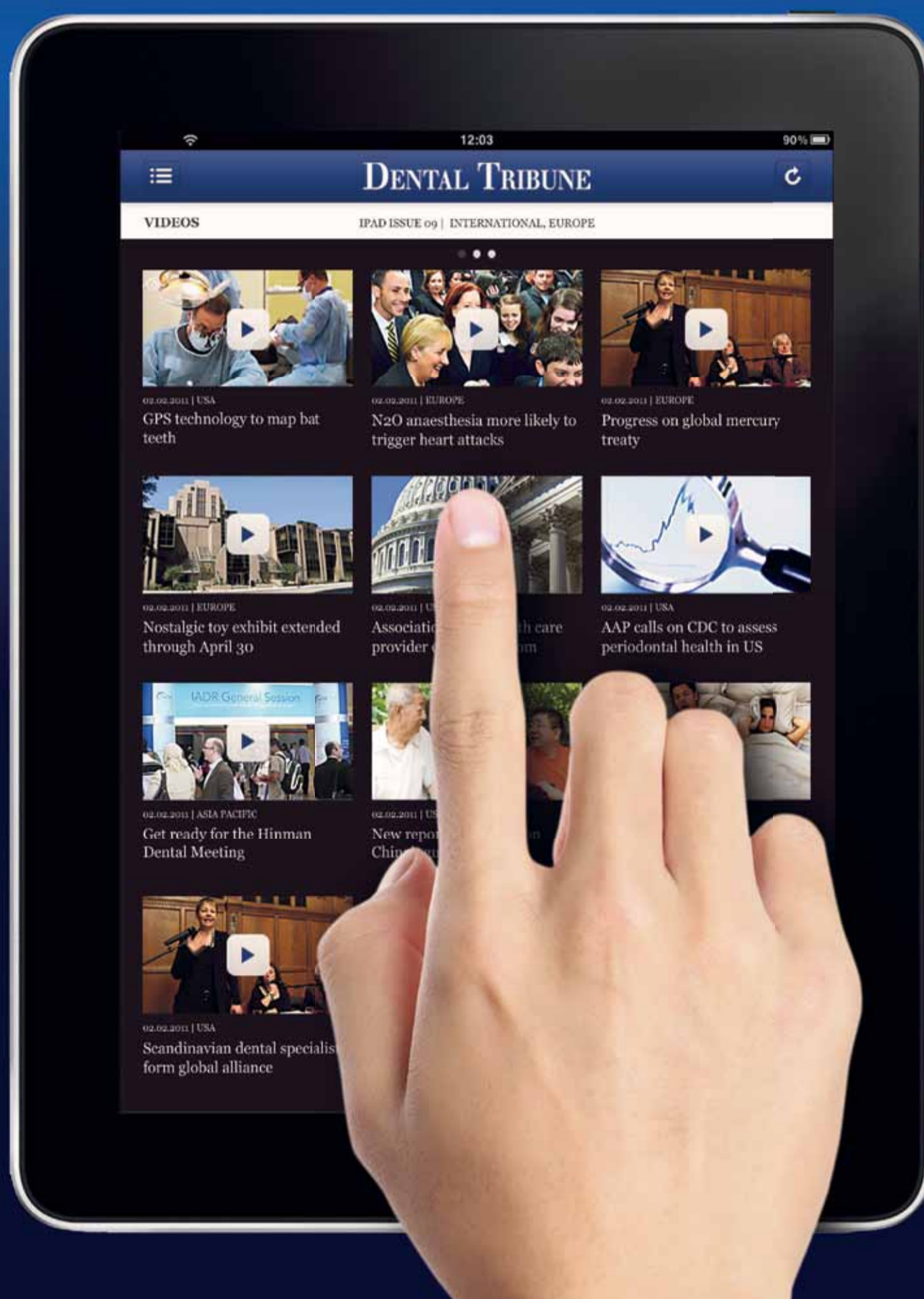
* Source: GfK and SDM market data 2010 for LuxaCore

DMG
Dental Milestones Guaranteed

Dental Tribune for iPad – Your weekly news selection

Our editors select the best articles and videos from around the world for you every week. Create your personal edition in your preferred language.

ipad.dental-tribune.com



DENTAL TRIBUNE

— The World's Dental Newspaper —