



DENTAL TRIBUNE

—The World's Dental Newspaper • Middle East & Africa Edition—

Printed in Dubai

www.dental-tribune.me

November-December 2015 | No. 6, Vol. 5

ENDO TRIBUNE

Supernumerary teeth:
Diagnosis and treatment



>Insertion

LAB TRIBUNE

IPS e.max Smile
Award 2016: In search
of the world's most
esthetic dental cases



>Insertion

HYGIENE TRIBUNE

New Philips Sonicare
AirFloss Ultra improves
periodontal health in
just four weeks



>Insertion

DENTSPLY–Sirona merger to create world's largest dental manufacturer

By Dental Tribune International

SALZBURG, Austria/YORK, Penn., USA: DENTSPLY International and Sirona Dental Systems announced that the companies have entered into a definitive merger agreement. It is expected that the new company will be the world's leading manufacturer of professional dental products and technologies, having the largest sales and service in-

frastructure in the global dental industry with about 15,000 employees across the world.

The newly founded company will operate under the name of DENTSPLY SIRO-NA. Both companies will retain their respective headquarters. The current

> Page 2



DENTSPLY-Sirona merger

The 25th BIDM 2015 Another success for Lebanese Dental Association

By Dental Tribune MEA/CAPPmea

BEIRUT, Lebanon: In his welcoming speech, President Elie Maalouf opened with "Our Target is to have a BIDM that attracts the major dental business in the area". Several new projects were also launched in order to im-

prove dentistry in Lebanon by the LDA during the BIDM meeting.

The conference proved to be a vital platform for the participants to share their ideas, explore potential new advances in technology and foster closer ties. "The theme of 'Redefining the standards of Care' is more relevant than ever as we face conflicting ideas in our daily practice and there is a real urge to be able to respond to this with evidence-based knowledge" said Dr. Nabih Nader, LDA President of the Scientific Committee.

Despite the difficult situation in the region, the event attracted over 2,072 Lebanese and International registered dentists, 38 highly esteemed guest speakers from 18 countries around the world (Brazil, USA, France, Germany,

> Page 44

INDUSTRY	4-7
MEDIA mCME	8-14
ORAL HEALTH	16-18
AESTHETICS	19
PAEDIATRIC TRIBUNE	20-24
CAD/CAM	25-30
ORTHO TRIBUNE	31-33
IMPLANT TRIBUNE	35-39
NEWS	40-46
PRACTICE MNG	48-50

CAREERS

Career Opportunities
Job openings
Dental Categories

www.dental-tribune.com/careers

S
SOUTHERNIMPLANTS

MAX
Implants

Co-Axis
Implants

May Eliminate The Need For Grafting
Shortens Treatment Time

Appropriate Emergence

Stable Enough For Immediate Restoration

5 Different Connections



P.O. BOX 505190, DUBAI, U.A.E.
Tel: +971 (0)56 131 1574
Fax: +971 (0)4 427 5011

info@southernimplants.net | www.southernimplants.com

< Page 1: "DENTSPLY-Sirona merger to create world's largest dental manufacturer"

DENTSPLY head office in York will serve as the new company's global headquarters, while the international headquarters will be located in Salzburg.

Upon close of the transaction, Jeffrey T. Slovin, current president and CEO of Sirona, will serve as CEO of DENTSPLY SIRONA and will be a member of the board of directors. Bret W. Wise, current chairman and

CEO of DENTSPLY, will assume the position of executive chairman of the newly founded company. In their respective positions, they will collaborate in executing the corporate strategy and in integrating the companies and their respective corporate cultures.

Together, the companies expect to generate a net revenue of about \$3.8 billion (€3.4 billion)

and adjusted EBITDA of more than \$900 million (€796 million), excluding the incremental benefit of synergies.

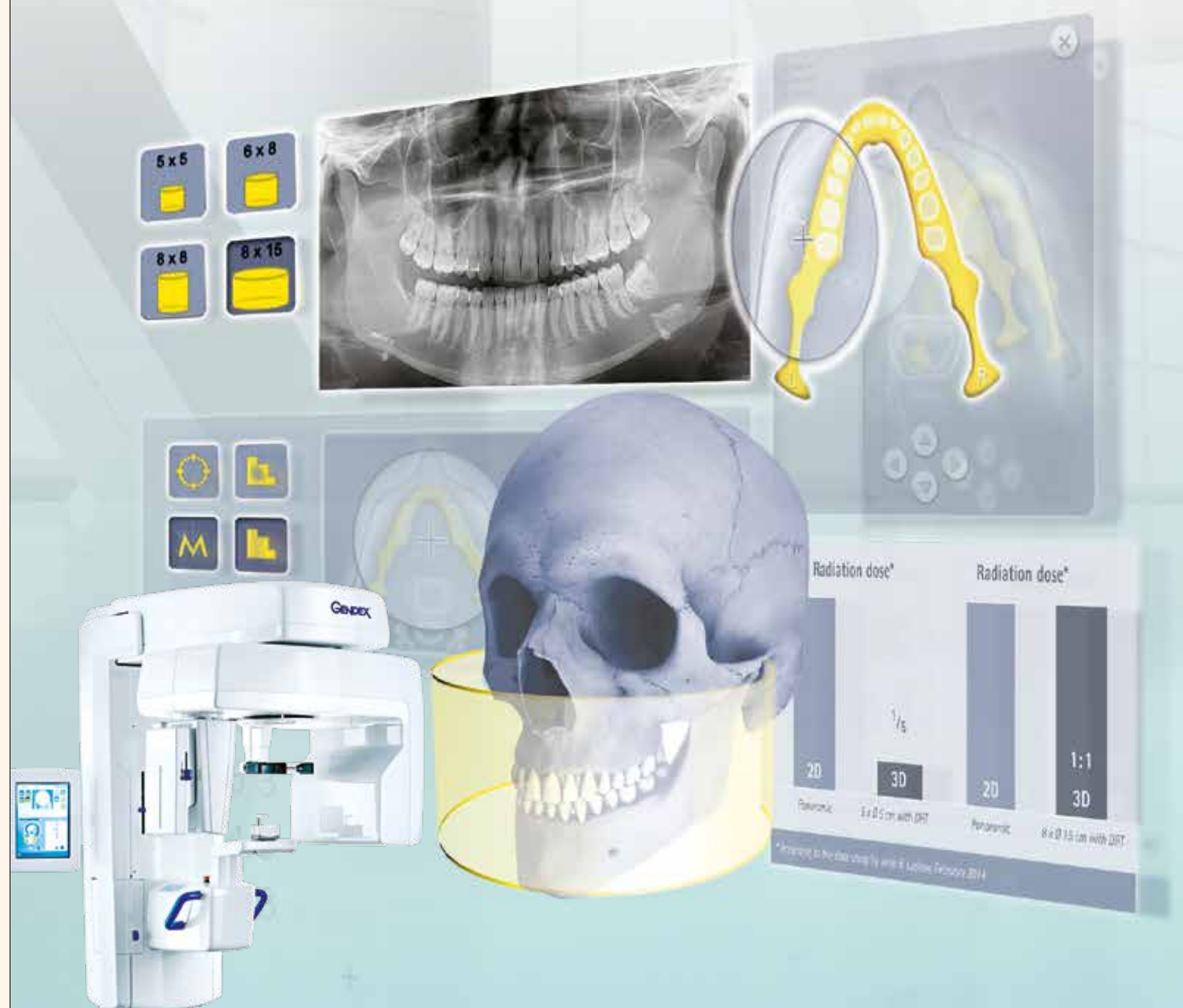In addition to thousands of employees in more than 120 countries, DENTSPLY SIRONA will have over 600 scientists, and research and development staff working to accelerate the development of new dental technologies, especially in the rapidly

growing areas of digital dentistry and integrated solutions.

The merger is expected to be completed in the first quarter of 2016. However, the transaction is still subject to the receipt of certain regulatory approvals and other customary closing conditions and approvals. ^{DT}

The Intelligent Solution

Exceptional performance, at an everyday price



Adapts to every patient – just like you!

A cost-efficient and easy-to-use system made to adapt to your requirements. High image quality in 2D and 3D, with 4 FOV and 4 individual resolution options, including Dose Reduction Technology.

It's the Gendex way of doing things!

GX DP-800™

- Cone Beam 3D Imaging Systems
- Panoramic X-ray Systems

Find your solution, visit:
www.kavo.com/gxdp-800

GENDEX
Always by your side

DENTAL TRIBUNE

The World's Dental Newspaper - Middle East & Africa Edition

GROUP EDITOR

Daniel Zimmermann
newsroom@dental-tribune.com
Tel.: +49 541 48 474 107

CLINICAL EDITOR
Magda Wojtkiewicz

ONLINE EDITOR
SOCIAL MEDIA MANAGER
Claudia Duschek

EDITORIAL ASSISTANTS
Anne Faulmann
Kristin Hübner

COPY EDITORS
Sabrina Raaff
Hans Motschmann

PUBLISHER/PRESIDENT/CEO
Torsten Oemus

CHIEF FINANCIAL OFFICER
Dan Wunderlich

CHIEF TECHNOLOGY OFFICER
Serban Veres

BUSINESS DEVELOPMENT MANAGER
Claudia Salwiczek

JUNIOR MANAGER BUSINESS DEVELOPMENT
Sarah Schubert

PROJECT MANAGER ONLINE
Tom Carvalho

EDUCATION MANAGER
Christiane Ferret

EVENT MANAGER
Lars Hoffmann

MARKETING & SALES SERVICES
Nicole Andra

EVENT SERVICES
Esther Wodarski

ACCOUNTING SERVICES
Karen Hamatschek
Anja Maywald
Manuela Hunger

MEDIA SALES MANAGERS
Matthias Diessner (Key Accounts)
Melissa Brown (International)
Antje Kahnt (International)
Peter Witteczek (Asia Pacific)
Weridiana Magowski (Latin America)
Maria Kaiser (USA)
Hélène Carpentier (Europe)
Barbora Solarova (Eastern Europe)

EXECUTIVE PRODUCER
Gernot Meyer

ADVERTISING DISPOSITION
Marius Mezger

DENTAL TRIBUNE INTERNATIONAL
Holbeinstr. 29, 04229 Leipzig, Germany
Tel.: +49 541 48 474 502
Fax: +49 541 48 474 175
www.dental-tribune.com
info@dental-tribune.com

DENTAL TRIBUNE ASIA PACIFIC LTD.
Room A, 20/F
Harvard Commercial Building
105-111 Thomson Road, Wanchai, HK
Tel.: +852 5113 6177
Fax: +852 5113 6199

THE AMERICA, LLC
116 West 25th Street, Ste. 500, New York
N.Y. 10011, USA
Tel.: +1 212 244 7181
Fax: +1 212 244 7185

DENTAL TRIBUNE MEA EDITION EDITORIAL BOARD
Dr. Aisha Sultan Alsuwaidi, UAE
Dr. Ninette Banday, UAE
Dr. Nabeel Humood Alsabeeha, UAE
Dr. Mohammad Al-Obaidi, KSA
Dr. Meshari F. Alotaibi, KSA
Dr. Jasim M. Al-Saeedi, Oman
Dr. Mohammed Sultan Al-Darwish
Prof. Khaled Balto, KSA
Dr. Dobrina Mollova, UAE
Dr. Munir Silvadi, UAE
Dr. Khaled Abouseada, KSA
Dr. Rabih Abi Nader, UAE
Dr. George Sanoop, UAE
Aiham Farrah, CDT, UAE
Retty M. Matthew, UAE
Olivier Carcuac, UAE
Rodny Abdallah, CDT, Lebanon

PARTNERS
Emirates Dental Society
Saudi Dental Society
Lebanese Dental Association
Qatar Dental Society
Oman Dental Society

DIRECTOR OF mCME
Dr. Dobrina Mollova
mollova@dental-tribune.me
Tel.: +971 50 42 43072

DIRECTOR
Tzvetan Deyanov
deyanov@dental-tribune.me
Tel.: +971 55 11 28 581

DESIGNER
Kinga Romik
k.romik@dental-tribune.me

SMALL CHANGE. BIG DIFFERENCE.

The new imaging plate scanner XIOS Scan completes the intraoral family from Sirona. Whether you're taking the first steps into the digital world or establishing or updating a fully digital practice, XIOS Scan and XIOS XG Sensors offer perfectly synchronized solutions for every workflow. **Enjoy every day. With Sirona.**



THE NEW
IMAGING PLATE
SCANNER:
XIOS Scan

SIRONA.COM

The Dental Company

sirona.

Ketac™ Universal Glass Ionomer Restorative Clinical Case

By Dr. Gunnar Reich, Germany

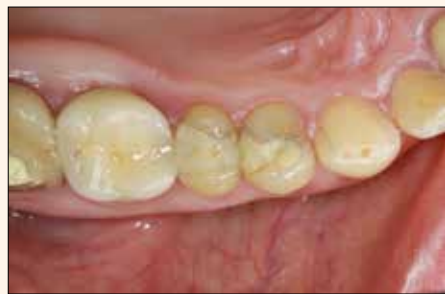

Fig. 1: Initial situation: upper first premolar with insufficient disto-occlusal restoration

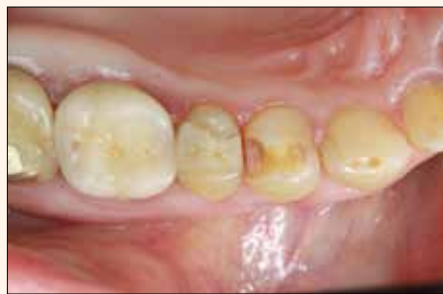

Fig. 2: Cavity preparation after removal of the defective restoration

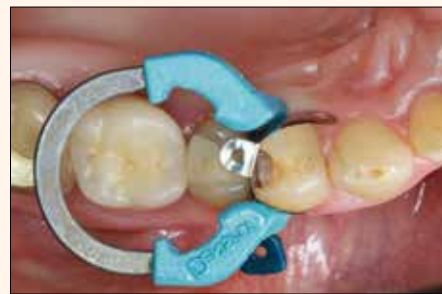

Fig. 3: Placement of sectional matrix system

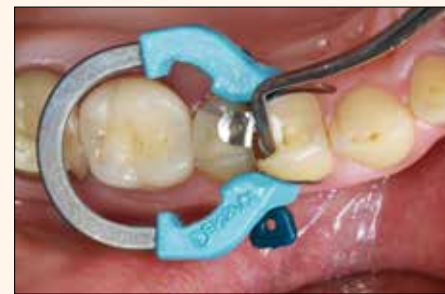

Fig. 4: Bulk placement of Ketac™ Universal Glass Ionomer Restorative into cavity

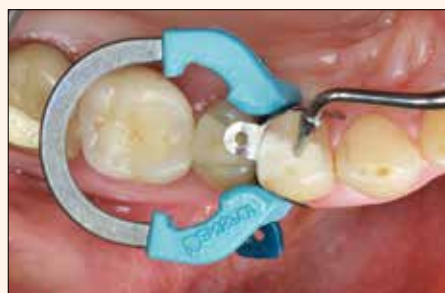

Fig. 5: Shaping of occlusal surface with the instrument

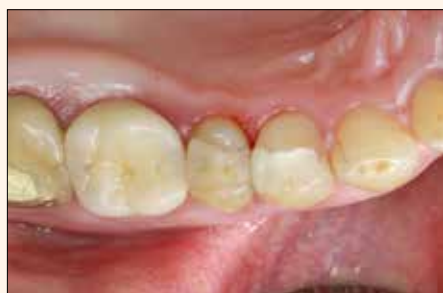

Fig. 6: Final Ketac™ Universal restoration after polishing with Sof-Lex™ Spiral Polishing Wheels

About the Author



Dr. Gunnar Reich, Munich, Germany
Owner of Dr. Gunnar Reich Private Dental Practice specialized in the following focus areas: aesthetic restoration and reconstruction with plastic, filling material in anterior and posterior regions, complex dental prostheses and implantology.

Author of several publications in Germany and abroad.

Ketac™ Universal Restorative. Dentist satisfaction ratings

By 3M

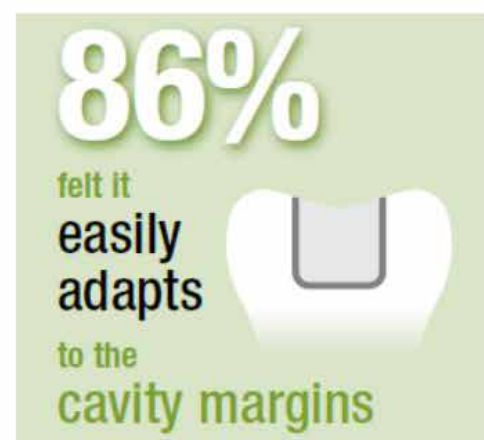
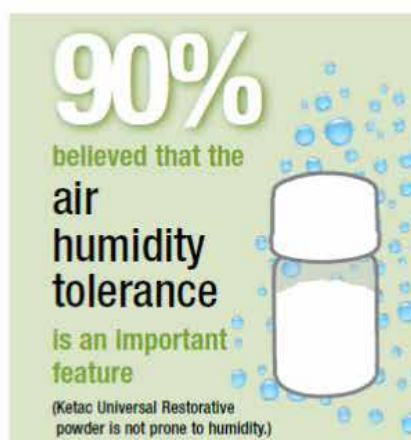Ketac Universal restorative is designed to save steps and time... therefore the handling must also support a

fast, easy procedure. In an application test 3,510 fillings were placed using Ketac™ Universal Glass Ionomer restorative. Dentists

were pleased with overall handling, ease of placement and cavity adaptation¹.

References

1. Please refer to the Technical Data Sheet.



3M Announces New 3M Oral Care Organization

By 3M

Consistent with 3M's strategy to increase customer relevance, the company has announced the formation of 3M Oral Care, combining the former 3M ESPE Dental and 3M Unitek Orthodontics into a single new division, led by Vice President & General Manager James D. Ingebrand.

"Building on our strong brands and technologies, 3M Oral Care will leverage our fundamental strengths in science and innovation to deliver a complete suite of solutions across the continuum

of oral care for dentists and orthodontists, to improve patient outcomes," said Joaquin Delgado, Executive Vice President, 3M Health Care Business Group.

"We are committed to further building on our more than half a century of innovation in the oral health industry," Ingebrand said. "This will accelerate our momentum as we continue to deliver quality innovative solutions for doctors and their patients."

3M was recognized recently as the "Most Innovative Dental Company" for the 10th consecutive year, by The Anaheim Group

(publisher of Dental Fax Weekly), for continuing to bring exciting new ideas to dentistry. 3M's wide range of dental products and supplies includes restorative, crown and bridge, mini-dental implants, preventive, infection control and others. In addition, 3M helps integrate advanced digital technology and materials science through CAD/CAM dentistry and digital impressions. 3M has brought a number of amazing firsts to the dental industry, including the first-ever tooth-colored restorative material, the first self-adhesive universal resin cement, the first nano ionomer, the first malleable, preformed

temporary crown and the first automated mixing of impression materials.

3M also is known as a leader in orthodontic solutions. Recent innovations include: Clarity™ Advanced Ceramic Brackets which combine brilliant aesthetics with consistent strength and small bracket design for enhanced patient comfort; APC™ Flash-Free Adhesive which allow doctors to move directly from bracket placement to bracket cure without removing adhesive flash – no clean up; and Victory Series™ Superior Fit Buccal Tubes to hold arch wires to molars, designed

with a large compound contour base for superior fit, exclusive "contoured funnel" for easy wire insertion and low profile and flush-mount hook for patient comfort; and "invisible" 3M™ Incognito™ hidden braces, which are placed on the lingual side of the teeth for highly aesthetic treatment.^{DT}

Contact Information

For more information please visit www.3MGulf.com/espe



Finish faster. Finish strong.

Now, get them out of the chair faster!

Pediatric. Geriatric. And busy teens in between. Treating patients who can't sit still long feels like a race against the clock—and every second counts. That's why 3M ESPE Dental developed Ketac™ Universal Aplicap™ Glass Ionomer Restorative.

- **One-step placement**—no conditioning, coating or light-curing steps to slow the procedure down
- **Stress-bearing properties** enable extended indications
- **Continous fluoride release** over 12 months

Ketac Universal restorative ... because the most caries-prone patients are also the most restless.

For more information please visit:

www.3MGulf.com/espe



**Ketac™
Universal
Aplicap™**

Glass Ionomer Restorative

3M



AEEDC 2016
German Pavillion

PROMEDICA

Highest quality made in Germany



Self-curing Calcium Hydroxide Paste

- For indirect pulp capping and linings under dental filling materials
- Sufficient working time in combination with a short setting time in the mouth
- Bacteriostatic
- Antimicrobial effect due to a high pH-value
- Contains 26% calcium hydroxide
- Preservation of vitality due to pulp recovering

Glass Ionomer Filling Cement

- Excellent biocompatibility due to low acidity
- High compressive strength
- Stable and abrasion resistant
- Tooth-like thermal expansion
- No temperature rise during setting
- Enamel-like translucency and excellent radiopacity



Visit www.promedica.de to learn more about all our products!

PROMEDICA

Dental Material GmbH
24537 Neumünster / Germany
Tel. +49 43 21 / 5 41 73
Fax +49 43 21 / 5 19 08
eMail info@promedica.de
Internet www.promedica.de

Individual design for your treatment unit and your furniture

By Ritter

The glass elements of the treatment unit ARIA SR and the furniture line Cameo can be designed according to your personal preference. Perfectly harmonized, the two elements fit perfectly in your clinic branding. Choose your own motives, personal images or your practice logo in order to create an amazing brand recognition!

The new treatment unit ARIA SR combines efficiency and user-friendly handling with pure

aesthetics and individuality. It improves the productivity in the dental office with simple and practical solutions. The careful selection of high-quality materials, a very attractive design and outstanding functionality guarantee fantastic results. The surface parts of the ARIA-SR are made of pure metal and polyester with high-quality gel coating. No usual plastic parts are used. This guarantees an extraordinary stability and the long-term consistent appearance, free from yellowing. For the purpose of preventive care treatment and prophylaxis, the operating



ARIA SR is perfectly complemented by modern furniture line Cameo

lamp of ARIA SR can be particularly equipped with a bleaching adapter and a cosmetic mirror.

ARIA SR is perfectly complemented by modern furniture line Cameo. With its modular

components, best materials and an outstanding design this young furniture line meets all expectations in terms of hygiene, reliability, comfort and aesthetics. The matching wall cupboards for disposable materials complete the furniture line optional. ^{DT}

Contact Information

RitterConcept GmbH
Bahnhofstraße 65,
08297 Zwoenitz
Tel. 0049 (0) 37754/13-514
info@ritterconcept.com
www.ritterconcept.com









ADVANCED PRESS™ Process

The patented ADVANCED PRESS™ process ensures a uniform temperature distribution from the temperature sensor of the press furnace to the inside of the press ring.

Pressing always takes place within the ideal temperature range for pressing lithium disilicate. Thus hardly any reaction layer is created on the surface. This is enhanced by an extremely short press time.

The result is a smooth surface and an enormous time savings!

Available only in the VARIO PRESS 300e Version

Exclusively by:



دبي للمعدات الطبية ذ.م.م.
Dubai Medical Equipment L.L.C.
P.O.Box: 24476, Sharjah - United Arab Emirates, Tel. : +9716 5308055, Fax : +971 6 5308077
E-mail : dt_uae@eim.ae, www.dme-medical.com

Design prize ju SIDEXIS 4 as “

By Dental Tribune International

BENSHEIM, Germany/ SALZBURG, Austria: Dental manufacturer Sirona has recently been awarded the Red Dot Award in Communication Design as “Best of the Best” for its new SIDEXIS 4 imaging software. Each year, the international design award gives recognition to products of the highest level of design quality. Overall, almost 7,500 projects from 53 countries were submitted. The award will be presented at the Red Dot Gala in Berlin on 6 November 2015 in the presence of approximately 1,000 guests.

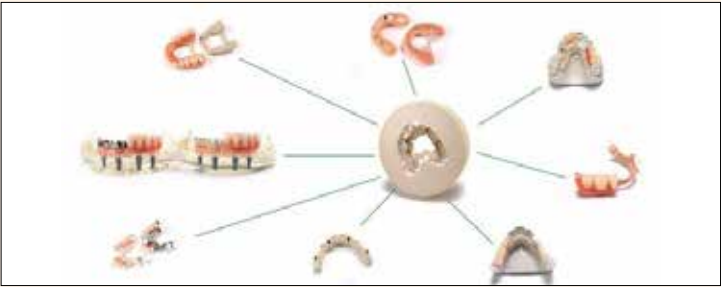
Together with software specialist Heinrich & Reuter Solutions, Sirona has been recognised for its extensive efforts in designing the intuitive, user-friendly interface of SIDEXIS 4. Dentists can use the software to access all per-



Qualident Dental Laboratory Introduces JUVORA – The Next Generation Dental Material

By Qualident

JUVORA™, the first approved high performance polymer material that allows the CAD/CAM fabrication of a removable denture framework from a non-metal material – provides a more efficient process for dental professionals and an improved patient experience. Intended for use in telescope attachments, precision attachments and implant supported superstructures, the JUVORA™ Dental Material uses only the purest biomaterial sourced from the market leading provider of PEEK-OPTIMA biomaterials, Invibio® Biomaterial Solutions (that has more than a decade of experience and proven success in over 4 million implanted devices globally.)



JUVORA™ material offers significant benefits for patients as both the design and material properties, enabling the manufacture of precise, lightweight and comfortable non-metal removable dentures

Patient benefits

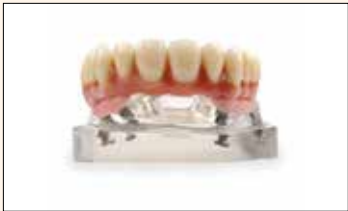Prosthetic frameworks made from JUVORA™ provide patients with premium solutions:

- Strong and lightweight to improve patient comfort
- Digitally designed to match patient's anatomy
- Elastic modulus similar to bone – allowing for increased flexibility in both denture design and patient use.
- Shock absorbent during chewing
- High strength to weight ratio
- Resistance to wear, abrasion and corrosion – less damage to adjacent natural teeth
- Metal-free denture framework
- Taste-neutral (no metal taste)
- Reduced thermal or electrical conductivity when compared to metal

- X-ray and scanner friendly (X-ray Transparent)

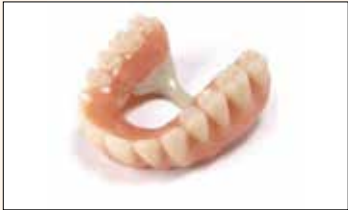Indications

1) Implant-supported superstructures
Our high-performance, biocompatible JUVORA allows a strong, yet lightweight, framework for cantilever designs (e.g. all-in-four) and is clinically proven for implant applications.

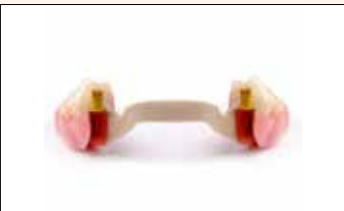

2) Telescope attachments:
Telescope attachments manufactured from a JUVORA™ provide improved friction, accuracy and better retention of zirconia primary crowns and offer less intrusive telescope transversal

connectors. The CAD/CAM digital design process results in a precise denture framework that is more comfortable and better fitting than alternative materials.



3) Precision attachments
Denture attachments made from a JUVORA™ are more comfortable and better fitting than those made from other materials. The JUVORA™ is made from a revolutionary PEEK-OPTIMA® denture base material that is clinically proven for implant applications and noted to improve the retention of the dental structure.



At Qualident Dental Laboratory, we are vigilant about ensuring the quality of our product.

Contact Information

Dr. Noor Al-Aswad
Mob: 056 7945588
Dubai, U.A.E,
Century Plaza 101,
Jumeirah 1 Beach Road.
Tel: +971 4 3427576

Sharjah, U.A.E,
Al Ettihad Road
Opposite Safeer Mall,
Wasl Bldg, 101,
Tel: 06-5255199
www.qualident-online.com

Qualident recognises "Best of the Best"

...tinent patient image data. The software can handle all common image formats and types, including digital SLR, intra-oral, panoramic and 3-D images. Thus, data from previous and current imaging technologies can be accessed and easily displayed and managed. SIDEXIS 4 acts as a central hub for the integration of diagnostic image data of any kind that the practice team has not only prepared during the course of the treatment, but also received from other dentists for long-term patients. The dentist can display a full overview of the patient's treatment history in a timeline. Using a digital light-box, the dentist can easily make cross-comparisons between the image data and recognise subtle changes in the course of treatment.

The numerous interfaces make it possible to connect to all digi-

tal systems in the dental practice. The imaging software can also be extended with plug-ins and applications to enable perfect coordination with integrated digital processes for simultaneous surgical and prosthetic planning of implants, and for orthodontic applications.

According to Sirona, SIDEXIS 4 has also been well received by the expert community. "We have received feedback from many users that the entire workflow in the practice has improved with the software upgrade and that diagnosis, planning and treatment are simpler, faster and safer," remarked Dr Nadia Amor, Senior Product Manager of Imaging Software at Sirona.

Sirona has already won two Red Dot Awards this year for its innovative ORTHOPHOS SL radiographic solution and inLab MC X5 dental device. [DR](#)

**ARCHITECT
of the SMILE**

www.qualident-online.com

Dubai - 04 3427576
Sharjah - 06 5255199

How to avoid extractions when treating malocclusions using MRC's Bent Wire System and Trainer System for arch development



mCME articles in Dental Tribune have been approved by:

HAAD as having educational content for 2 CME Credit Hours

DHA awarded this program for 2 CPD Credit Points

ADA C.E.R.P.® Continuing Education Recognition Program

Centre for Advanced Professional Practices (CAPP) is an ADA CERP Recognized Provider. ADA CERP is a service of the American Dental Association to assist dental professionals in identifying quality providers of continuing dental education. ADA CERP does not approve or endorse individual courses or instructors, nor does it imply acceptance of credit hours by boards of dentistry.

CAPPmea designates this activity for 2 continuing education credits.

By German O. Ramirez-Yañez, DDS, PhD, and Chris Farrell, BDS

Abstract
Maxillary and mandibular expansion has been proposed to increase the arch perimeter and to avoid extractions during orthodontic treatment. Although controversy has persisted over the stability of expansion techniques, there is an increasing trend toward "non-extraction."

This paper describes a novel method to produce expansion of the dental arches, and at the same time, to treat muscular dysfunctions that may be the etiological factor of the maloc-

clusion. The system has been developed by Myofunctional Research Co. (MRC), Queensland, Australia, as a simpler method of phase one expansion, which may produce improved stability because of simultaneous habit correction in selected cases. Two cases treated with the Farrell Bent Wire System™ (BWS™) are described and the advantage of this method of treatment is discussed.

Introduction

Expansion of the jaws has been increasingly performed in orthodontics to achieve better occlusal and maxillary relationship and, in doing so, improving oral functions. Maxillary and

mandibular expansion has been proposed since Edward Angle to avoid extractions (Dewel, 1964). This paper presents a novel method to produce dental arch development in the maxilla and the mandible, while at the same time correcting or maintaining the inter-maxillary relationship either if a sagittal and/or vertical problem exists or a Class I malocclusion with normal overjet and overbite is present at the beginning of treatment.

There is a controversy regarding the ideal time for performing the expansion. Sari and co-workers reported that rapid maxillary expansion by means of a fixed screw (eg. Hyrax) produces better results when it is performed in the early permanent dentition (Sari, 2005). Although this statement appears to be supported by other studies (Chung; Housley, 2005; Spillane, 1995), maxillary expansion may also be successfully done in older adolescents and adults (Stuart, 2003; Iseri, 2004; Lima, 2000). In the maxilla, rapid and semi-rapid expansion produce an increase of the lower nasal and maxillary base widths, with the maxilla moving forward and downward (Chung, 2004; Sari, 2005; Iseri, 2004).

These changes in the maxilla produced by the expansion are accompanied by a spontaneous mandibular response, which increases the dental arch perimeter (Lima, 2004; McNamara, 2005) and rotates the mandible posteriorly (Sari, 2005; Chung, 2004). Mandibular displacement is associated with an increase in facial height (Sari, 2005; Chung, 2004).

Net gain in the arch perimeter may be calculated accordingly with the expansion performed. Motoyoshi and co-workers reported that 1 mm increase in arch width results in an increase in arch perimeter of 0.57 mm (Motoyoshi, 2002). Akkaya and collaborators determined that arch perimeter gain through expansion could be predicted as 0.65 times the amount of the posterior expansion when treatment is performed with rapid maxillary expansion, and 0.60 times the amount of posterior expansion when treatment is performed with semi-rapid maxillary expansion (Akkaya, 1998). This is also supported by Adkins and co-workers, who determined that arch perimeter may increase 0.7 times the expansion produced at the premolars.

An expected relapse in the amount of expansion has been reported by some authors (Hime, 1990; Housley, 2005), which appears to be the result of that pressure delivered by the cheeks on the maxillary arch

and the resistance to deformation of maxillary sutures and surrounding tissues to maxillary expansion.

Nevertheless, maxillary and mandibular expansion rises up as one of the important phases of orthodontic treatment, producing arch perimeter increase, and thus, avoiding extraction of teeth. Increasing numbers of multi-banded techniques using passive self-ligating brackets have become popular, but few address the challenges of adapting the soft tissues to this new dental position. Long-term retention is the recommended solution to stability. Thus, the aim of the current paper is to present a new method to produce maxillary and mandibular expansion and, at the same time, to treat the soft-tissue dysfunction that may be responsible for treatment relapse (Ramirez-Yañez, 2005). Two example cases treated with the BWS Orthodontic System developed by Myofunctional Research Co (MRC) in Australia are presented to explain the proposed treatment.

The BWS Orthodontic System

The BWS Orthodontic System discussed in this article is composed of two different appliances: the Trainer™ and the BWS. These two appliances combined may simultaneously produce arch development and treat poor myofunctional habits. The Trainer, a pre-fabricated functional appliance, has amply demonstrated an ability to relocate the mandible (Usumez, 2004) to correct improper forces produced by the muscles of the cheek and lips (Quatrelli, Ramirez-Yañez, 2005a) and to change the dimensions of the dental arches (Ramirez-Yañez, 2005b). Further research (Yagci 2011) showed that treatment using the Trainer produced a positive influence on the masticatory and peri-oral musculature.

However, in those cases where more maxillary and mandibular expansion is required to avoid teeth extractions, the Trainer combined with the BWS produces higher amounts of expansion and, therefore, a higher increase in arch perimeter. It is also proposed that by utilizing the Trainer in conjunction with the arch expansion, the force of the tongue activates further alveolar changes that other techniques may not achieve because of the bulk of the appliance being located in the palate where the tongue should naturally position.

The BWS is typically composed of a lingual arch, which follows the lingual surfaces of the teeth crowns at the gingival third and ends in a loop at the inter-

proximal space between the second premolar and the first molar at both sides. The distal end engages a tube (0.7 Farrell tube by MRC) welded to a cemented band on the first molars (Fig. 1). Additionally, the BWS is maintained in place, facing the gingival third of teeth's crown, by two begg premolar brackets cemented on the first premolars with the slot directed toward gingival or alternately composite stops bonded to the premolar or anterior dentition (Fig. 2). The wire component is 0.7 mm spring wire and is fabricated to the arch form of the starting models either by the laboratory or the orthodontist. The simple nature of the BWS makes it possible to assemble in-house, avoiding the fees that accompany laboratory-constructed appliances.

An advantage of this system is that it does not involve using acrylic in the palatal vault. A functional appliance designed with acrylic on the palate and that is not properly built may lower the tongue, encouraging tongue thrusting, and, thus, either worsening the malocclusion or producing a relapse (Fig. 5). The Trainer is a pre-fabricated functional appliance, which means no laboratory involvement, and the BWS can be entirely constructed "in office." The BWS is not made of acrylic, nor does it occupy the palate. It allows the tongue to position correctly and the patient to speak normally.

The BWS is also suitable for use in the lower arch. Typical treatment tends to use only upper expansion for three to four months, after which time the wire component of the BWS is removed (the bands are kept for later use of the BWS). The i-2 Trainer (with the inner-cage that produces arch expansion) is then used to maintain the initial arch expansion gained using the BWS. Lower alignment is re-evaluated throughout this stage of i-2 Trainer use. Often, as can be demonstrated in the cases selected, lower alignment and arch form improves because of the maxillary expansion and peri-oral musculature functional improvement (Fig. 4).

The BWS is held in place using standard ligatures placed around the BWS tube as pictured (Fig. 5).

The following two cases show the effect of the BWS Orthodontic System on arch development.

Case No. 1

This 10-year-old female patient

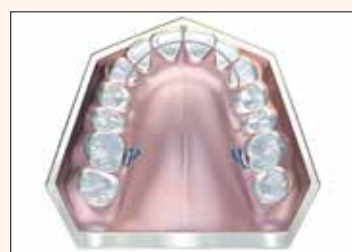


Fig. 1: Photos/Provided by Drs. German O. Ramirez-Yañez and Chris Farrell.

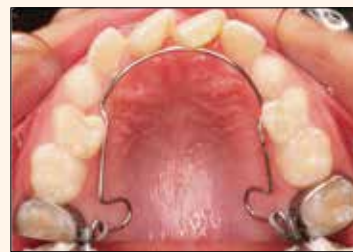

Fig. 2

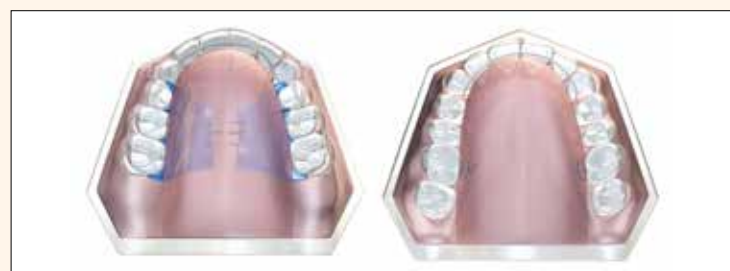

Fig. 3

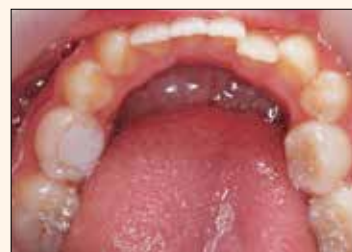

Fig. 4a

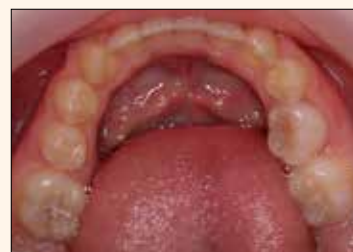

Fig. 4b

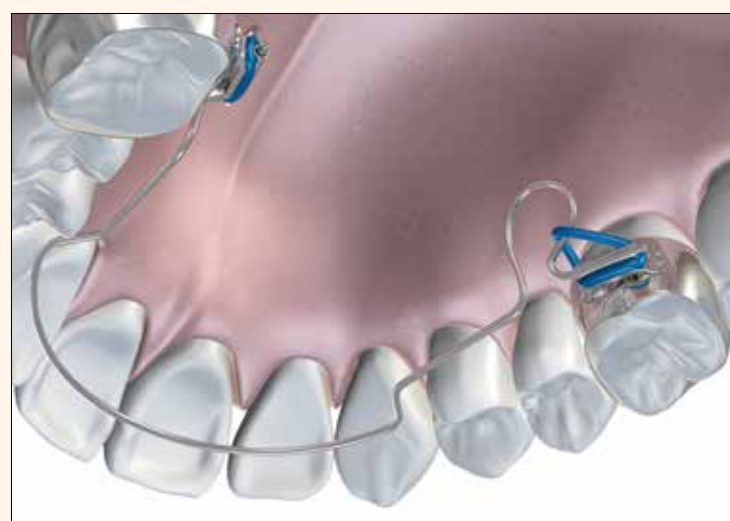

Fig. 5

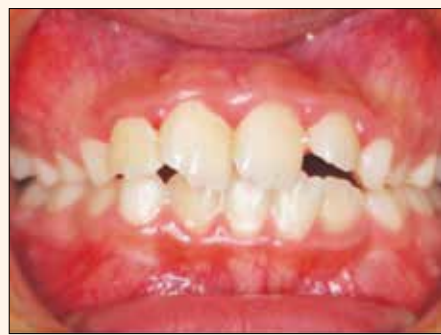

Fig. 6a

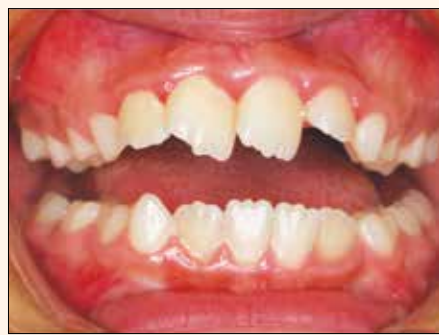

Fig. 6b

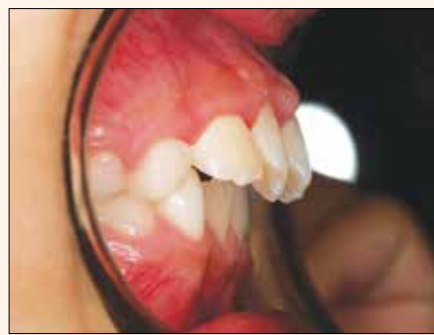

Fig. 6c

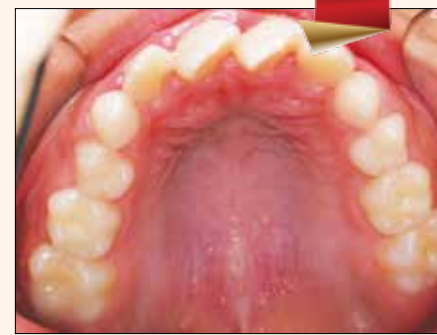

Fig. 6d

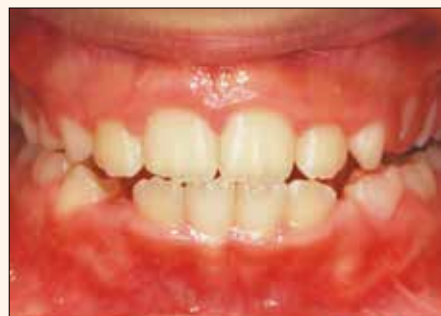

Fig. 7a

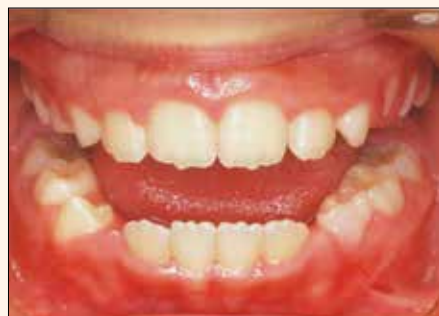

Fig. 7b

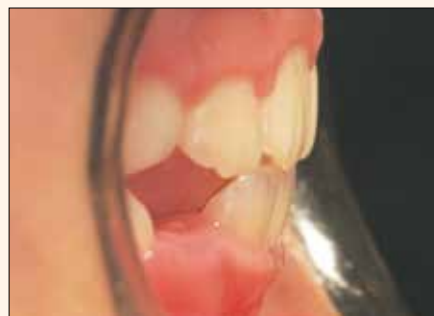

Fig. 7c

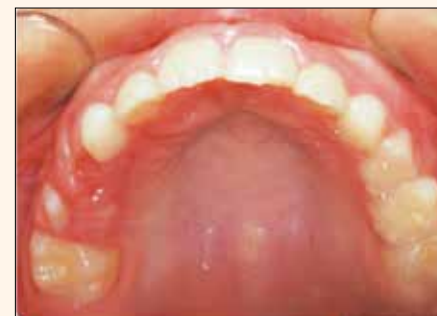

Fig. 7d

consulted because of a crowded dentition involving unusually misaligned upper central incisors with a midline shift of 10 mm and with lost “c” space on the lower left side. The parents requested that the treatment be non-extraction, although they had previously been advised that future orthodontic treatment might require this option (Fig. 6).

The occlusion was classified as Class I with normal slight overjet and with normal overbite. No skeletal alteration was found on cephalometric measurements and analysis of cast models reported a lack of arch development. This case was diagnosed as a Class I malocclusion with underdevelopment of both dental arches. Midline shift was primarily as a result of the lost lower “c” space. Soft-tissue analysis showed a mouth-open posture and hyperactive peri-oral musculature. It was considered the myofunctional habits were a contributing factor to the malocclusion and, thus, a suitable case for the BWS and Trainer combination prior to fixed appliances once the permanent dentition was fully erupted.

The plan of treatment involved a first phase with a BWS for the upper arch combined with an I-2n Trainer — “n” for no core or cage for increased flexibility and use with the BWS. The i-2n Trainer was used one hour daily plus overnight while sleeping. Monthly adjustment to the activating loops of the BWS were made in increments of 1-2 mm per month.

This treatment was continued for four months, after which time the upper BWS was removed and i-2 Trainer was used to maintain the expansion achieved by the BWS. The i-2 Trainer also encouraged the tongue to assist in maintaining the maxillary expansion without retainers. At this stage, the lower arch form and dental alignment was assessed and showed considerable improvement. It was noted the space for the lower left permanent canine had increased — an effect thought to be produced by the combination of maxillary arch expansion and correction of myofunctional habits. The midlines were also self-correcting.

Space for the lower canines was ultimately achieved without a lower BWS.

The case is further improved by continued use of the i-2 Trainer

and the Myobrace Regular™ to exploit the eruption stage prior to treatment finalization with fixed appliances as required.

The observation of the effects and benefits of the BWS Orthodontic System are evident from this case, and the concepts are not new to orthodontics. Maxillary expansion tends to also improve the lower arch length and assists the orthodontist in achieving non-extraction outcomes with more stable results because of simultaneous correction of tongue position and retraining of the peri-oral musculature. The second phase of treatment did not require the BWS on the lower arch as arch development during the treatment period sufficiently opened the space for the lower permanent canine. The lower anterior dentition did not require the use of fixed appliances (Fig. 7). Thus, this case was treated in a 2-year period, required minimal chair side time and a difficult extraction case was converted to a simple, non-extraction case.

Case No. 2

This 12-year-old female patient consulted because of very underdeveloped maxillary arch form and ectopic erupting canines (Fig. 8). This is far from an ideal stage to be considering non-extraction treatment; however, the parent insisted that the case was attempted non-extraction. The lower anterior teeth were also considerably crowded, and it would regularly be justified in extracting the first four premolar teeth and going into upper and lower straight wire fixed appliances.

It could be argued that treating non-extraction will prolong the treatment and certainly incur greater expense on the parent. However, there is a growing demand from parents who have had extraction orthodontics in the past to avoid this approach for their children. Therefore, the BWS Orthodontic System can be a beneficial technique that the orthodontist can use in these exceptional cases.

Treatment was similar to case 1. An upper BWS was fitted and combined with the use of the i-2n Trainer initially for four months, after which time the BWS wire was removed, leaving the molar bands in place. The i-2 Trainer was introduced at this stage for a further three months to maintain the expansion prior to a second phase of treatment

using the BWS and i2n Trainer for three months (as mentioned earlier in this article).

This allows the dentition to “catch up” and prevents excessive tooth mobility. It is thought that much of the expansion achieved by this system is dento-alveolar rather than sutural, as with a rapid maxillary expander and other acrylic expanders. Also, there is more development in the anterior arch form, which is an effect previously found in the research on the Trainer (Ramirez-Yañez, 2005b).

The difficulty in cases like this, requiring large amounts of expansion to achieve a non-extraction result, is a tendency to create an open bite. Although this occurs to some extent, the BWS Orthodontic System does not open the bite as much as more conventional techniques because the tongue position is favorably altered by use of the Trainer. This conjecture may require further investigation to ratify.

Once again, spontaneous alignment of the lower anterior dentition has occurred without the requirement for an additional BWS for the lower arch. This effect is not just restricted to these two cases but is a routine observation of the BWS Orthodontic System. This case also illustrates the stability achieved in the lower dentition as no retainers were used apart from night use of the Trainer.

Although this patient is not at the ideal age, the pictures show that it was possible to obtain space for all permanent canines, without extractions and with good stability.

The bite opening is minimal and tends to decrease with further dental development. Although this case was finalized with the Myobrace Regular™ from MRC, fixed appliances on the upper arch would possibly have delivered quicker results following the BWS Orthodontic System. The assistance of correcting the forces delivered by the muscles of the cheek (buccinator) and lips (orbicularis oris) at swallowing cannot be ignored and is a key part of the *modus operandi* of this expansion system.

After two years of treatment and observation, along with night-time retention using the i-2 Trainer for 12 months after treatment, the BWS produced enough upper arch development to not only accommodate the erupting canines, but also

achieve lower anterior alignment with minimal intervention and minimal retention (Fig. 9). This case was a more extreme example that orthodontists will face in the future as more parents demand the non-extraction option with minimal use of multi-bracket systems.

Conclusions

Maxillary and mandibular expansion has been shown to be an excellent alternative to increase the arch perimeter and, thus, to avoid the need for extractions to properly align teeth. This paper has presented two cases treated using the BWS Orthodontic System, which involves the combination of two appliance systems: the Trainer, a pre-fabricated functional appliance, and the BWS.

Both appliances, Trainer and

BWS, have to be used in order to get the results reported in this paper. The BWS Orthodontic System showed in these two cases and in many cases treated by the authors is an excellent means to produce arch development in both upper and lower dental arches in a short time.

The effect of the BWS Orthodontic System on arch development does not change the inter-maxillary relationship when a Class I occlusion exists at the beginning of treatment.

However, when a Class II malocclusion associated to a crowded dentition is present the BWS Orthodontic System produces arch development and, at the same time, the mandibular relocation

> Page 10

mCME SELF INSTRUCTION PROGRAM

CAPPmea together with Dental Tribune provides the opportunity with its mCME - Self Instruction Program a quick and simple way to meet your continuing education needs. mCME offers you the flexibility to work at your own pace through the material from any location at any time. The content is international, drawn from the upper echelon of dental medicine, but also presents a regional outlook in terms of perspective and subject matter.

Membership:

Yearly membership subscription for mCME: 900 AED
One Time article newspaper subscription: 250 AED per issue.
After the payment, you will receive your membership number and allowing you to start the program.

Completion of mCME

- mCME participants are required to read the continuing medical education (CME) articles published in each issue.
- Each article offers 2 CME Credit and are followed by a quiz Questionnaire online, which is available on <http://www.cappmea.com/mCME/questionnaires.html>.
- Each quiz has to be returned to events@cappmea.com or faxed to: +97143686885 in three months from the publication date.
- A minimum passing score of 80% must be achieved in order to claim credit.
- No more than two answered questions can be submitted at the same time
- Validity of the article – 5 months
- Validity of the subscription – 1 year
- Collection of Credit hours: You will receive the summary report with Certificate, maximum one month after the expiry date of your membership. For single subscription certificates and summary reports will be sent one month after the publication of the article.

The answers and critiques published herein have been checked carefully and represent authoritative opinions about the questions concerned.

Articles are available on www.cappmea.com after the publication. For more information please contact events@cappmea.com or +971 4 3616174

FOR INTERACTION WITH THE AUTHORS FIND THE CONTACT DETAILS AT THE END OF EACH ARTICLE.