

# DENTAL TRIBUNE

— The World's Dental Newspaper • Middle East & Africa Edition —

PUBLISHED IN DUBAI


July-August 2010

No. 6 Vol. 8



**News & Opinions**  
Saudi Judge Asks Doctors To  
Damage Criminal's Spine

► Page 2



**Media CME**  
Class II Challenge

► Page 6



**Dental Cafe**  
Black couple have white  
baby

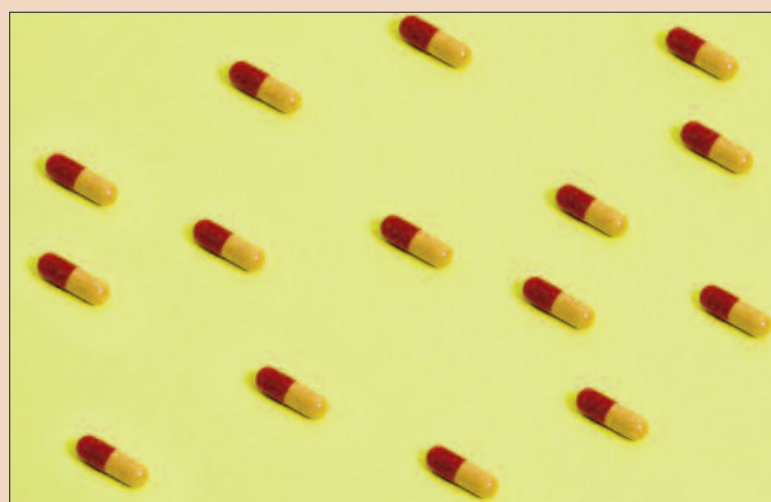
► Page 10

## Asian 'Superbug' causes trouble worldwide

Daniel Zimmermann  
DTI

HONG KONG/LEIPZIG, Germany: The emergence of a bacteria-resisted genetic mutation in Asia and other countries is posing a significant threat to global health, a multinational team of researchers reports. According to their study published in the current issue of The Lancet Infectious Diseases, evidence of increased prevalence of a gen that makes bacteria resistant to antibiotics was detected in Enterobacteriaceae isolated in India, Pakistan and the UK. The researchers called for co-ordinated international surveillance of the enzyme to prevent its spread through medical and dental tourism.

New Delhi metallo-beta-lactamase (NDM-1), which was first identified by UK Professor Tim Walsh in a hospital in India last year, has been found to be resistant in a wide range of antibiotics including penicillin and amoxicillin which are commonly used after dental procedures. In addition, it also affects the efficiency of carbapenems, a group of antibiotics



reserved for use in emergencies when other antibiotics have failed.

Prof. Walsh told the New Scientist that due to travelling and medical tourism throughout the region, bacterial mutations like NDM-1 increasingly find their way from India and Pakistan to other countries. He said meanwhile the gene has been turning up from being rarely observed just a few years ago to in between 1 and 3 per cent of all infections involving Enterobacteriaceae. Mutated genes have been

recently isolated, for example, in the United States, Sweden, Turkey, Israel, Greece, and the UK, he said.

Infectious disease experts have warned clinicians be increasingly aware of the possibility of NDM-1-producing bacteria in patients who have received medical services in India and Pakistan. They are also advised to specifically inquire about this risk factor when carbapenem-resistant Enterobacteriaceae are identified in their country. [DTI](#)

## Dentist seeks US class action suit vs Nobel Biocare

STOCKHOLM - Swiss dental implant maker Nobel Biocare has been sued by a California dentist seeking class-action status on behalf of dentists whose patients have suffered complications such as bone loss from one of its products.

A company spokesman said on Monday the NobelDirect dental implant was safe and that Nobel Biocare (NOBN.VX) would fight the lawsuit, which was filed in the U.S. District court in Los Angeles.

The suit by Jason M Yamada seeks compensation for dentists who have had to perform surgery on their patients, or pay for restorative surgery, after compli-



cations from the implants, which it said were defectively designed.

"Because of Nobel's practices, plaintiff and the class members now face a flood of complaints from injured dental patients who have needed, and will need, immediate intervention to remove

→ [DTI](#) page 2

آیا میدانید؟

DENTAL TRIBUNE

پرمخاطب ترین نشریه درمانی دنیاست و به تمامی زبانهای دنیا در بیش از ۹۰ کشور دنیا منتشر میشود....

در حال حاضر با تیراژ ۲۰۰۰ نسخه برای تمامی کلینیک ها و دندانپزشکان منطقه بطور مستقیم ارسال میگردد.

برای تبلیغ و گسترش کار خود در منطقه، میتونید با شایان سیمین طب به شماره ۰۲۱-۹۸۰۳۶۴۵ تماس بگیرید

AD

# PROMEDICA

Highest quality made in Germany

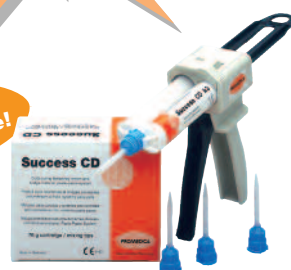- high quality glass ionomer cements
- first class composites
- innovative compomers
- modern bonding systems
- materials for long-term prophylaxis
- temporary solutions
- bleaching products...

All our products convince by

- excellent physical properties
- perfect aesthetical results

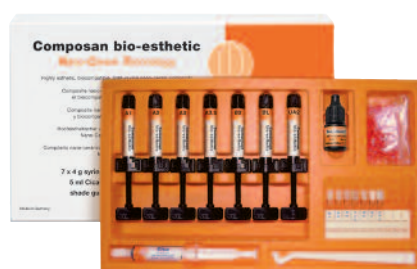Meet us at  
several exhibitions -  
[www.promedica.de](http://www.promedica.de)

New:  
Bleach Shade!



**Temporary crown and bridge material**

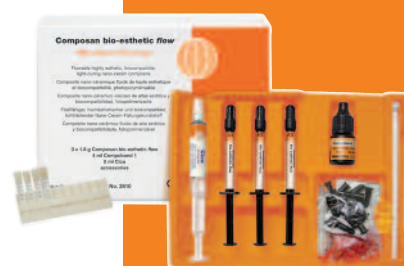- particular fracture and wear resistance
- now available in 6 attractive shades



**Light-curing nano-ceram composite**

- universal for all cavity classes
- comfortable handling, easy modellation
- highly esthetic and biocompatible

Nano-Ceram-Technology



• exact match of translucency and shade to the packable Composan bio-esthetic



**Resin-reinforced glass ionomer luting cement**

- strong adhesion, very low film thickness
- especially suited for zirconia-based pieces

PROMEDICA

**PROMEDICA Dental Material GmbH**  
Tel. +49 43 21 / 5 41 73 · Fax +49 43 21 / 5 19 08  
Internet: <http://www.promedica.de> · eMail: [info@promedica.de](mailto:info@promedica.de)



# Saudi Judge Asks Doctors To Damage Criminal's Spine



A Saudi judge has asked several hospitals if they are willing to damage a man's spinal cord as punishment for a cleaver attack that left a 22-year-old paralysed.

The victim, Abdul-Aziz al Mutairi, became paralysed and subsequently lost a foot after a fight more than two years ago.

An unnamed man was sentenced to 14 months in prison for the assault, but released after serving only half that time.

The shortened jail time has reportedly enraged Mr Mutairi's family.

His 27-year-old brother Khaled said they want an equivalent punishment for the attacker and have appealed to a judge in northwestern Tabuk province.

"We are asking for our legal right under Islamic law," the brother said.

"There is no better word than God's word - an eye for an eye."

The judge has since asked several hospitals if medical paralysis was possible and would they perform the operation. Local newspapers reported a facility in the capital Riyadh had declined, saying it could not inflict such harm.

Saudi Arabia enforces strict Islamic law and occasionally hands out punishments based on the ancient legal code.

Amnesty International has expressed concerns over the reports and said it was contacting Saudi authorities for details.

"We are very concerned and we will appeal to the authorities not to carry out such a punishment," said Lamri Chirouf, the group's researcher on Saudi Ara-

bia. He added this was the first time Amnesty had heard of a punishment involving the damaging of a spinal cord.

"It's hard to follow details of the Saudi justice system. People are sentenced in closed trials with no access to the public and no lawyers." DT

## Editorial Board

Prof. Abdullah Al-Shammary, Restorative Dentistry, KSA  
Prof. Hussain F. Al Huwaizi, Endodontics, Iraq  
Prof. Samar Burgan, Oral Medicine, Jordan  
Dr. Abdel Salam Al Askary, Implantology, Egypt

Dr. Talal Al-Harbi, Orthodontist, Qatar  
Dr. Mohammed H. Al Jishi, Bahrain  
Dr. Lara Bakaeen, Prosthodontist, Jordan  
Dr. Aisha Sultan, Periodontist, UAE  
Dr. Kamal Balaghi Mobin Aesthetics, Iran

## DENTAL TRIBUNE

The World's Dental Newspaper - Middle East & Africa Edition

## Published by Education Zone

in licence of Dental Tribune International GmbH

© 2010, Dental Tribune International GmbH. All rights reserved.

Dental Tribune makes every effort to report clinical information and manufacturer's product news accurately, but cannot assume responsibility for the validity of product claims, or for typographical errors. The publishers also do not assume responsibility for product names or claims, or statements made by advertisers. Opinions expressed by authors are their own and may not reflect those of Dental Tribune International.

### President/CEO

Yasir Allawi  
y.allawi@dental-tribune.ae

### Director mCME:

Dr. D. Mollova  
info@cappmea.com

### Marketing manager

Khawla Najib  
khawla@dental-tribune.ae

### Production manager

Hussain Alvi  
dentalme@dental-tribune.ae

PO Box 214592, Dubai, UAE, Tel + 971 4 391 0257  
Fax + 971 4 366 4512 [www.dental-tribune.com](http://www.dental-tribune.com)

# DENTISTRY 2010

9 - 11 November 2010 • Abu Dhabi National Exhibition Centre, UAE



## The Definitive Dentistry Event in the Middle East

Email [dentistry@iirme.com](mailto:dentistry@iirme.com) and reserve your copy of the 2010 conference programme. The conference will feature the most up-to-date information on the diagnosis and treatments available from international experts including:



### Renowned Dental Personality

**Prof Nasser Barghi,**  
Professor and Head of Division - Esthetic Dentistry,  
University of Texas, San Antonio, USA

- Past president of the American Equilibration Society
- 650 didactic and "hands-on" clinical course presentations
- 30 countries
- 250 articles (authored and co-authored)
- Research focus: porcelain bonded restorations



### Award Winner: Excellence in Dental Education

**Prof Patricia Reynolds,**  
Director of Flexible Learning -  
Dental Institute, King's College, UK

- Chair (appointed): Dental Education - King's College
- Finalist: Times Higher Education Awards
- Awarded commendation: Medical Futures Innovative Project - IVIDENT
- Author: e-learning - British Dental Journal
- Founder: Anglo-Italian Colloquium (Now spread over 12 countries - International Innovations Colloquium)
- External Examiner and Advisor: Open University, UK



### Diplomate of the American Board of Oral Medicine

**Prof Juan Yepes,**  
Associate Professor and  
Director of Radiology,  
University of Kentucky, USA

- Clinical focus on:
  - Medically compromised patients
  - Orofacial pain
  - Oral pathology
  - Oral radiology
  - Oral pain

Register your delegate place today -  
[www.dentistryme.com](http://www.dentistryme.com)

← DT Page 1

the defective implants," the lawyers Lopez McHugh and Audet & Partners wrote in the 26-page complaint.

The suit proposed a class action to cover thousands of dentists in the U.S. who have used the NobelDirect implant, adding that Nobel Biocare had knowledge of the defect, but marketed the implant as safe and effective.

The Swedish Medical Products Agency investigated the same implants in 2005 to 2006 after complaints about bone loss. The company got approval to continue sales, but the agency told it to revise instructions and marketing material. DT



Supported By



Organised By



Member Of



Media Partners



Priority Code DT08

T +971 4 336 7334 F +971 4 336 4021 E [dentistry@iirme.com](mailto:dentistry@iirme.com)

[www.dentistryme.com](http://www.dentistryme.com)





3M ESPE has given dentists across the region the opportunity to try its newest universal restorative, the Filtek™ Z350 XT Universal Restorative which has now been available on the market for just over three months. This new restorative combines the best attributes of preceding Filtek restoratives, to deliver even better esthetic qualities through an expanded range of body shades. This offers more universal options for creating easy, natural-looking, one-shade restorations, while maintaining the composite's versatility for dual or multi-layering techniques.

"With Filtek Z350 XT, we've modified the technology to maintain the excellent handling dentists love while improving upon polish retention and simplifying the shading system." As the first and only composite system to incorporate true nanotechnology, the Filtek line has gained a strong following over the past six years for its ability to provide the polish and polish retention of a microfill, while maintaining the strength and wear properties of a modern hybrid.

Speaking of the trials Dr. Samer Aouad, Scientific Marketing Supervisor-3M ESPE - Middle East and Africa, said: "Feedback from dental professionals is at the core of 3M ESPE innovation, and it's what allows us to take industry-leading composite technology and make it even better." The responses were very positive indicating the product will be a dentistry success story.

"I have been using 3M ESPE for 10 years now and have never compromised on quality. I only use the best for my patients and 3M ESPE is known for the high quality of their product. The new Z350 XT is by far the best product that I have even seen in terms of polishability, shade and shrinkage," said Dr. Riyas Jamaluddin, UAE dentist.

The new product combines and improves on past Filtek restoratives creating one simple choice for universal application. Dentists can now choose from four opacities—dentin, body, enamel and translucent—and numerous shades to create a match for every patient. This wide range of shades and opacities gives dentists more options to achieve a beautiful outcome through single, dual or multi-layered techniques.

"The Z 350 XT is a winner. It is easy to handle and it is not sticky. It is easy to sculpt and pack and has predictable esthetic results as the change after polymerization is not significant. The opalescence, translucency and reflection of the light are also impressive. Finally Filtek Z350 XT has excellent polishing characteristics and polishes to a real nice shine and I love the fact that it is a nano-composite," Dr.

## Middle East dentists experience Filtek™ Z350 XT Universal Restorative for the first time

*Professionals are impressed with the product's results*

Ajay Juneja, UAE Specialist Prosthodontist.

"With Filtek Z350 XT, the creation of art in dentistry has become easier. I now get beautiful results using both the single and multi

shade technique," said Dr. Aziz Lammam, UAE Dentist.

"I have been using 3M composite for more than 17 years and I recently tried the Z350 XT. It gives by far the most beautiful results I have

seen to date!" Dr. Mouen Junblat, UAE Dentist.

Additional advancements include even better polish retention of dentin, body and enamel shades, as well as improved handling of

translucent shades. Beyond the product attributes, additional simplification is seen in the form of new, bold labeling and color-coded opacities, which simplify the shade selection process. [\[4\]](#)

AD

## كلية نيقولا وآسب الجامعية NICOLAS & ASP UNIVERSITY COLLEGE

The 1st Accredited Dental Postgraduate Training Programs in the UAE

Register NOW...

### Masters In Orthodontics

- 5th Intake (February 2011)
- 3 years study in UAE
- Recognized by Swedish National Board of Health and Welfare
- Accredited by
  - UAE Ministry of Higher Education
  - Malmö University, Sweden
  - Saudi Commission for Health Specialities

### Masters Degree in Pediatric Dentistry


- Intake - extended (September 2010)
- 3 years study in UAE
- Accredited by
  - UAE Ministry of Higher Education

### High Diploma In Oral Implantology

- 5th Intake (September 2010)
- 1 year (modules) for practicing dentists and specialists
- Program is offered in cooperation with Gothenberg University, Sweden
- Accredited By UAE Ministry of Higher Education & Scientific Research

Unique group of European & American faculty

For more information: Tel.: 00971 43624788



### Abu Dhabi Headquarters

Admission Office:  
Al Odaid Office Tower, Airport Road, Abu Dhabi, UAE  
10th Floor, Office 1201  
Telephone: +971 2 404 7141

### Dubai Branch

Dubai Healthcare City  
Ibn Sina Building (No. 27)  
Block D, 3rd floor, Office 302  
Telephone: +971 4 3624787

Fax: +971 4 362 4793

P.O. Box: 53382, Dubai, UAE

Website: [www.dubaipostgraduate.com](http://www.dubaipostgraduate.com)

Email: [info@dubaipostgraduate.com](mailto:info@dubaipostgraduate.com)



# Crown or same-day onlays – A clinical example

## The advantages of indirect composite resin restorations

Dr Lorin Berland  
USA

*"The trend in dentistry today is clearly toward more aesthetic and less invasive. Indirect resin and ceramic inlays and onlays are not only compatible with this trend, but fulfil very nicely the restorative void between fillings and crowns,"*  
Dr Ronald D. Jackson (*Cosmetic Dental Tribune*, December 2008).

In terms of durability, aesthetic inlays and onlays are no longer new. They have a track record—a good one. With today's materials, longevity is mainly a matter of diagnosis, correct treatment planning and proper execution of technique. The problem with replacing old amalgams with tooth-coloured composites lies in its difficulty. In addition, they tend to be inconsistent and unpredictable.

But the warranty on these 30-, 40-, 50-year-old silver fillings is

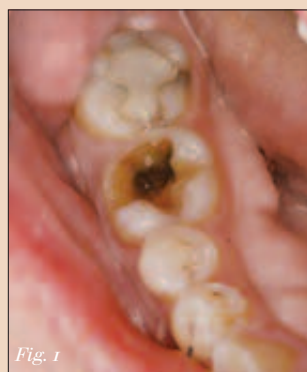

Fig. 1

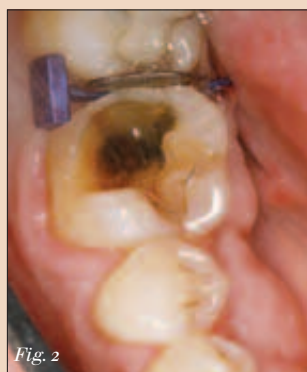

Fig. 2

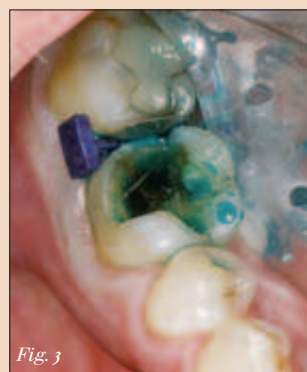

Fig. 3

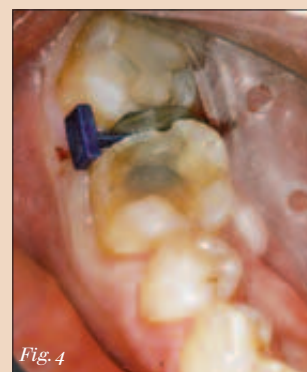

Fig. 4

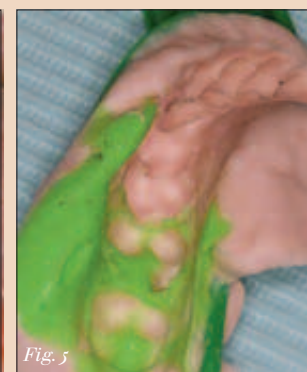

Fig. 5

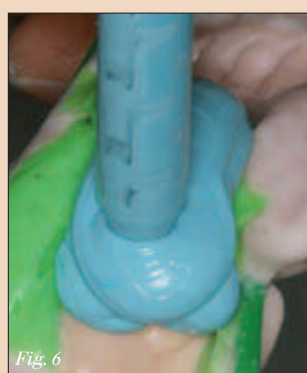

Fig. 6

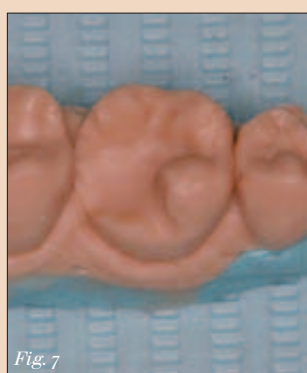

Fig. 7

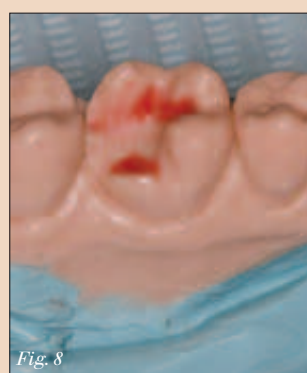

Fig. 8

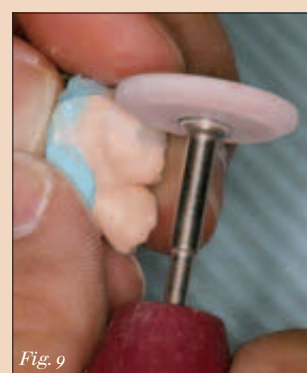

Fig. 9

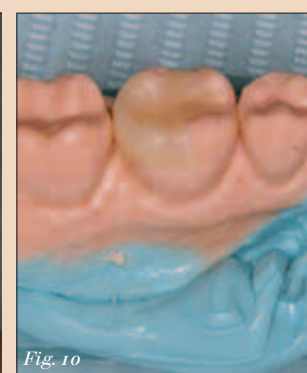


Fig. 10

Fig. 1: #30 pre-op. — Fig. 2: FenderWedge in place. — Fig. 3: Caries detector. — Fig. 4: Preparation with liner. — Fig. 5: Identical Hydrocolloid impression.


Fig. 6: Basing the poured impression. — Fig. 7: Silicone model. — Fig. 8: Model with undercuts waxed. — Fig. 9: Finishing the onlay. — Fig. 10: Onlay finished and polished.

AD

## FDI Annual World Dental Congress


# 2-5 September 2010

## Salvador da Bahia, Brazil



congress@fdiworldental.org

www.fdiworldental.org



BRAZIL SALVADOR DA BAHIA 2010

running out. We have to remember that amalgam technology is over 150 years old. At that time, people lost their teeth much earlier and died a lot earlier, too. Nowadays, however, we have a large and growing segment of the population that is over 50 years old – and they want to keep their teeth functioning well and looking good. Let's think the same way our patients do. They want to replace these old amalgams, but they want to do it conservatively, consistently, efficiently, predictably and economically. They also want us to do it in one visit. So, what are the advantages of indirect, laboratory-processed, composite resin, posterior restorations?

Restorations fabricated in this manner look better, undergo less shrinkage, help restore the strength of the tooth, have minimal porosity and excellent marginal integrity. They are also very durable and have smoother surfaces that are kinder to the gums and result in less plaque accumulation. Patients appreciate avoiding the inconvenient, uncomfortable and expensive second appointment because no second appointment means no temporaries, no emergency visits, and best of all, the preservation of healthy tooth structure.

By contrast, replacing amalgam restorations with direct posterior composites, especially ones involving an interproximal surface, are difficult for the patient as well as the dentist. For many reasons, these direct composite replacements frequently prove to be inadequate, especially over time. The inherent problems of isolation, the large bulk of composite required, the layered curing of the composite and the effects of shrinkage all affect contacts, occlusion, margins and post-operative tooth sensitivity. Gold will always be an excellent restoration material for posterior teeth, but because of its appearance, mass and increasing price, it is becoming increasingly undesirable in today's image-conscious society.

### The preparation

The patient in this clinical case came in with a dental emergency. The filling had fallen out of his broken, lower right molar the day before he was going overseas for three weeks on business. He wanted a quick and permanent solution (Fig. 1). The tooth was anesthetised. Next, a FenderWedge (Directa Dental) was used to further isolate the tooth involved, protect the adjacent interproximal surface and pre-wedge the teeth for optimal contacts (Fig. 2). The Isolite (Isolite Systems) was placed to obtain a dry, illuminated field. We used a caries detector to ensure complete decay removal (Fig. 3). The tooth was then micro-etched, etched and desensitised with HemaSeal and Cide (Advantage Dental Products, Inc.). Two layers of a self-etching bonding agent (OptiBond All-In-One Unidose, Kerr Dental) were applied to provide reduced post-operative sensitivity and high dentine bond strength. This was then air-thinned and light-cured. Flowable composite (Premise Flowable, Kerr Dental) was added to the internal walls and floor, creating an even floor and filling in undercuts that were originally prepared for caries removal and amalgam retention (Fig. 4). After the tooth had been insulated, the preparation was refined with a flat-end cylinder, fine-grit, short-shank diamond. Two identical hydrocolloid impressions (DUX Dental) were taken to make the onlay in the laboratory (Fig. 5).

After disinfecting the impressions, the assistant immediately poured moulds using MACH-SLO (Parkell, Inc.) and based them using a rigid, fast-setting bite registration material (e.g. Blu-Mousse, Parkell, Inc.; Fig. 6). Within two minutes, we had a silicone working model on which to build the onlay (Fig. 7). Undercuts were blocked out with a waxer, carefully avoiding the margins (Fig. 8). Starting with the Premise Indirect (Kerr Dental) dentinal shades and ending with incisal shades, the onlay was incre-



mentally fabricated in layers and then placed in the Premise curing oven (Kerr Dental). In approximately 10 minutes, it was ready to be finished with various finishing burs (Fig. 9). It was polished to a high shine and then checked on the model to verify accurate interproximal contacts and margins (Fig. 10).

Seating the onlay

When seating the onlay, the Iso-lite was re-applied for isolation, ease of placement and patient comfort during cementation of the onlay. Prior to cementation, Expasyl (Kerr Dental) was gently packed into the sulcus, creating a dry space between the tooth and tissue without any risk of rupturing the epithelial attachment (Fig. 11). The aluminium chloride dries the tissue, reducing the risk of sulcal seepage and contamination. The FenderMate (Directa Dental) was then inserted beneath the interproximal floor to slightly separate and isolate the adjacent teeth and to help facilitate seating the onlay (Fig. 12). The remaining Expasyl paste was rinsed off thoroughly and the FenderMate was adapted to the adjacent interproximal surface with a condenser (Fig. 13). The enamel and composite core were then etched for 15 to 30 seconds.

A single component fifth-generation adhesive (OptiBond Solo Plus Unidose, Kerr Dental) was applied in two coats and air-thinned until there was no more movement. Flowable composite (Premise Flowable) was dispensed into the prepared tooth prior to inserting the onlay into the tooth. The FenderMate was removed and the onlay was further seated using a condenser with gentle pressure. Complete seating was facilitated using the contra-angle packer/condenser (Fig. 14). An explorer is helpful in removing excess flowable before curing.

The restoration was cured from all angles, starting at the interproximal gingival floors where leakage is most likely to occur. Occlusal flash and excess flowable composite was buffed with a short flame carbide, while the interproximal margins were adjusted with bullet or needle carbides. A Bard-Parker #12 scalpel was used to remove interproximal cement. Once the proper occlusion had been established, a diamond-impregnated point and cup were used to polish the restoration (Fig. 15).

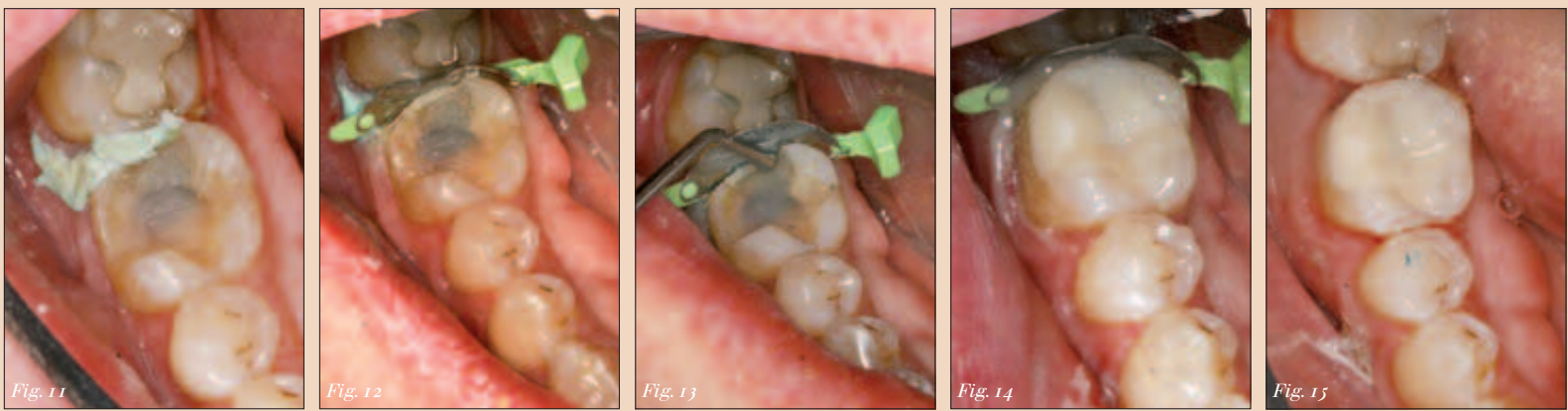



Fig. 11: Expasyl prior to seating. — Fig. 12: Expasyl and FenderMate prior to seating. — Fig. 13: Adapting FenderMate. — Fig. 14: Seating onlay. — Fig. 15: Final onlay.

VITABLOCS RealLife® – ingeniously three-dimensional.

At a simple mouse click: truly natural anterior esthetics with 3D dentine core-enamel structure!



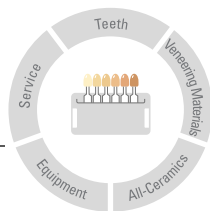
Contact Info



Dr Lorin Berland maintains a private dental care centre in Dallas, USA. He can be contacted at drberland@dallasdentalspa.com.



VITA SYSTEM



3D-MASTER

VITA

The innovative VITABLOCS RealLife for CEREC/inLab MC XL are especially designed for highly esthetic anterior restorations. Just like natural tooth structure, the three-dimensional block structure with dentine core and enamel coat imitates the curved shade transitions between dentine and incisal edge. The VITABLOCS have been clinically proven millions of times over.

Fax +49(0)7761/562-281  
Phone +49(0)7761/562-0

☐ Please send me more info!  
☐ Please arrange a consultation appointment for me!

Practice/Laboratory, Contact: \_\_\_\_\_

Street, Number: \_\_\_\_\_

Zip-Code/Town/City: \_\_\_\_\_





# Class II challenge

*Clinical solutions to common problems when placing Class II direct composites*

The article has been accredited by Health Authority - Abu Dhabi as having educational content and is acceptable for up to 2 (Category 1) credit hours. Credit may be claimed for one year from the date of subscription.

By Robert Lowe, DDS, FAGD, FICD, FADI, FACD

Direct composite restorations that involve posterior proximal surfaces are still a common finding in many dental patients.

Unlike dental amalgam, which can be a very forgiving material technically and can be condensed against a matrix band to create a proximal contact, proper placement of composite restorative materials presents a unique set of challenges for the operative dentist.

The adhesion process itself is well understood by most clinicians as far as isolation and execution, however, there are some steps in the placement process that cause difficulty and ultimately lead to a less than desirable end result.

In this article we will look at three specific areas: management of the soft tissue in the interproximal region; creation of proximal contour and contact; finishing and polishing of the restoration.

## Management of the interproximal gingival tissue

The most common area for the adhesion process to fail is the proximal gingival margin. Compounding this problem is the inability to gain access to the area to effect a repair without removal of the entire restoration.

As stated by Dr. Ron Jackson, bonded restorations are unique in that minor defects (decay or microleakage) at the marginal interface can often be “renewed,” or repaired by removal of the affected tooth structure and repaired with additional composite restorative material.

Because of the bond of the restorative material to enamel and dentin,

the recurrence is usually self-limiting. This is not true with metallic restorations that are not bonded to tooth structure. However, if the defective area is at the proximal gingival margin or line angle, access is not possible.

Therefore, precise marginal adaptation of the direct composite restorative material and the seal of this margin in the absence of moisture or sulcular fluid contamination is of paramount importance.

However, whether due to the subgingival level of decay and/or gingival inflammation, it can be difficult to seal the gingival margin with a matrix in the presence of blood.

## Proximal contact and contour

Another challenge for the dentist has always been to re-create contact to the adjacent tooth and, at the same time, restore proper interproximal anatomic form given the limitations of conventional matrix systems.

The thickness of the matrix band and the ability to compress the periodontal ligaments of the tooth being restored and the one adjacent to it can sometimes make the restoration of proximal tooth contact arduous at best.

Anatomically, the posterior proximal surface is convex occlusally and concave gingivally. The proximal contact is elliptical in the buccolingual direction and located approximately one millimeter apical to the height of the marginal ridge.

As the surface of the tooth progresses gingivally from the contact point toward the cemento-enamel junction, a concavity exists that houses the interdental papilla.

Conventional matrix systems are

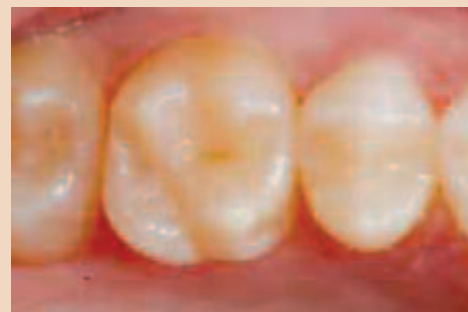

Fig. 1: This occlusal preoperative view shows a maxillary molar that has radiographic decay on the mesio-proximal surface.

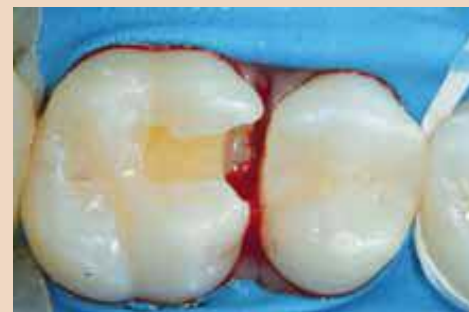

Fig. 2: After the cavity preparation is completed, bleeding is seen in the proximal area.

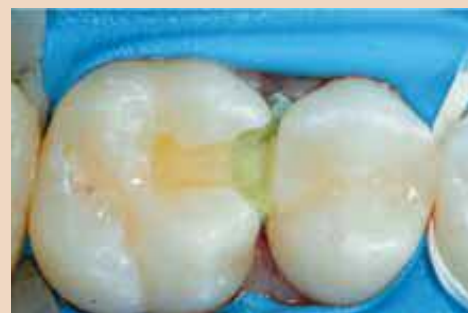

Fig. 3: Expa-syl (Kerr) is placed into the proximal area with the delivery syringe then tapped to place using a dry cotton pellet.

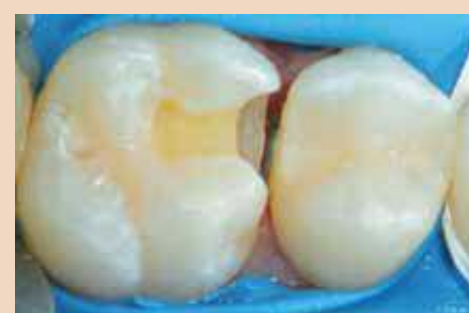

Fig. 4: After rinsing away the majority of the Expa-syl (note that a small amount of Expa-syl remains sub-marginal for additional hemorrhage control), the proximal tissue is deflected away and bleeding is absent, allowing for easy placement of the sectional matrix band.

made of thin, flat metallic strips that are placed circumferentially around the tooth to be restored and affixed with some sort of retaining device.

While contact with the adjacent tooth can be made with a circumferential matrix band, it is practically impossible to re-create the natural convex/concave anatomy of the posterior proximal surface because of the inherent limitations of these systems.

Attempts to “shape” or “burnish” matrix bands with elliptical instrumentation may help create nonanatomic contact, but only “distorts” or “indents” the band and does not re-create complete natural interproximal contours.

Without the support of tooth contour, the interdental papilla may not completely fill the gingival embrasure, leading to potential food traps and areas for excess plaque accumulation. Direct Class II composite restorations can present even more of a challenge to place for the dentist because of the inability of resin materials to be compressed against a matrix to the same degree as amalgam, making it difficult to create a proximal contact.

## Finishing and polishing composite restorations

Direct composite material does not carve like amalgam, although many clinicians wish that it did! Unfortunately, this means that most posterior composites are carved with a bur.

This is not part of the finishing and polishing of the restoration. It must be remembered that cuspal forms

are convex and cannot be carved with a convex rotary instrument that imparts a concave surface to the restorative material.

Composite should be incrementally placed and sculpted to proper occlusal form prior to light curing. The finishing and polishing process is done to accomplish precise marginal adaptation and make minor occlusal adjustments.

Rubber abrasives further refine the surface of the composite, and surface sealants are used to gain additional marginal seal beyond the limitations of our instrumentation.

## Case report

The patient shown in Figure 1 presented with radiographic decay on the mesial proximal surface of tooth No. 3. The operative area is isolated using an OptiDam (Kerr Hawe). The decay is minimal, so the operative plan is to keep the preparation very conservative.

After removal of the decay and completion of the proximal and occlusal cavity form, the operative area is isolated with a rubber dam in preparation for the restorative process. Figure 2 clearly shows that the proximal gingival tissue was abraded during cavity preparation and there is evidence of hemorrhage.

It is not advisable to try and “wash” the hemorrhage away with water and quickly apply the matrix band.

Even if this is successful, it is

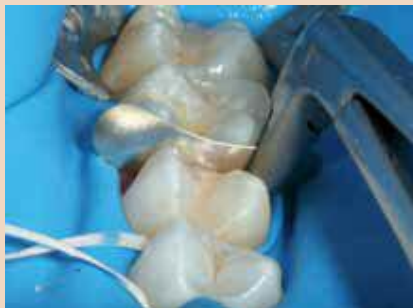

Fig. 5: A sectional matrix band gripped by Composit-Tight Matrix Forceps, an instrument that enables precise placement of sectional matrix bands without deformation.

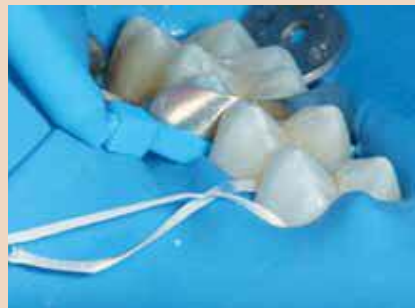

Fig. 6: The WedgeWand during clinical application with the wedge bent at a 90-degree angle to the handle.

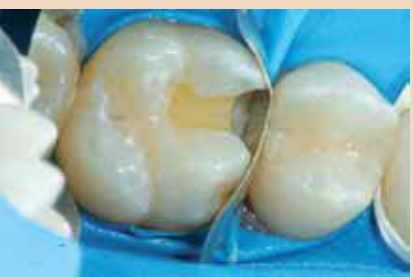

Fig. 6a: WedgeWands provide an excellent seal.

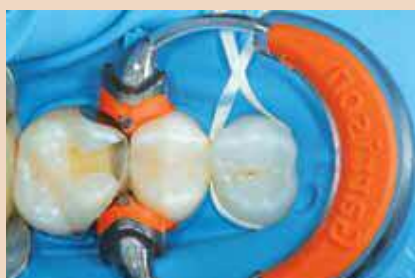
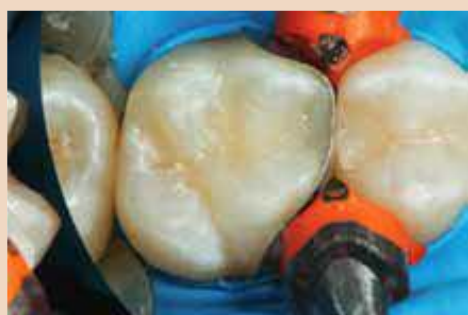
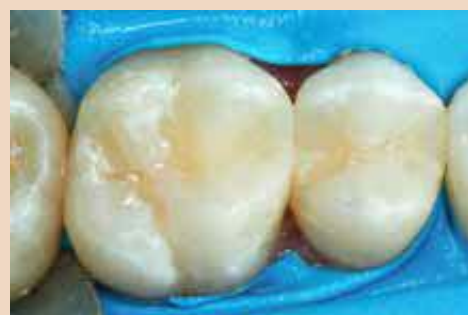Fig. 7: The Soft Face 3D-Ring in place. Note the precision of the cavo-surface and marginal seal by the sectional matrix.

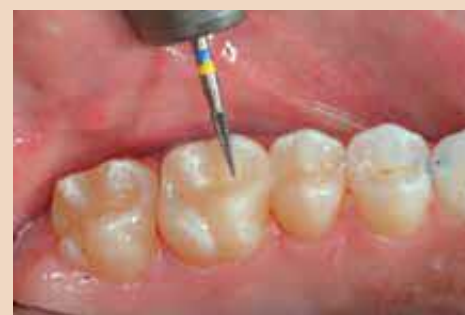



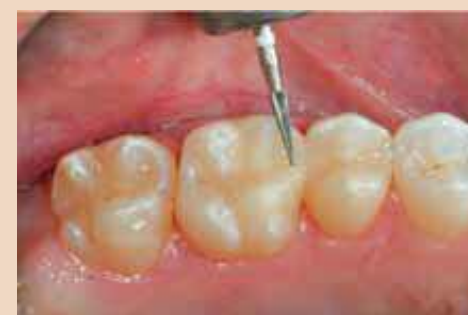*Fig. 8: The composite restoration is completed prior to removal of the matrix band. Placement of the matrix precisely reconstructs the proximal tooth form.*



*Fig. 8a: The restoration immediately after matrix removal.*



*Fig. 9: The pointed Q-Finisher carbide finishing bur is used to make minor occlusal adjustments and refine the restorative margins.*



*Fig. 10: The ultra-fine pointed composite finishing bur is used to further refine and finish the restoration's adjusted areas.*

likely that blood will infiltrate into the preparation in the gingival area and make etching and placement of the dentin bonding adhesive without contamination impossible.

An excellent way to manage the proximal tissue hemorrhage quickly and completely is to apply Expa-syl (Ker) to the area, tap it to place with a dry cotton pellet, and wait one to two minutes (Fig. 3).

Using an air-water mixture, rinse away the Expa-syl leaving a little bit of the material on top of the tissue, but below the gingival margin of the preparation (Fig. 4).

The Expa-syl will deflect the tissue away from the preparation margin, maintain control of any hemorrhage and facilitate placement of the proximal matrix without the risk of contamination of the operative field.

Class II preparations that need a matrix band for restoration will require rebuilding of the marginal ridge, proximal contact and often a large portion of the interproximal surface.

The goal of composite placement is to do so in such a way that the amount of rotary instrumentation for contouring and finishing is limited. This is especially true for the interproximal surface.

Because of the constraints of clinical access to the proximal area, it is extremely difficult to sculpt and correctly contour this surface of the restoration. Proper reconstitution of this surface is largely due to the shape of the matrix band and the accuracy of its placement.

After removal of caries and old restorative material, the outline form of the cavity preparation is assessed. If any portion of the proximal contact remains, it does not necessarily need to be removed. Conserve as much healthy, unaffected tooth structure as possible.

If the matrix band cannot be easily positioned through the remaining contact, the contact can be lightened using a Fine Diamond Strip (DS25F, Komet USA). The Composi-Tight 3D™ Matrix System was chosen to aid in the anatomic restoration of the mesial proximal tooth morphology of this maxillary first molar.

The appropriate matrix band chosen is one that will best correspond anatomically to the tooth being restored, and also to the width and height of the proximal surface.

The height of the sectional matrix should be no higher than the adjacent marginal ridge when properly

placed. Because of the concave anatomic shape, the proximal contact will be located approximately one millimeter apical to the height of the marginal ridge.

The Composi-Tight Matrix Forceps are used to place the selected sectional matrix band in the correct orientation in the proximal area.

The positive grip of this instrument will allow for more exact placement than a cotton plier, which could damage or crimp the matrix band.

The sectional matrix band (Garrison Dental Solutions) is positioned and placed using the Composi-Tight Matrix Forceps to the mesial proximal area of tooth No. 14 (Fig. 5).

The orientation of the band and the positive fit make precise placement possible, even in posterior areas with tight access.

Next, the gingival portion of the band is stabilized and sealed against the cavosurface margin of the preparation using the appropriate size.

#### WedgeWand flexible wedge (Fig. 6)

The size of the WedgeWand® flexible wedge should be wide enough to hold the gingival portion of the matrix band sealed against the cavosurface of the preparation, while the opposite side of the wedge sits firmly against the adjacent tooth surface.

To place the wedge, the Wedge Wand is bent to 90 degrees where the wedge meets the handle.

The flexible wedge can now be placed with pressure conveniently, without the use of cotton forceps, that often can be very clumsy. Once the wedge is in the correct orientation, a twist of the wand releases the wedge.

The G-Ring® forceps are then used to place the Soft Face™ 3D Ring into position. The feet of the Soft Face 3D Ring are placed on either side of the flexible wedge and the ring is released from the forceps.

The force of the 3D Ring causes a slight separation of the teeth due to periodontal ligament compression. The unique pads of the Soft Face 3D ring hug the proximal morphology of the buccal and lingual surfaces of the adjacent teeth, while at the same time creating an unbelievably precise adaptation of the sectional matrix to the tooth cavosurface margins (Fig. 7).

Once the sectional matrix is properly wedged and the Soft Face 3D Ring is in place, the restorative process can be started.

A 15-second total-etch technique, 10 seconds on enamel margins and five seconds on dentin surfaces, is performed using a 37 percent phosphoric etch.

The etchant is then rinsed off for a minimum of 15 to 20 seconds to ensure complete removal. The preparation is then air-dried and treated with AcQuaSeal desensitizer (AcQuaMed Technologies) to disinfect the cavity surface, create a moist surface for bonding and begin initial penetration of HEMA into the dentinal tubules.

A fifth generation bonding agent (Optibond Solo Plus, Kerr) is then placed on all cavity surfaces. The solvent is evaporated by spraying a gentle stream of air across the surface of the preparation. The adhesive is then light cured for 20 seconds.

The first layer of composite is placed using a flowable composite (Revolution 2, Kerr) to a thickness of about 0.5 mm.

The flowable composite will "flow" into all the irregular areas of the preparation and create an oxygen-inhibited layer to bond subsequent layers of microhybrid material.

After light curing for 20 seconds, the next step is to layer in the microhybrid material.

First, using a unidose delivery, the first increment of microhybrid composite (Premise, Kerr) is placed into the proximal box of the preparation.

A smooth-ended condensing instrument is used to adapt the restorative material to the inside of the sectional matrix and preparation.

This first increment should be no more than 2 mm thick. After light curing the first increment, the next increment should extend to the apical portion of the interproximal contact and extend across the pulpal floor.

Facial and lingual increments are placed and sculpted using a Gold-

stein Flexithin Mini 4 (Hu-Friedy).

A #2 Keystone brush (Patterson Dental) is lightly dipped in resin and used to feather the material toward the margins and smooth the surface of the composite.

Figure 8 shows the restoration after completion of the enamel layer prior to matrix band removal.

The Composi-Tight Matrix Forceps were used to remove the sectional matrix after removal of the flexible wedge and Soft Face 3D Ring.

The Composi-Tight™ 3D Ring reduces flash to a minimum. Finishing and polishing were accomplished using Q-Finisher Carbide Finishing Burs (Komet USA).

Typically, three grits and, correspondingly, three different burs are used to finish composite materials. With the Q-Finisher system, the blue-yellow striped bur with its unique blade configuration does the work of two burs with one.

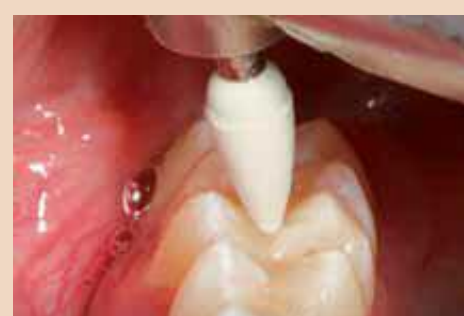An excellent surface quality on composite and natural tooth is achieved due to the cross-cut design of the cutting instrument.

The small, pointed (H134Q-014) Q-Finisher was used to make minor occlusal adjustments on the restorative surface as needed and to smooth and refine the marginal areas of the restorative material where accessible (Fig. 9).

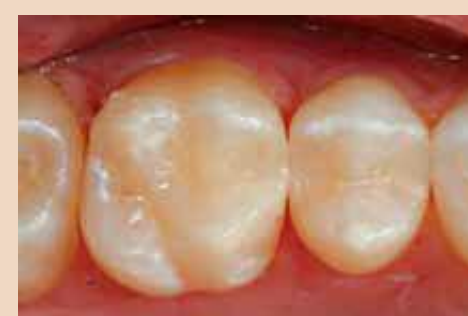The fine, white stripe ultra-fine finishing bur (H134UF-014) was used in the adjusted areas for precise fine finishing (Fig. 10). Komet Diamond Composite polishing points (green, polishing; and gray, high shine) were then used to polish and refine the restorative surface (Fig. 11).

Once polishing is complete, the final step is to place a surface sealant (Seal and Shine, Pulpdent) to seal and protect any microscopic imperfections at the restorative marginal interface that may be left as a result of our inability to access these areas on the micron level.

→ DT page 8



*Fig. 11: A fine-pointed diamond composite polisher smooths adjusted areas during polishing.*



*Fig. 12: An occlusal view of the direct MO composite restoration after application of Seal-n-Shine sealant.*



← DT Page 7

Remember, an explorer can “feel” a 30-micron marginal gap at best. Bacteria are 1 micron in diameter. The purpose of the Seal and Shine is to fill these areas. Figure 12 shows an occlusal view of the completed Class II composite restoration.

### Conclusion

A technique has been described:

1) to control proximal tissue bleeding prior to matrix placement with Expa-syl (Kerr),

2) utilize a sectional matrix system (Composi-Tight 3-D, Wedge-Wand, Garrison Dental Solutions) and a nanofilled microhybrid composite (Premise, Kerr) to create an anatomically precise proximal surface, and

3) use the Q-Finisher, two-bur composite finishing system (Komet USA) to finish then polish with diamond composite abrasives (Komet USA), refining marginal integrity without destroying occlusal anatomic form.

The interproximal surface has been re-created with natural anatomic contour and has a predictable, elliptical contact with the adjacent tooth.

With proper occlusal and proximal form, this “invisible” direct composite restoration will service the patient for many years to come. **DT**

## MEDIA CME Self-Instruction Program

Dental Tribune Middle East & Africa in collaboration with CAPP introduce to the market the new project mCME - Self Instruction Program. mCME gives you the opportunity to have a quick and easy way to meet your continuing education needs.

mCME offers you the flexibility to work at your own pace through the material from any location at any time. The content is international, drawn from the upper echelon of dental medicine, but also presents a regional outlook in terms of perspective and subject matter.

#### How can professionals enroll?

They can either sign up for a one-year (10 exercises) by subscription for the magazine for one year (\$65) or pay (\$20) per article. After the payment, participants will receive their membership number and will be able to attend to the program.

#### How to earn CME credits?

Once the reader attends the distance-learning program, he/she can earn credits in three easy steps:

1. Read the articles.
2. Take the exercises
3. Fill in the Questionnaire and Submit the answers by Fax (+971 4 3686883) or

#### Email: info@cappmea.com

After submission of the answers, (name and membership number must be included for processing) they will receive the Certificate with unique ID Number within 48 to 72 hours. Articles and Questionnaires will be available in the website after the publication. [www.cappmea.com](http://www.cappmea.com)

# Three essential lessons for every new dentist

By Sally McKenzie, CEO

After years of schooling, thousands of dollars in tuition, hours upon hours of clinics and exams, and tests and on and on, finally you entered the working world as a dentist. Just you and the patients.

Wouldn't it be great if it could really be that simple?

It's likely that it didn't take you long to realize that once your tour in dental school was over, the learning process had only just begun.

Moreover, there are at least three key lessons that were probably barely touched upon in the dental school curriculum.

### Lesson No. 1: How to deal with people

I'm not talking about the patients. You've been trained to manage them. I'm talking about the people you see every day, the ones you work with elbow to elbow, those you depend on to represent you, to make sure you have enough money to pay your bills, to keep your schedule on track, etc.

Obviously, I'm talking about your team. Your success as a dentist is directly dependent upon your employees' success. Unfortunately, one bad hiring decision can cost you a small fortune — estimates range between 1.5 to 5 times annual compensation — it can also damage patient relations, staff morale and overall effectiveness of the practice.

Given what's at stake, pay close attention to Lesson No. 1: Do your best to hire the best and never hire under pressure. Follow these steps and take a clear and measured approach to ensure that every employee you hire is the best fit for your growing practice.

*Assess the systems before you bring in a new employee.* If you're hiring an office manager, look at business operations first. Are the business systems, scheduling, collections, recall, etc., working efficiently? If not, this is your chance to fix them, to integrate new protocols and establish up front how you want these handled in your practice.

*Take 15 minutes.* Set aside 15 minutes to think about what you want the person in this position to do. Make a list. Consider what you are looking for in this individual.

*Write a job description.* Once you've given some thought to the position, update or write a job description for the job tailored to attract the employee you need. Include the job title, job summary and specific duties. This clarifies what skills the applicant must possess and explains what duties she/he would perform.

Cast a wide net. Develop an ad and place it on multiple websites and in different publications. Promote those aspects of the job that will have the greatest appeal, including money. Sell the position.

Keep the copy simple but answer the reader's questions — job title, job scope, duties, responsibilities, benefits, application procedures, financial incentives and location. Direct prospects to your website to learn more about your practice and the position.

*Read the resumes; don't just scan them.* Highlight those qualities that match the position's requirements. Look for longevity in employment. Be careful of those applicants that only note years, such as 2008–2009. Chances are this person was hired in December of '08 and fired in January of 2009.

Watch for sloppy cover letters. The applicant may have poor attention to detail. Flag resumes with “yes,” “no,” or “maybe.” The “yes” candidates are the first to be considered.

*Pre-screen applicants on the phone.* Address your most pressing concerns up front. If there are gaps in employment history, now is the time to find out why. Ask the applicant what salary range she/he is expecting. Listen for tone, attitude and grammar on the phone, particularly if the position requires handling patient calls. Based on the applicant's phone demeanor, would this person represent your practice well?

*Prepare for the interviews.* Conduct interviews using a written set of standard questions for each applicant so you are able to compare responses to the same questions.

Avoid asking any personal questions. Ask follow-up questions

based on the applicant's responses. Jot down personal details to keep track of who's who. The candidate is likely to be on her/his best behavior in the interview. If the applicant doesn't impress you now, it will not get better after she/he is hired.

*Test for the best.* Take advantage of Internet testing tools that are available to dentists. Such testing has been used in the business sector for years to help companies identify the better candidates for specific positions.

*Check 'em out.* Once the interview and testing process has enabled you to narrow the selection down to a couple of candidates, check their references and work histories. This step can yield tremendously helpful information and will save you from multiple hiring horrors.

*Budget for training.* Give your new employee the tools and the knowledge to achieve her/his best, and you'll both benefit significantly.


Above all else, when it comes to staff hiring, make your decisions based on real data, not a candidate's sunny disposition or your “gut feelings.”

### Lesson No. 2: Lead your team to excellence

If you're frustrated by what you perceive as average or below average team performance, determine if you've given them the foundation to achieve the standards you expect.

First, avoid the most common pitfall in leading employees: Assuming that your staff knows what you want. Don't assume.

Spell out your expectations and the employees' responsibilities in black and white, and do so for every member of your team


**European Medical**  
 Equipment Distribution - Middle East

**Dentistry of the 21st Century**  
 Come and Join Us

October 15th 2010 at Movenpick Hotel Bur Dubai  
 Four International speakers, Four different topics  
**6 CME Credit hours**

Email: [info@euro-med-me.com](mailto:info@euro-med-me.com)  
 Contact number: 050 674 2359  
 for more information visit [www.euro-med-me.com](http://www.euro-med-me.com)



## ‘Give ongoing direction, guidance and feedback to your team so they know where they stand.’

from the beginning. Do not convince yourself that because they’ve worked in this dental practice for X number of years, they know how you want things done.

They don’t, and they will simply keep performing their responsibilities according to what they think you want unless they are directed otherwise.

Recognize the strengths and weaknesses among your team members. All employees bring both to their positions. The fact is that some people are much better suited for certain responsibilities and not others. Just because “Rebecca” has been handling insurance and collections for the practice doesn’t mean she’s effective in those areas. Look at results.

Rebecca may be much more successful at scheduling and recall and would be a much more valuable employee if she were assigned those duties. Don’t be afraid to restructure responsibilities to make the most of team strengths. In addition, be open to maximizing those strengths through professional training.

Give ongoing direction, guidance and feedback to your team so that they know where they stand.

Don’t be stingy. Give praise often and appraise performance regularly. Verbal feedback can be given at any time, but it is most effective at the very moment the employee is engaging in the behavior that you either want to praise or correct.

Nip problems in the bud and you’ll avoid numerous thorns in your side. If an employee is not fulfilling her/his responsibilities, address the issue privately and directly with her/him. Be prepared to discuss the key points of the problem as you see it as well as possible resolutions.

Use performance reviews to motivate and encourage your team to thrive in their positions. Base your performance measurements on individual jobs. Focus on specific job-related goals and how those relate to improving the total practice.

Used effectively, employee performance measurements and reviews offer critical information that is essential in your efforts to

make major decisions regarding patients, financial concerns, management systems, productivity and staff in your new practice.

### Lesson No. 3: Keep your hands in the business

Certainly, it doesn’t take long to recognize that there are many hats for the dentist to wear. The hat that says “The CEO” is just as important as the hat that says “The Dentist.” It is critical that you completely understand the business side of your practice.

There are 22 practice systems and you should be well-versed in each of them. If not, seek out training for new dentists. The effectiveness of the practice systems will directly, and profoundly, affect your own success today and throughout your entire career.

For starters, routinely monitor practice overhead. It should breakdown according to the following benchmarks to ensure that it is within the industry standard of 55 percent of collections:

- Dental supplies: 5 percent
- Office supplies: 2 percent
- Rent: 5 percent
- Laboratory: 10 percent
- Payroll: 20 percent
- Payroll taxes and benefits: 3 percent
- Miscellaneous: 10 percent

Keep a particularly close eye on staff salaries. Payroll should be between 20 and 22 percent of gross income. Tack on an additional 3 to 5 percent for payroll taxes and benefits. If your payroll costs are higher than that, they are hammering your profits. Here’s what may be happening:

- You have too many employees.
- You are giving raises based on longevity rather than productivity/performance.
- The hygiene department is not meeting the industry standard for production, which is 33 percent of total practice production.
- The recall system, if there is one, is not structured to ensure that the hygiene schedule is full and appointments are kept.

*Maximizing productivity.* Hand-in-hand with practice overhead is production, and one area that directly affects your production is your schedule. Oftentimes, new dentists simply want to be busy, but it’s more important to be productive. Follow these steps to maximize productivity.

First, establish a goal. Let’s say yours is to break \$700,000 in clinical production. This calculates to \$14,583 per week, not including four weeks for vacation. Working 40 hours per week means you’ll need to produce about \$364 per hour. If you want to work fewer

hours, obviously per-hour production will need to be higher.

A crown charged out at \$900, which takes two appointments for a total of two hours, exceeds the per hour production goal by \$86. This excess can be applied to any shortfall caused by smaller ticket procedures. Use the steps below to determine the rate of hourly production in your practice.

The assistant logs the amount of time it takes to perform specific procedures. If the procedure takes the dentist three appointments, she should record the time needed for all three appointments.

Record the total fee for the procedure.

Determine the procedure value per hourly goal. To do this, take the cost of the procedure (for example, \$900) divide it by the total time to perform the procedure ( $\$900 \div 120$  minutes). That will give you your production per minute value ( $= \$7.50$ ). Multiply that by 60 minutes ( $\$7.50 \times 60 = \$450$ ).

Compare that amount to the dentist’s hourly production goal. It must equal or exceed the identified goal.

Now you can identify tasks that can be delegated and opportunities for training that will maximize the assistant’s functions. You also should be able to see more clearly how set up and tasks can be made more efficient.

A career in dentistry is one of the most personally and professionally fulfilling fields you can choose. With the right team, clear leadership and effective business systems, you can enjoy tremendous personal success and lifelong financial security for you and your family. [DT](#)

### About the author



Sally McKenzie is CEO of McKenzie Management, which provides success-proven management solutions to dental practitioners nationwide. She is also editor of The Dentist’s Network Newsletter at [www.thedentistsnetwork.net](http://www.thedentistsnetwork.net); the e-Management Newsletter from [www.mckenziemgmt.com](http://www.mckenziemgmt.com); and The New Dentist™ magazine, [www.thenewdentist.net](http://www.thenewdentist.net). She can be reached at (877) 777-6151 or [sallymck@mckenziemgmt.com](mailto:sallymck@mckenziemgmt.com).

AD