

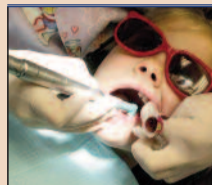DENTAL TRIBUNE

— The World's Dental Newspaper · Middle East & Africa Edition —

PUBLISHED IN DUBAI

June-August 2011

No. 6+7+8 Vol. 9



News & Opinions
64% Abu Dhabi students suffer dental decay

Page 2



Media CME
Two-stage esthetic crown lengthening

Page 6



Dental Cafe
Lollipops May Reduce Tooth Decay

Page 11

Mediterranean diet lengthens life'



People who follow a Mediterranean diet combined with exercise, not smoking and keeping to a healthy weight could live up to 15 years longer, researchers have said.

The effect is strongest in women, who can live an extra 15 years compared to the least

healthy people, while healthy men can enjoy eight years more.

Researchers from Maastricht University in the Netherlands said keeping to the four healthy lifestyle factors can "substantially reduce" the risk of an early death.

Writing in the American Journal of Clinical Nutrition, researchers looked at 120,000 men and women who were aged 55 to 69 in 1986.

They calculated a "healthy lifestyle score" based on smoking, exercise, weight and diet and followed the group until 1996.

A Mediterranean diet is high in vegetables, olive oil, fruit, nuts, fish and whole grains, and low in meat and alcohol.

Researchers found that combining the diet with exercise, keeping to a healthy weight and not smoking dramatically cut the risk of dying young.

Piet van den Brandt, professor of epidemiology at Maastricht University, who worked on the study, said: "Very few research studies worldwide have analysed the relationship between a combination of lifestyle factors and mortality in this way. This study shows that a healthy lifestyle can lead to significant health benefits.

"Furthermore, the effects of a Mediterranean diet were more evident in women than in men. Within this diet, nuts, vegetables and alcohol intake had the biggest impact on lower mortality rates."

5TH INTERNATIONAL CONGRESS IN IMPLANTOLOGY & ESTHETIC DENTISTRY

THE CUTTING EDGE OF CLINICAL DENTISTRY

LECTURES

SWITZERLAND
PASCAL MAGNE
MICHEL MAGNE
DIDIER DIETSCHI
UELI GRUNDER
MARKUS HURZELER

USA
SASCHA JOVANOVIC

GREECE
PANOS BAZOS

CHAIRMEN:
PANOS BAZOS, GREECE
STAVROS PELEKANOS, GREECE

SEPTEMBER 23-24 2011 ATHENS, GREECE

ATHENAEUM INTERCONTINENTAL HOTEL & CONVENTIONAL CENTER
103 - 105, SYNGROU AVENUE, ATHENS

Conference Fee (lectures only):
183 EUR until June 30, 2011
240 EUR until Sept 5, 2011
300 EUR from Sept 6, 2011 until upon registration

ORGANIZED BY



MEDIA PARTNERS



SPONSORS



More information & registration:
Tel: +30 210 222 2637 +30 210 213 2084 omnipress@omnipress.gr web: www.omnicongresses.gr www.omnipress.gr

PROMEDICA

Highest quality made in Germany

- ▶ high quality glass ionomer cements
- ▶ first class composites
- ▶ innovative compomers
- ▶ modern bonding systems
- ▶ materials for long-term prophylaxis
- ▶ temporary solutions
- ▶ bleaching products...

All our products convince by

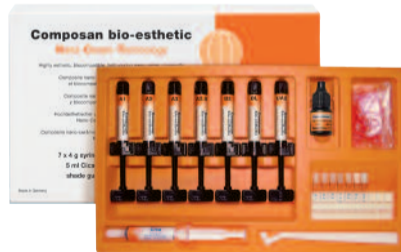- ▶ excellent physical properties
- ▶ perfect aesthetic results

Meet us at several exhibitions - www.promedica.de



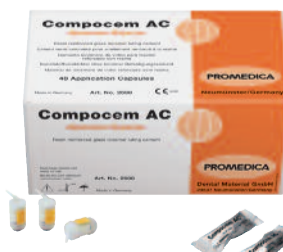Temporary crown and bridge material

- particular fracture and wear resistance
- available in several attractive shades



Light-curing nano-ceram composite

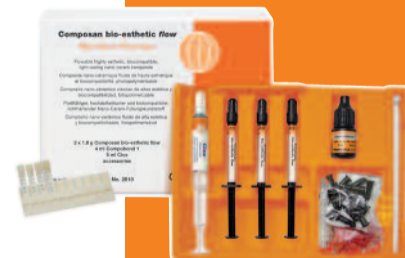- universal for all cavity classes
- comfortable handling, easy modellation
- highly esthetic and biocompatible



Resin-reinforced glass ionomer luting cement

- strong adhesion, very low film thickness
- especially suited for zirconia-based pieces

Nano-Ceram-Technology



• exact match of translucency and shade to the packable Composan bio-esthetic

PROMEDICA

PROMEDICA Dental Material GmbH

Tel. + 49 43 21 / 5 41 73 · Fax + 49 43 21 / 5 19 08

Internet: <http://www.promedica.de> · eMail: info@promedica.de

Editorial Board

Prof. Abdullah Al-Shammery, Restorative Dentistry, KSA
 Prof. Hussain F. Al Huwaizi, Endodontics, Iraq
 Prof. Samar Burgan, Oral Medicine, Jordan
 Dr. Abdel Salam Al Askary, Implantology, Egypt

Dr. Talal Al-Harbi, Orthodontist, Qatar
 Dr. Mohammed H. Al Jishi, Bahrain
 Dr. Lara Bakaeen, Prosthodontist, Jordan
 Dr. Aisha Sultan, Periodontist, UAE
 Dr. Kamal Balaghi Mobin Aesthetics, Iran

DENTAL TRIBUNE

The World's Dental Newspaper - Middle East & Africa Edition

Published by Education Zone

in licence of Dental Tribune International GmbH

© 2011, Dental Tribune International GmbH. All rights reserved.

Dental Tribune makes every effort to report clinical information and manufacturer's product news accurately, but cannot assume responsibility for the validity of product claims, or for typographical errors. The publishers also do not assume responsibility for product names or claims, or statements made by advertisers. Opinions expressed by authors are their own and may not reflect those of Dental Tribune International.

President/CEO Yasir Allawi
 y.allawi@dental-tribune.ae

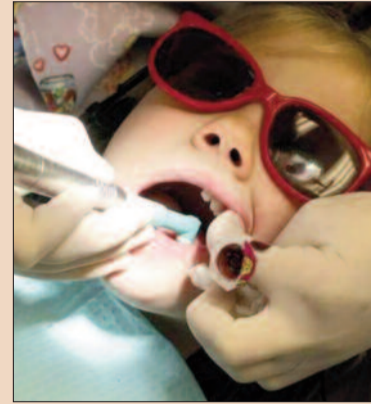
Director mCME: Dr. D. Mollova
 info@cappmea.com

Marketing manager Khawla Najib
 khawla@dental-tribune.ae

Production manager Hussain Alvi
 dentalme@dental-tribune.ae

PO Box 214592, Dubai, UAE, Tel + 971 4 591 0257
 Fax + 971 4 566 4512 www.dental-tribune.com

64% Abu Dhabi students suffer dental decay: Study



ABU DHABI: Dental decay is a problem that 16,505 of the 25,778 (64 per cent) capital students suffer from, a recent survey has revealed.

The Ambulatory Healthcare Services (AHS) - SEHA, in cooperation with the Abu Dhabi Education Council (ADEC), carried out a campaign in public schools in Abu Dhabi, testing students from grade 1, grade 5, and grade nine.

The comprehensive preventive examination for students included a clinical exam tests for BMI, CBC, vision, hearing, scoliosis and dental/oral health.

Discussing key oral hygiene aspects, Dr N Serah George pointed out, "You would be surprised to know that in some families the toothbrush is shared among the family members. This should be a complete no-no."

"Once in every three months people should also change their toothbrush. However, in case the person has suffered from a fever, it should be changed right after they get better and have completed the medication course."

According to her, adults should change their toothbrush every three to four months while children may need to get new toothbrushes more frequently.

"The toothbrush should be replaced when the bristles show signs of wear. It is important to change it often because it holds within its bristles food particles which were once in your teeth," she added.

Dr George noted that children should be taught at a young age the importance of brushing their teeth after meals. "Oral hygiene remains a significant health challenge, which needs to be taken seriously by both care providers and patients."

"Brushing twice per day remains a challenge. Inadequate time spent on brushing and lack of knowledge on the appropriate brushing and flossing process further results in failure to reach remote areas around the posterior teeth."

After the health exams have been carried out, plans are being developed to include students from all levels in both public and private schools in the campaign, based

The campaign has been a success and plans are currently being developed to on the criteria determined by the Health Authority - Abu Dhabi.

A study has also been carried out to introduce the electronic health files in public school clinics, tying the school clinics to the Seha network. This step will provide the school nurse with access to the latest updates regarding the student's medical issues, tests, and results. [\[1\]](#)

كلية نيقولا وآسب الجامعية

NICOLAS & ASP UNIVERSITY COLLEGE

Dubai - Abu Dhabi

First Postgraduate Dental Institution in UAE

Register NOW...

MASTER DEGREE IN ORTHODONTICS & MALMO UNIVERSITY SPECIALIST DEGREE
 Full And Part Time

SPECIALITY CERTIFICATE IN ORTHODONTICS
 Full And Part Time

MASTER DEGREE IN ENDODONTICS
 Swedish Recognition In Progress
 Full And Part Time

SPECIALITY CERTIFICATE IN ENDODONTICS
 Full And Part Time

MASTER DEGREE IN PEDIATRIC DENTISTRY
 Swedish Recognition In Progress
 Full And Part Time

SPECIALITY CERTIFICATE IN PEDIATRIC DENTISTRY
 Full And Part Time

DIPLOMA IN ADVANCED EDUCATION IN GENERAL DENTISTRY
 Fulfill Experience Requirements
 Full Time

HIGH DIPLOMA IN ORAL IMPLANTOLOGY
 Modular Option Available
 Full And Part Time



All Programs Accredited by
 UAE Ministry of Higher Education & Scientific Research

Abu Dhabi Headquarters

Admission Office:
 Al Nadi Al Seyahl
 Sheikh Omar Bin Zayed Al Nahyan

Dubai Branch

Dubai Healthcare City
 Ibn Sina Building (No. 27)
 Block D, 3rd floor, Office 302
 Telephone: +971 4 3624787

Fax: +971 4 362 4793

P.O. Box: 53382, Dubai, UAE

Website: www.dubai-postgraduate.com

Email: info@dubai-postgraduate.com

AD

Dentists warn of worrying trend for unnecessary cosmetic procedures in the Middle East

Abu Dhabi, UAE: With weekly TV programmes in the Middle East showing dentists giving people the pearly-whites of their dreams, and newspapers touting the latest procedure to give you a 'new smile in an hour', the attraction of a quick-fix cosmetic smile makeover such as dental veneers, rather than prolonged improvement through natural alignment, can seem a very attractive option for many busy professionals. But, as Dr Raj Kumar, founder of Forma and speaker at Dentistry Middle East 2011 explains, the worrying trend for unnecessary cosmetic dental veneers, carried out on healthy teeth for the sake of a smile makeover, can do more harm than good.

"Traditionally veneers have represented one of the best cosmetic dentistry options for people wanting whiter teeth or who want to camouflage spaces between 'gappy' or overcrowded teeth," says Dr Kumar. "However, having veneers on your teeth is a permanent solution and the veneers will need to be replaced after a period of time.

"Some dentists routinely remove at least 1.5 mm of the outer enamel to create space for veneers. This can lead to a number of complications such as pulpitis, tooth fracture, veneer failure due to the loss of the enamel surface, gingivitis or gingival recession. Once you trim down a tooth you reduce its life expectancy. As we only have one set of adult teeth, why should we rush into irreversible treatment?"

Instead, Dr Kumar recommends the patient does their homework before opting for veneers and considers the less-invasive options available in today's market. Treatment such as Invisalign, for example, straighten teeth without the need for metal braces or tooth extraction using instead a series of clear, plastic 'aligners' which slowly move teeth over time using individual virtual 3D treatment.

"While the total treatment time with this less invasive method of achieving a 'Hollywood smile' can take from nine to 15 months, ultimately this treatment is more comfortable and the patient will avoid causing irreplaceable damage to their teeth," explains Dr Kumar. "To recreate that 'Hollywood smile', at the end of the treatment the teeth can be safely whitened if the patient so desires."

Dr Kumar also advises to watch out for unqualified dentists. "It is very difficult to know how good your dentist really is as anyone can print a certificate. Sometimes a good measure is to see if the dentist can spot the patients' cosmetic problem without being shown it. This shows that the dentist has experience and is looking at details when carrying out an examination. The best thing is to be shown before and after cases that the dentist has carried out."

Dr Raj Kumar will be speaking at the 5rd Dentistry Middle East Exhibition and Conference, the Middle East's largest gathering of dental professionals, which will run from 1-3 November, 2011, at the Abu Dhabi National Exhibition Centre (ADNEC), with more than 30 leading experts in the field of

dentistry highlighting the educational significance of the event.

Prof Dr Asmat Lone, Chairman of the Advisory Board for Dentistry Middle East 2011, says: "Cosmetic dentistry is becoming extremely popular in the Middle East as the middle and upper class want their

smiles to look perfect. Missing teeth are also becoming a major problem in the Middle East as people are losing teeth due to decay and trauma. The teeth have to be replaced and implantology is becoming the first choice."



Prof Asmat Lone



Dr Raj Kumar

AD



EMS
ELECTRO MEDICAL SYSTEMS

EMS-SWISSQUALITY.COM

SUBGINGIVAL WITHOUT LIMITS

THE DEEPEST PERIODONTAL POCKETS NOW WITHIN REACH WITH THE ORIGINAL AIR-FLOW METHOD



> Subgingival application of the Original AIR-FLOW® method reduces periodontal pocket depth, removes biofilm, prevents periimplantitis

AIR-FLOW MASTER® is the name of the world's first subgingival prophylaxis unit. With two application systems in one. For sub- and supragingival use with matching handpiece and powder chamber.

Incredibly easy to operate. Uniquely simple to use.

Touch 'n' flow: Highly sensitive 3-touch panel for easy choice of settings.



The inventor of the Original Air-Flow Method is now first to cross the boundaries of conventional prophylaxis.

"I FEEL GOOD"

For more information > welcome@ems-ch.com

AIR-FLOW® KILLS BIOFILM

ems-swissquality.com

International Team for Implantology awards André Schroeder Research Prize

From news report

BASEL, Switzerland: The International Team for Implantology (ITI) has awarded Dr Nikola Saulacic, dentist, oral surgeon and researcher at the University of Bern, Switzerland, with the 16th André Schroeder Research Prize. Mid-June, Prof. Daniel Buser, president of the academic organisation dedicated to the promotion of evidence-based education and research in the field of implant dentistry, presented the prize at the ITI Congress Benelux in Amsterdam in the Netherlands.

Forty-two-year-old Saulacic was selected by the ITI Research Committee through an anonymous evaluation process. The committee honoured the researcher for his experimental study on "Bone apposition to a titanium-zirconium alloy implant surface" which is aimed at determining the early healing events

of titanium-zirconium (TiZr) implants in comparison with titanium implants, both with a modified sandblasted and acid etched (SLActive) surface, and an implant material with additional strength (Ti6Al4V). The study concluded that TiZr implants showed comparably fast early osseointegration than titanium im-



Dr Nikola Saulacic (left) and Prof. Daniel Buser. (DTI/Photo courtesy of ITI, Switzerland)

plants supporting their use for more challenging clinical situa-

tions in which implants with a reduced diameter are indicated.

The André Schroeder Research Prize was established almost 20 years ago and is presented annually in honour of the late Prof. André Schroeder (1918–2004), founding ITI President, who pioneered implant dentistry and whose lifework contributed significantly to modern dentistry. It is worth CHF 20,000 (US\$24,000) in cash. According to the ITI, it is one of the most prestigious awards in implant dentistry. [DTI](#)

US scientists measure dino blood

Daniel Zimmermann
DTI

NEW YORK, USA: New findings using dinosaur teeth could help to explain how the reptiles were able to regulate their body temperature, researchers from the California Institute of Technology in the US have reported. By measuring subatomic particle concentrations in fossil teeth in two of the largest dinosaur species, they claim to have found that the animals' body temperatures were much higher than that of other reptiles and comparable to mammals.

Since the first species was officially classified, anthropologists have quarrelled over whether dinosaurs were cold- or warm-blooded. The latest research suggests that they were warmer than originally expected and probably able to reduce body heat through special physiological features. Scientists, however, were not able to determine the body temperature of the creatures except through indirect methods, such as measuring the spacing of dinosaur tracks.

The new approach developed by geochemist Robert Eagle and geologist Prof. John Eiler is able to determine body temperature to within one or two degrees, the researchers say. It measures the concentration of rare carbon and oxygen particles that clump and form minerals called bioapatites, a process that is dependent on heat. The researchers analysed the clumps in 11 teeth of the *Brachiosaurus brancai* and *Camarasaurus* species found in different locations in the US and Tanzania.

"Nobody has used this approach to look at dinosaur body temperatures before so our study provides a completely different angle on the long-standing debate about dinosaur physiology," Eagle commented. He and Prof. Eiler announced that they would be applying the method to other dinosaurs and extinct animals, including mammals, in order to find out more about how they evolved. [DTI](#)




ultra mini head & super slim body designed for pedo & M.I.

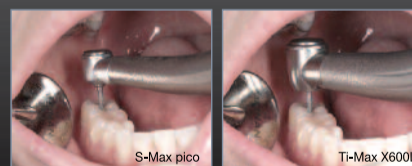new
S-Max pico

S-Max pico Series features ultra-mini head and super-slim body that has been developed specifically for delicate operations with high precision. With its greater visibility and accessibility to hard-to-treat oral areas, pico allows you to work more freely on pedodontics treatment, chamber opening, mirror-technique operation, and buccal and lingual axial reduction in the posterior areas. Pico is now a "must-have" handpiece for every practice and clinic which will be beneficial to both patients and clinicians. Use of NSK's original pico bur (or its equivalent bur) is strictly required.


The smallest head size in the world



The smallest head in dentistry allows for the biggest treatment area

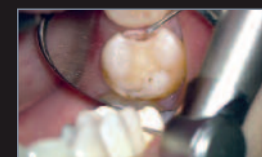
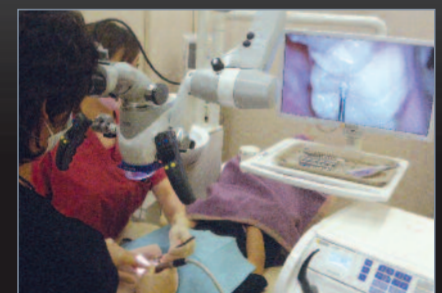

The slimmest neck in the world



Improve the accuracy of operation with the microscope

The ultra mini head delivers expanded operational visibility and greater flexibility. Patient comfort is increased.



In combination with mirror technique

New portable chair could aid dental treatment

Daniel Zimmermann
DTI

NEW YORK, USA: Design and Engineering students from Purdue University in West Lafayette in the US have developed a new kind of portable medical chair that can also be used for dental treatment. The device, named the Mantis owing to its ability to transform into various shapes, does not have any gears or mo-

tors and can be folded into a dolly to suit different medical uses. It is intended to help carry out treatment in underdeveloped countries, where operating traditional surgical equipment can be difficult.

The idea came from Industrial Design student Leha Kenttämää-Squires following several visits to a dental office. In order to realise her concept, she



Inventors Kyle Amick (left) and Leah Kenttämää-Squires demonstrate the Mantis reclining chair they developed. (DTI/Photo courtesy of Purdue University, USA)

teamed up with Mechanical Engineering graduate Kyle Amick, who helped to build the first prototype. According to Kenttämää-Squires, the Mantis is extremely lightweight for carrying by commercial airliners and can store additional medical and dental equipment.

The students are currently seeking to license and commercialise the chair through the Purdue Research Foundations Office of Technology Commercialization, an office that protects and promotes the university's intellectual property. Kenttämää-Squires said that once patented the chair could be available to dental professionals worldwide within two years. [DTI](#)

European doctors use Wikipedia and Co.

From news report

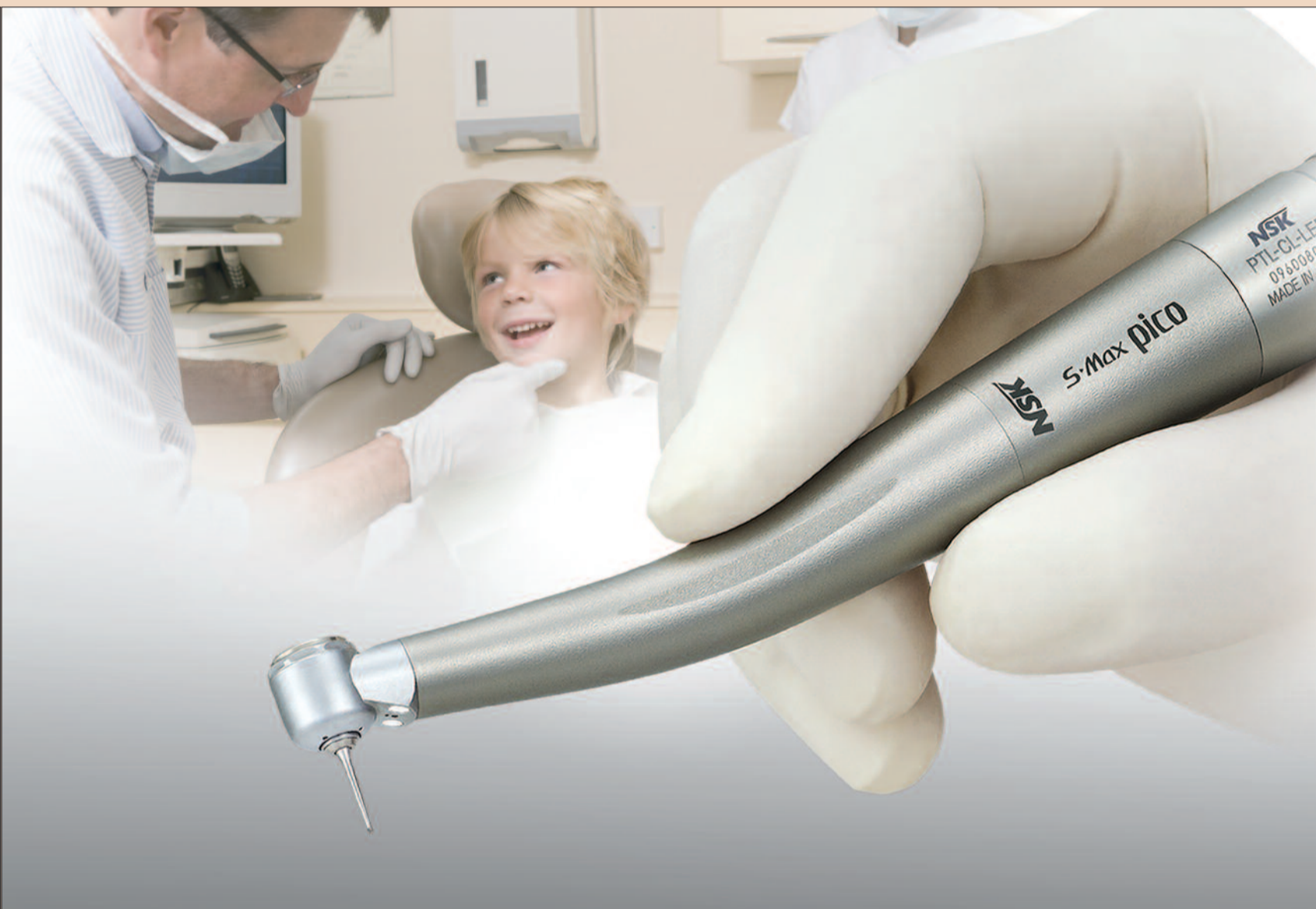LONDON, UK: Sixty per cent of European doctors use the online encyclopaedia Wikipedia for professional purposes, a report has revealed. Furthermore, 69% use social media sites like Facebook, LinkedIn, YouTube and Twitter. For the survey, 300 general practitioners across Europe were interviewed.

The findings show that it is not only young doctors who use the Internet for this purpose. Across all markets, 75% of doctors in the 51 to 60 age groups stated that they regularly consulted Wikipedia for professional use.

According to the London-based Insight Research Group, who carried out the survey, the new statistic surprised many in the industry. Not only did the doctors surveyed use the Internet as a source for their research, but half of them also recommended specific websites for their patients to visit following their consultations. Eighty-seven per cent advised certain sites for further background or education on their condition, 70% for additional support and advice, and 69% for more information regarding treatment and medication.

According to the Insight Research Group, the findings reinforce the popular view that we are now living in the era of the "e-patient", for whom the web has become a trusted tool for health-related matters, as well as daily tasks.

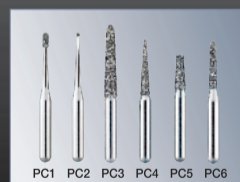
"The e-patient is here to stay. But we have to investigate whether patients are accessing the right type of websites when it comes to health issues they or their loved ones are facing," continued Damian Eade, Director of Insight Research Group. "Whether it's researching illnesses, sharing experiences, making recommendations or providing moral support for other patients around the world, the social web has reinvented health advice." [DTI](#)



Dedicated burs for S-Max pico series

Specifications of each bur

- PC1 for opening the Enamel and removing the Soft dentin
- PC2 for the preparation of small proximal caries
- PC3 for preparation of abutment tooth
- PC4 for the slice cut of proximal surface and feather-edge preparation
- PC5 for the preparation of molar occlusal surface and cavity
- PC6 for finish of the margin preparation



Standard accessory pico bur set PC1-6 (6pcs / pack)



KaVo® and MULTIFLEX® LUX are registered trademarks of Kaltenbach & Voigt GmbH & Co.
Sirona® is a registered trademark of Sirona Dental Systems GmbH.
W&H® is a registered trademark of W&H Dentalwerk Bürmoos GmbH.
Bien-Air® and Unifix® are registered trademarks of Bien-Air Dental S.A.

NSK Middle East www.nsk-inc.com
TEL : +971(0)4-204-5507





Two-stage esthetic crown lengthening

By Michael Sonick, DMD, Stephen Rothenberg, DMD and Debby Hwang, DMD

(mCME articles in Dental Tribune (always page 6) has been approved by HAAD as having educational content acceptable for (Category 1) CME credit hours. Term of approval covers issues published within one year from the distribution date (September, 2010). This (Volume/Issue) has been approved by HAAD for 2 CME credit hours.

A smile that is perceived as unattractive mars confidence, sociability and self-regard. For some patients, the lack of visual appeal stems in large part from a "gummy smile," which a layperson begins to consider disharmonious when there is 3 to 4 mm of gingiva displayed.¹

Management of such a complaint often entails both periodontal and restorative therapy, if not also orthognathic surgery and facial plastic procedures.

The following report showcases two-stage esthetic crown lengthening and prosthetic rehabilitation for the treatment of a gummy smile.

Patient history

A medically and periodontally stable 40-year-old female presented with excessive, asymmetric gingival display of 5 to 7 mm upon smiling, short clinical crowns and incisal wear from tooth #4 to #15 (Figs. 1, 2).

Due to attrition and the relationship between the dentition and periodontal drape, the anterior teeth appear square-shaped and "masculine."

Diagnoses included (1) Coslet Type IA altered passive eruption, evidenced by a wider-than-customary dimension of keratinized gingiva and an alveolar crest at least 1.5 mm apical to the cemento-enamel junction (CEJ); and (2) vertical maxillary excess.^{2,3} The patient also shows a thick tissue biotype.

Treatment plan

- Consult with oral and maxillofacial surgeon regarding orthognathic surgery
- Consult with facial plastic surgeon regarding lip lowering therapy
- Consult with restorative dentist regarding ideal tooth shape set-up and fabrication of surgical guide
- Two-stage esthetic crown lengthening from tooth #4 to #15
- First stage: osseous recontouring
- 6-week healing period
- Second stage: gingivectomy
- 3-month healing period
- Final porcelain veneer restorations for teeth #4 through #15
- Delivery of maxillary occlusal bite guard

Treatment plan rationale

Ideal treatment for the patient with vertical maxillary excess embraces a host of dental and medical specialties.

In such a case as this, in which the patient demonstrates up to 7 mm of gingival display, LeFort I maxillary impaction may further refine results if conventional crown lengthening insufficiently

elevates the periodontal margin, creates an unacceptable crown-to-root ratio or precludes achievement of a natural-seeming emergence profile due to exposure of excessive radicular structure.⁵

Likewise, neuromuscular relaxation of the upper lip by botulinum toxin type A (BTX-A) depresses the lip, and thus masks any mucosal surplus left after periodontal surgery.⁴

As the patient declined orthognathic and facial plastic therapy, the treatment rendered to alleviate her gummy smile and reestablish tissue and dental symmetry included a two-stage crown lengthening procedure followed by delivery of porcelain veneers from tooth #4 to #15.

A biphasic crown lengthening approach minimizes the 1 to 3 mm coronal gingival shifts common after one-stage procedures detected especially in patients with thick soft-tissue biotypes (such as the patient featured in this report).⁵

By first reshaping only the osseous crest and letting healing commence, it is possible to correct any coronal rebound of the soft tissue seen after healing at the second, gingivectomy-only, surgery. Once the attachment apparatus fully remodels post-gingivectomy, which takes roughly three months, final restorations may be cemented.

Restorative consult

From the diagnostic models, the patient's prosthodontist created an ideal dental wax-up, upon which a vacuform matrix was applied to generate a surgical guide (Figs. 3, 4).

osseous recontouring (first stage)

The first stage of biphasic crown lengthening of teeth #4 through #15 involved only os-



Fig. 1a: Initial facial presentation of patient, who exhibits a gummy smile (up to 7 mm of soft-tissue display) and vertical maxillary excess.

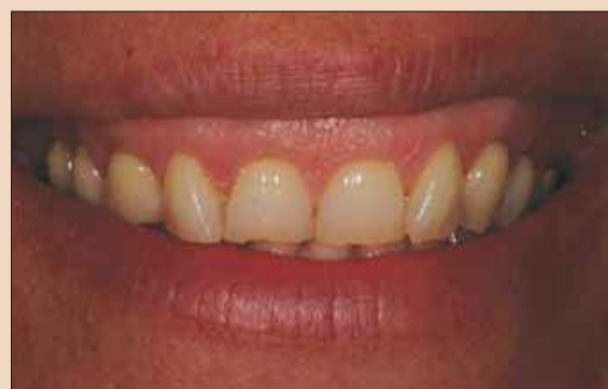

Fig. 2: Excessive keratinized gingiva, a thick soft-tissue biotype and asymmetric gingival contours exist.

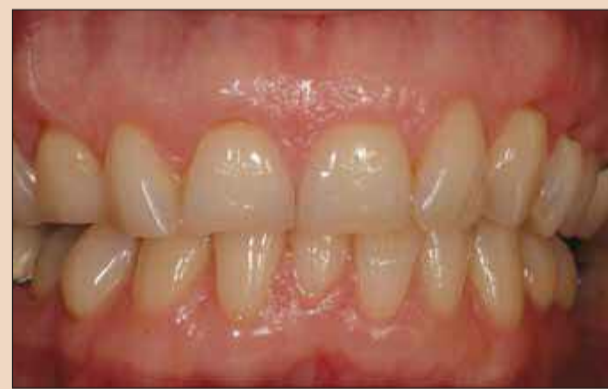

Fig. 3a

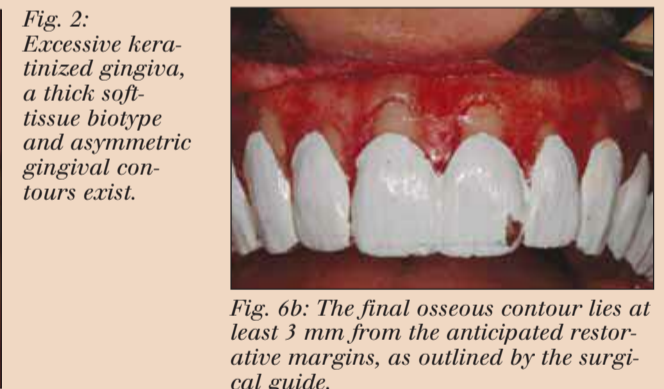
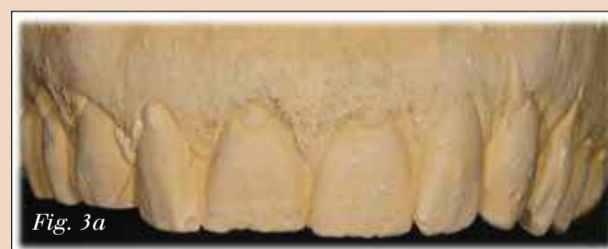

Fig. 3b

Fig. 3a: The maxillary diagnostic model.

Fig. 3b: Ideal wax-up created on the diagnostic model.



Before

After

Fig. 14: Facial view six years post-treatment.

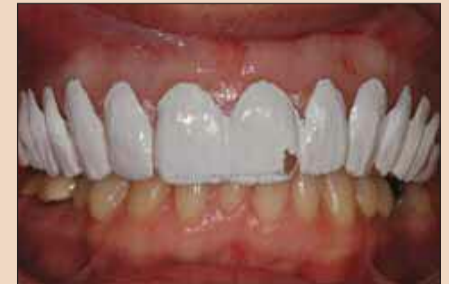

Fig. 4: Surgical guide in place in the mouth. The ideal tooth contours are shaded in white.

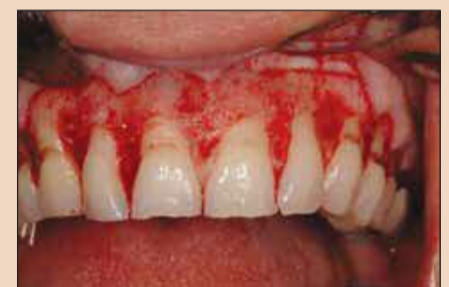

Fig. 5: Initial full-thickness flap reflection at first stage surgery. Note the apical level of the alveolar crest compared to the cemento-enamel junction.

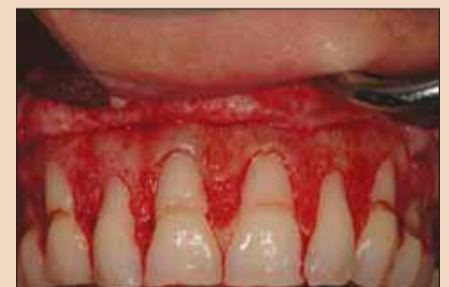

Fig. 6a: Final bone contours after osteotomy.

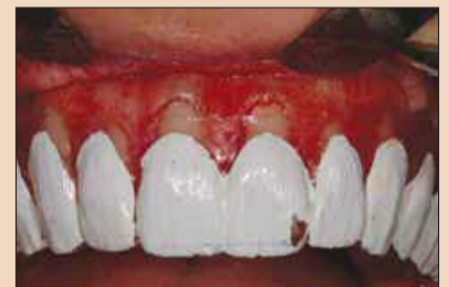

Fig. 6b: The final osseous contour lies at least 3 mm from the anticipated restorative margins, as outlined by the surgical guide.

seous resection. The patient took 0.25 mg oral triazolam and 600 mg ibuprofen one hour before surgery.

Anesthesia with 2 percent lidocaine with 1:100,000 epinephrine and 0.5 percent bupivacaine with 1:200,000 epinephrine was given via local infiltration.

A buccal sulcular incision was made extending from tooth #4 to #15, and vertical incisions were dropped at the mesio-buccal and disto-buccal line angles of teeth #4 and #15. A full-thickness flap was elevated (Fig. 5).

Osteotomy was performed using an Ochsenbein chisel, carbide finishing bur and Neumeyer bur to position the alveolar crest at least 3 mm from the anticipated restorative margin at each site, as verified by the surgical guide (Fig. 6).

The bone was gradualized such that no sharp edges or bulbous areas existed, and positive architecture was preserved. The flaps were replaced and sutured in sling fashion with 4-0 expanded polytetrafluoroethylene (ePTFE) (Fig. 7). The gingival height and shape post-surgery

appeared similar to that found before surgery, even 10 days after intervention (Fig. 8).

Gingivectomy (second stage)

Once the soft tissue resettled six weeks post-osteotomy (Fig. 9), the second stage of biphasic crown lengthening of teeth #4 through #15 was executed. The patient was sedated and anesthetized as above.

A definitive external bevel gingivectomy of teeth

#4 through #15 was performed with a #15 scalpel utiliz-

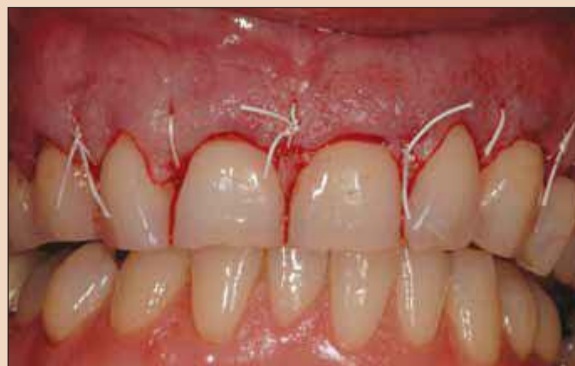

Fig. 7: Sling sutures in place after osseous reshaping. Note the similarity in gingival height and morphology between pre-surgical and post-surgical views.

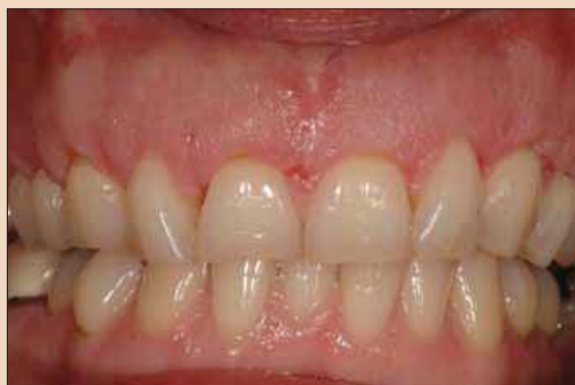

Fig. 8: Healing 10 days after first stage crown lengthening. The periodontal level still approximates the initial presentation.

Fig. 9: Healing six weeks after first stage of crown lengthening.

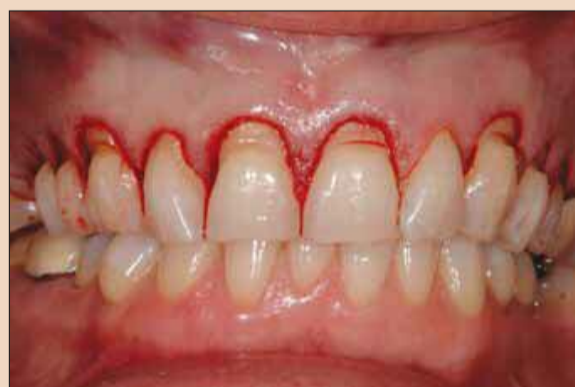
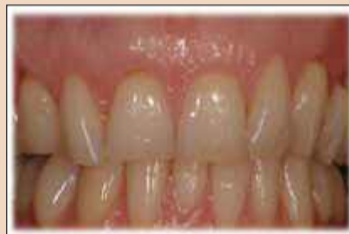
Fig. 10a: Frontal view immediately after second stage gingivectomy.

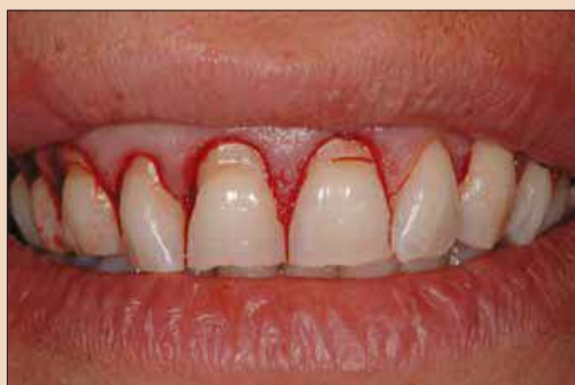

Fig. 10b: Positional relationship between the lip and gingival margin immediately after second stage gingivectomy.

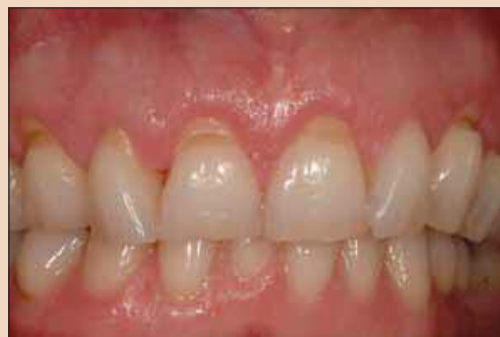

Fig. 11a: Frontal view four weeks after second stage gingivectomy.

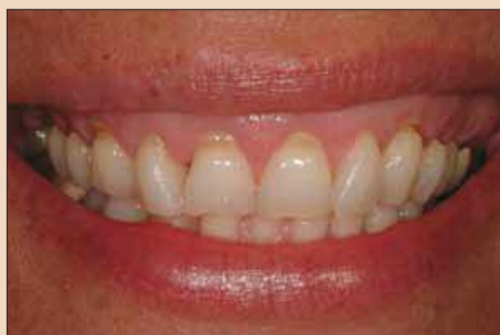

Fig. 11b: Positional relationship between the lip and gingival margin four weeks after second stage gingivectomy.

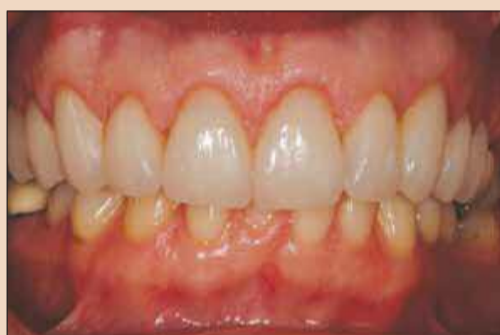

Fig. 12a: Frontal view of final veneers (#4 through #13) three months after gingivectomy.

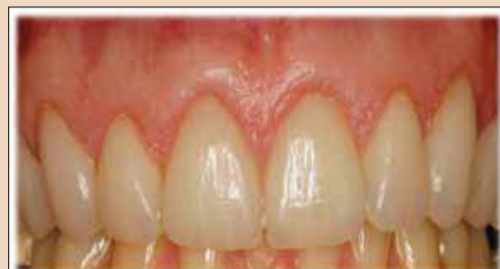

Fig. 12b: Central view of final veneers (#6 through #11) three months after gingivectomy.

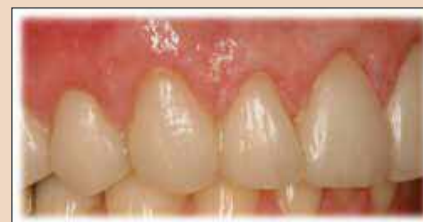

Fig. 12c: Right lateral view of final veneers (#4 through #8) three months after gingivectomy.

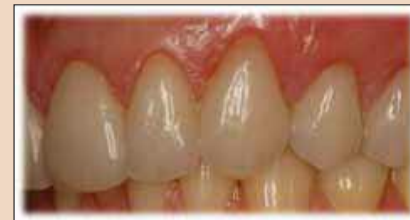

Fig. 12d: Left lateral view of final veneers (#9 through #13) three months after gingivectomy.

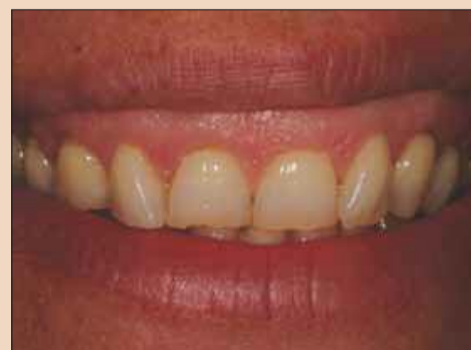

Fig. 13a: Smile pre-treatment.

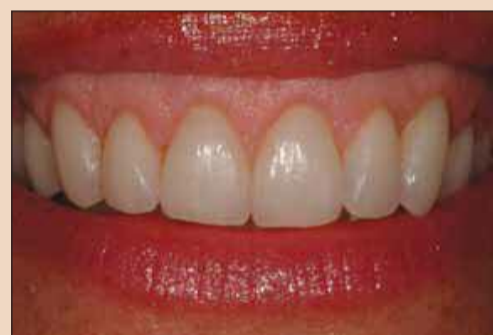

Fig. 13b: Smile six years post-treatment.



Fig. 14: Facial view six years post-treatment.

Before



situations. Am J Orthod Dentofacial Orthop 2006;130(2):141-51.
 2. Coslet JG, Vanarsdall R, Weisgold A. Diagnosis and classification of delayed passive eruption of the dentogingival junction in the adult. Alpha Omegan 1977;70(5):24-8.
 3. Garber DA, Salama MA. The aesthetic smile: diagnosis and treatment. Periodontol 2000 1996;11:18-28.
 4. Polo M. Botulinum toxin type A (Botox) for the neuromuscular correction of excessive gingival display on smiling (gummy smile). Am J Orthod Dentofacial Orthop 2008;135(2):195-203.
 5. Sonick M. Esthetic crown lengthening for maxillary anterior teeth. Compend Contin Educ Dent 1997;18(8):807-12, 14-6, 18-9; quiz 20.

Suture removal occurred at 10 to 14 days post-surgery. CT

References

1. Kokich VO, Kokich VG, Kiyak HA. Perceptions of dental professionals and laypersons to altered dental esthetics: asymmetric and symmetric

About the authors

Periodontal surgeon: Michael Sonick, DMD
 Restorative dentist: Stephen Rothenberg, DMD



Dr. Michael Sonick is a full-time practicing periodontist and implant surgeon in Fairfield, Conn. He is on the editorial boards of many journals and is co-editor of the textbook, Implant Site Development. He is currently a guest lecturer at New York University School of Dentistry and is director of Sonick Seminars, in Fairfield, Conn.

ing the surgical template to delineate the desired tooth contours (Fig. 10).

The papillae were left intact and no sutures were required. Healing four weeks after the gingivectomy revealed a harmonious gingival drape (Fig. 11).

Final prosthetics

Placement of final veneers on teeth #4 through #15 occurred three months post-gingivectomy (Fig. 12). An occlusal bite guard was delivered to protect the restorations.

In order to correct lip line asymmetry and further diminish gingival display, neuromuscular lip correction (lowering) with BTX-A was reconsidered, but the patient did not pursue treatment.

Six years after veneer placement, the patient remained satisfied with the functional and esthetic result achieved solely through periodontal surgery and prosthetic rehabilitation (Figs. 13, 14).

Postoperative instructions After each surgical procedure, the patient was instructed

to take 600 mg of ibuprofen every 4-6 hours, hydrocodone 7.5 mg/acetaminophen 750 mg every 4-6 hours as needed for pain and 100 mg of doxycycline a day for 10 days.

The patient was instructed not to brush at or near the surgical site but instead to rinse with 0.12 percent chlorhexidine or warm saline twice daily. The patient was also directed not to chew in the affected area for at least two weeks.

MEDIA CME Self-Instruction Program

Dental Tribune Middle East & Africa in collaboration with CAPP introduce to the market the new project mCME - Self Instruction Program.

mCME gives you the opportunity to have a quick and easy way to meet your continuing education needs. mCME offers you the flexibility to work at your own pace through the material from any location at any time. The content is international, drawn from the upper echelon of dental medicine, but also presents a regional outlook in terms of perspective and subject matter.

How can professionals enroll? They can either sign up for a one-year (10 exercises) by subscription for the magazine for one year (\$65) or pay (\$20) per article. After the payment, participants will receive their membership number

and will be able to attend to the program.

How to earn CME credits?

Once the reader attends the distance-learning program, he/she can earn credits in three easy steps:

1. Read the articles.
2. Take the exercises
3. Fill in the Questionnaire and Submit the answers by Fax (+971 4 3686885) or Email :info@cappmea.com

After submission of the answers, (name and membership number must be included for processing) they will receive the Certificate with unique ID Number within 48 to 72hours.

Articles and Questionnaires will be available in the website after the publication.

www.cappmea.com

Moving the dental world from analogue to digital: 3Shape's success story continues

Bernhard Moldenhauer & Matthias Diessner
DTI

During SCANDEFA, a major dental fair in Scandinavia, DTI recently visited the 3Shape headquarters in the heart of

downtown Copenhagen to learn about the company's new products and future strategies. The historical building alongside Kongens Nytorv square and the Royal Danish Theatre has light and airy rooms, a perfect environment for a young,

passionate and ambitious organisation driven to develop the best technological solutions in 3-D scanning and CAD/CAM.

Often referred to as the "Google of the Dental Industry", 3Shape was launched eleven

years ago in a one-room apartment by two young and ambitious graduate students from the Technical University of Denmark and Copenhagen Business School—Tais Clausen and Nikolaj Deichmann. At the time, Clausen was completing his master's



From right to left: Nikolaj Deichmann (CFO), Tais Clausen (CTO) and one of the in-house developers at 3Shape. (DTI/Photo courtesy of 3Shape, Denmark)

AD

Belmont leads the way with a totally new generation of dental treatment centre.

CLESTA II

Belmont has combined cutting edge technology with traditional values for a dental treatment centre that offers sophistication, performance, flexibility and above all durability.

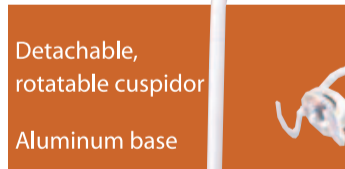
The Clesta II epitomizes Belmont's reputation for innovation, style, practicality and reliability. Technologically advanced and superbly engineered it represents a new generation of dental systems.



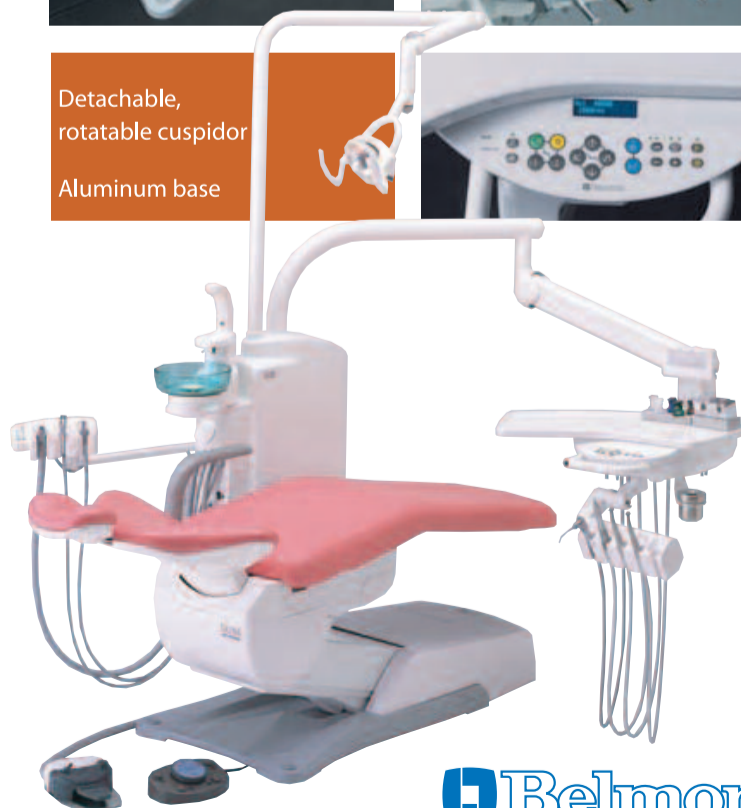Clesta-II E Rod type



Clesta-II E Holder type



Detachable, rotatable cuspidor
Aluminum base



TAKARA BELMONT CORPORATION
Tel. +81 (0)6 6213 5945 Fax. +81 (0)6 6212 3680

e-mail : belmont7@belmont-corp.co.jp <http://www.takara-net.com>

thesis on a groundbreaking 3-D scanning technology and Deichmann was finalising his Master's degree in Finance and Economics. Having met through friends, they joined forces to participate in the prestigious Venture Cup business plan competition, established by McKinsey and Co., in which they finished second. Throughout the competition, they constantly considered the manner in which the technology could be commercialised and thus the idea of launching 3Shape was born.

Initially, Clausen and Deichmann approached companies in the hearing-aid industry with the idea of developing a quality-control system for hearing-aid shells and ear moulds. Similar to a dental restoration, the devices need to be custom fitted to the patient's hearing canal and are traditionally made by taking an ear impression that is then manually sculpted, cut and used to make a mould—a time-consuming, manual procedure.

"During these first meetings, we realised that we could actually create a mass customisation production system," Deichmann remembered. "So instead of just checking the quality we decided to go directly for changing the workflow completely, from a manual process, where you spend several hours shaping the hearing-aid shells, to a completely digital workflow."

3Shape digitised the entire manufacturing process by introducing a 3-D scanner for ear impression taking, as well as the management software and CAD software needed to simulate the position of all the electronic components that need to fit into the patient's ear along with the shell, taking up minimal space and using CAM software for controlling the manufacturing equipment. They developed the system for a specific hearing-aid manufacturer but retained the rights to sell the technology to others.

At the time, there were only six companies that controlled approximately 90 % of the global hearing-aid market and within a period of three years, all of them went from a completely manual to an entirely digital production. Today, about 90 % of all hearing-aid devices are produced using 3Shape's technology.

Clausen and Deichmann were always aware of the 3-D scanning technology's enormous potential so they soon looked to other industries where the manufacturing processes are similar to the hearing-aid indus-

try, such as dental laboratories. In 2004, 3Shape began to receive an increasing number of requests from dental companies interested in the technology.

"We quickly decided that if we wanted to replicate our success in the hearing-aid industry, we needed to go for the full solution to have a very user-friendly system that the dental laboratories would adopt. Therefore, we went to a lot of laboratories, small ones and big ones, and tried to figure out how we could optimise the processes instead of just finding a better way to make zirconia copings. From the very beginning, our vision was to achieve a complete switch from analogue to digital," Deichmann explained.

3Shape introduced its first 3-D dental scanner and CAD/CAM software for virtual restoration design at the International Dental Show (IDS) in Cologne in 2005 and the system became a raving success. In the following years, the company extended and enhanced their dental laboratory product range by continuously responding to and involving their customers from the early stages of the product development process.

"Perhaps the most important lesson we have learned is that innovation is only successful if it moves and is guided in directions that truly benefit professionals in their daily work," Clausen, CTO and head of the 3Shape development team, pointed out.

Today, CAD/CAM has conquered dental laboratories and clinics, ensuring high profitability by maintaining top-level quality through standardised and controlled treatment and production processes that also benefit the patient. In Germany, traditionally an early adopter of new technologies, approximately 82 % of all ceramic restorations are already produced using CAD/CAM technology. "The question today is no longer if CAD/CAM will endure in the industry, but rather when all dental professionals will be taking advantage of it," Clausen said.

After having conquered the dental laboratory industry, 3Shape also extended the proven technologies to dental clinics. "We analysed all existing scanning systems on the market and defined what we like and what we didn't like about them. We wanted to create a system that incorporated all the advantages and eliminated all the drawbacks of the existing systems. Our solution really needed to be faster, easier, more accurate and more reliable," Deichmann said.

At the opening day of IDS 2011, 3Shape launched its newest achievement, the TRIOS intra-oral scanning solution, which aims to revolutionise the dental practice. The 3Shape booth was literally flooded with dentists trying to get a glimpse of the sleek and elegantly designed scanner.

One of the TRIOS 3-D scanner's notable features is that it does not require dentists to apply spray or powder to coat the patient's teeth, making scanning an easy, fast and comfortable process that does not ruin scan accuracy by adding material to

teeth surfaces. In addition, it can scan any material, such as metals, semi-transparent materials and skin. It only requires minimal training for use in clinical practice. The scanner captures over 3,000 2-D images per second, which is 100 times faster than a conventional video camera. Dentists who viewed the presentations at IDS stated that an "impression-free" dental practice seems to be just around the corner.

An open communication interface allows dentists to send the scanned data via the Internet directly to the laboratory of their choice, where the technician can start designing the restoration immediately using 3Shape Dental System software or the appropriate interface to third-party software. The TRIOS communication software includes a tool to visualise the technician's solutions for the patient, for example on an iPad, while the patient is still in the chair, which is espe-

cially important for anterior cases.

The system is designed to give dentists high-quality restorations and treat more patients rather than spending time and money on chairside milling. It handles a wide range of indications and produces quality 3-D data that can easily be realised by any laboratory.

Generally, digital data is controllable, predictable and available any time, requiring only minimal space. This guarantees

that the dentist owns and is able to use patient data without limitation and can potentially export virtual set-ups to other systems, such as for appliance manufacturing.

Surprisingly, 3Shape is the only major dental company that offers easily integrable solutions. All products are designed as plug-and-play solutions and feature open interfaces for connection to third-party applications.

→ DTI page 10

AD

DENTOFLEX takes you to BRAZIL!

NEXT GROUP
02 - 09 Oct 2011

Implant Course Package

All Trip Includes:

Course at São Paulo City:

- Air Tickets (MENA Countries - São Paulo - MENA Countries)* economy class
- Airport Pickup and Drop-off + City Transfers
- Hotel (Double Room) with Breakfast* tourist class
- Lunchs

Tour to Rio de Janeiro City:

- Air Tickets (São Paulo - Rio - São Paulo)
- Airport Pickup and Drop-off + City Transfers
- Hotel (Double Room) with Breakfast
- 4 Days Tour in Rio de Janeiro- Tour Guide
- Tour Visit (One Ticket Included per person) to:
 - » Cristo Redentor Estatue (The 7th Wonders of the World)
 - » Maracanã Soccer Stadium (Brazilian Biggest Stadium)
 - » Sugar Loaf (With Cable Car)
 - » Copacabana Beach

Our Offer for Trip Course

Trip Includes:

- 1 - Mix Surgical Set (Conical and Cylindrical)
- 30 - Dental Implant (Cylindrical or Conical)
- 30 - Straight Abutment (Fixed or Cemented)

Course at São Paulo City:

- 3 Days Courses (intensive 20 hours)
- Dentoflex Company and Plant tour
- Implant Lectures + Hands on Training and Surgeries
- Live Surgery with live broadcast
- Visit to Brazilian Dental Association
- Certificate Ceremony with Gala Dinner
- Airport Pickup and Drop-off + City Transfers
- Hotel (Double Room) with Breakfast* tourist class

USD 7,500

Implant System

Dentoflex Middle East | Jafza View Lob 19 Office 1301 | Dubai - U.A.E - P.O. Box 261901
 Tel: +971 (0) 48855404 Fax: +971 (0) 48855405 | www.dentoflex.com.br / education@dentoflex.com.br