

# DENTAL TRIBUNE

The World's Dental Newspaper • Pakistan Edition



PUBLISHED IN PAKISTAN

www.dental-tribune.com.pk

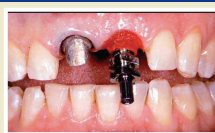MARCH, 2015 - Issue No. 02 Vol.2

Dux Dental now part of the KaVo Kerr Group's global platform of brands



*INTERNATIONAL NEWS* ▶ Page 2

Periodontal and peri-implant tissue management in the aesthetic zone



*CLINICAL PRACTICE* ▶ Page 4

The Pioneer of Community Dentistry in Pakistan - Dr Rafia Khanum Malik Passes Away



▶ Page 6

## PDA International Dental Congress "Multi-disciplinary Approach in Dentistry" need of the hour; Governor Sindh

DT International Report

**K**ARACHI: The Governor of Sindh inaugurated the 12th International and 32nd National Dental Congress at the Expo Centre, Karachi is being jointly organized by Pakistan Dental Association (PDA) Sindh and Karachi in collaboration with the Dental Trade & Manufacturers Association (DTMA).



Commenting on the theme of "Multi-disciplinary Approach in Dentistry" the governor said that it is need of the hour as it will play a pivotal role in the overall health delivery system in Pakistan. He admired the growth of educational institutions and said that this will help the youth realize their dream of becoming a health professional.

He appreciated the efforts of PDA and promised to look into the issues raised to give the profession a much needed boost.

Earlier the proceedings started with the National Anthem followed by verses from the Holy Quran. Dr Asif Arain in his welcome address appreciated the efforts of the

organizers and said that this is a sign of maturity in the profession where general practitioners and academicians are coming on a single platform to forge ahead the Continuous Dental Education initiative for the entire dental fraternity.

Dr Saqib said that Pakistan dental Association is the only representative body of the dental fraternity and is working towards introducing health insurance and soft loans for the professionals.

Dr Mahmood Shah in his address highlighted the dentist patient ratio in the Sindh which stands at 1:100000

*Continued on page 11*

## Women in Dentistry - the trend setters

DT Pakistan Report

**F**aisalabad: The 1st International Women Dental Conference at the University of Faisalabad will be held at Faisalabad on 10th to 12th of April, 2015 in collaboration with Dental News - the theme of the congress is Women in Dentistry, the Trend Setters. The event is supported by the Higher Education Commission and Pakistan Dental Association. The conference aims to highlight the emerging role of female practitioners in the field of Dentistry in Pakistan. With participants of the conference coming from all over Pakistan including students and distinguished faculty members of the Dental Colleges, the event is to host several key speakers from Pakistan and abroad focusing on the subject of Women dentists as the new trend setters in the dental fraternity.

The distinguished guests and speakers will share their experience and expertise on the leading role of female dentist around the world and especially in Pakistan. The conference is aimed to encourage women to take greater role in the field of specialized dentistry in being a positive force in their community.

"We are very excited to hold the first Women Dentist

Conference at the University of Faisalabad and look forward to see the participants take a learning experience from the event", said the principal of UMDC, Dental Section, Faisalabad, Prof Akhtar Bokhari.

The Patron in Chief of the event is Begum Mian Mohammad Saleem, wife of the Founder Chairman of the Madina Foundation. The patrons are Prof. Dr. Tasleem Hosein, Prof. Dr. Nazia Yazdani, Prof. Dr. Talat Firdous, Prof. Abida Ejaz and Brig. Shehnaz Nasim.


The conference will encompass scientific sessions and workshops by the speakers including entrepreneurship in dentistry and practice management. The event will also hold Poster/ Table clinic competition, Research Competition, Presentation skills competition, Qirat & Na'at competition and Quiz competition for the participants of the conference. All the activities hold cash prizes for the winners and runners up. PDA Faisalabad oath taking ceremony will also take place during the congress and Prof Dr Saqib Rashid will administer the oath.



## Ready, steady, IDS!

DT International Report

**C**OLOGNE, Germany: Cologne is set to become the centre of the global dental community again, when the 36th International Dental Show (IDS) opens tomorrow here at the Koelnmesse exhibition centre in Cologne.



The organiser, Koelnmesse, has announced that Lutz Stroppe, State Secretary at the Federal Ministry of Health, will welcome participants to the 2015 edition at the official opening of the event, to be held during a welcome ceremony on Tuesday morning. Traditionally, the first day of the show, known as Dealers' Day, will be dedicated to business-to-business activities.

*Continued on page 11*

## World Oral Health Day celebrations in Pakistan

DT Pakistan Report

**K**ARACHI- Dental Tribune and Dental News in collaboration with Pakistan Dental Association launches its World Oral Health Day 2015 (WOHD 2015) 'Smile for life' campaign backed by FDI, JPDA, FDI partner associations and the sponsor in Pakistan Shield Corporation. The theme of 2015 is smile for life which is to remind people everywhere about the importance of looking after their teeth and gums.

World Oral Health Day is celebrated throughout the world on 20th March and in Pakistan this will be the 5th year running where Shield Corporation as part of their CSR activities will be sponsoring the mega event being held in over 36 dental college hospitals in 15 cities across Pakistan. It is an international day to celebrate the benefits of a healthy mouth and to promote

*Continued on page 11*




# Combination of antimicrobial dental care products helps to prevent caries

## DT International Report

**G**RONINGEN, Netherlands: Dutch researchers have conducted a study to compare the formation of biofilms on retention wires in the context of different oral health care regimens. The study found that patients with bonded retainers who use an antimicrobial toothpaste in combination

Center Groningen aimed to determine whether the use of oral antimicrobials in the form of toothpastes with antibacterial claims and an antimicrobial mouthrinse influences the composition of the biofilm on single-strand and multi-strand wire retainers.

The researchers examined the retention wires



with a mouthrinse containing essential oil can reduce the number of bacteria present in the oral biofilm and thereby prevent tooth decay. Bonded retainers are a common device used after orthodontic treatment to prevent the teeth from relapsing into pretreatment positions. However, various bacteria tend to accumulate on retention wires, and this increases the risk of gingival recession and bleeding and of increased pocket depth.

In their study, the researchers at the University of Groningen and the University Medical

of 22 adult volunteers, who were divided into two groups and had to adhere to three different oral health care regimens in the course of 15 weeks. Each regimen was maintained for one week with a six-week wash-out period between each regimen.

The first group used a different toothpaste for every regimen, including two antibacterial toothpastes and one without antibacterial claims. The second group used the same toothpastes, but combined them with a

*Continued on page 11*

# Dux Dental now part of the KaVo Kerr Group's global platform of brands

## DT International Report

**N**EW YORK, N.Y., USA: Those looking for Dux Dental at the recent Greater New York Dental Meeting could find it at the Kerr booth. Following the June acquisition of Dux by the Danaher Corp., Dux is now part of the KaVo Kerr Group's global platform of brands. Rob Laurenti, with Dux, was stationed in the Kerr booth with a number of popular Dux Dental products, including free samples of Identic alginate and Clean and Lube wipes.

Laurenti said the Identic alginate is known for its easy mixing and accurate results. The free sample is one of the single-unit doses. Laurenti said the Clean and Lube wipes or spray work great to keep your alginate bowl clean, and they will also help the bowl last longer.

Also available are the company's popular Bib-Eze disposable bib holders, which enable you to never clean a bib chain again, supporting your practice's infection-control efforts. Another popular offering from the company



is its lead-free apron for patient X-ray procedures. It's 30 percent lighter than typical leaded aprons and provides 100 percent of the protection, according to the company. In addition to DUX Dental, the KaVo Kerr Group global platform of brands includes KaVo, Kerr, Kerr Total Care, Pentron, Axis|SybronEndo, Orascoptic, Pelton & Crane, Marus, DCI Equipment, Gendex, DEXIS, Instrumentarium, SOREDEX, i-CAT, NOMAD, Implant Direct and Ormco. All are part of the Washington, D.C.-based conglomerate Danaher Corp.

## DENTAL TRIBUNE

The World's Dental Newspaper • Pakistan Edition

### Publisher/CEO

Syed Hashim A. Hasan  
hashim.hasan@dental-tribune.com.pk

### Editor Clinical Research:

Dr. Inayatullah Padhiar

### Editors Research & Public Health

Prof. Dr. Ayyaz Ali Khan

### Editor - Online

Haseeb Uddin

### Graphics Designer

Sh. M. Sadiq Ali

### Dental Tribune Pakistan

3rd floor, Mahmood Centre, BC-11, Block-9  
Clifton, Karachi, Pakistan.

Tel.: +92 21 35378440-2 | Fax: +92 21 35836940

www.dental-tribune.com.pk info@dental-tribune.com.pk

Dental Tribune Pakistan cannot assume responsibility for the validity of product claims or for typographical errors. The publisher also does not assume responsibility for product names or statements made by advertisers. Opinions expressed by authors are their own and may not reflect of **Dental Tribune Pakistan.**

## International Imprint

### Group Editor

**Daniel Zimmermann**

newsroom@dental-tribune.com

Tel.: +49 341 48 474 107

### Clinical Editor

**Magda Wojtkiewicz**

### Online Editors

**Yvonne Bachmann**

**Claudia Duschek**

**Sabrina Raaff**

**Hans Motschmann**

### Copy Editors

### Publisher/President/CEO

**Torsten Oemus**

### Chief Financial Officer

**Dan Wunderlich**

### Business Development Manager

**Claudia Salwiczek**

### Events Manager

**Lars Hoffmann**

### Media Sales Managers

**Matthias Diessner**

(Key Accounts)

**Melissa Brown**

(International)

**Peter Witteczek**

(Asia Pacific)

**Maria Kaiser**

(North America)

**Weridiana Mageswki**

(Latin America)

**Hélène Carpentier**

(Europe)

### Marketing & Sales Services

**Nadine Dehmel**

**Nicole Andrä**

### Accounting

**Karen Hamatschek**

**Anja Maywald**

**Manuela Hunger**

### Executive Producer

**Gernot Meyer**

### Dental Tribune International

Holbeinstr. 29, 04229 Leipzig, Germany

Tel.: +49 341 48 474 302 | Fax: +49 341 48 474 173

info@dental-tribune.com | www.dental-tribune.com

### Regional Offices

#### Asia Pacific

Dental Tribune Asia Pacific Limited

Room A, 20/F, Harvard Commercial Building,

105-111 Thomson Road, Wanchai, Hong Kong

Tel.: +852 3113 6177 | Fax: +8523113 6199

#### The Americas

Tribune America, LLC

116 West 23rd Street, Ste. 500, New York, N.Y. 10011, USA

Tel.: +1 212 244 7181 | Fax: +1 212 244 7185

# SENSODYNE®

## COMPLETE PROTECTION POWERED BY NOVAMIN

### Sensodyne® understands that dentine hypersensitivity patients have differing needs


Sensodyne® Complete Protection, powered by NovaMin®, offers all-round care with specially designed benefits to meet your patients' different needs and preferences. With twice-daily brushing, Sensodyne® Complete Protection:

- Is clinically proven to provide dentine hypersensitivity relief<sup>1-3</sup>
- Contains fluoride to strengthen enamel
- Helps to maintain good gingival health<sup>4-6</sup>

### Sensodyne® Complete Protection, powered by NovaMin® – an advanced approach to dentine hypersensitivity relief

- NovaMin®, a calcium and phosphate delivery technology, initiates a cascade of events on contact with saliva<sup>7-12</sup> which leads to formation of a hydroxyapatite-like restorative layer over exposed dentine and within dentine tubules.<sup>7, 9-13</sup>
- In vitro* studies have shown that the hydroxyapatite-like layer starts building from the first use<sup>7,9</sup> and is up to 50% harder than dentine.<sup>9,14</sup>
- The hydroxyapatite-like layer binds firmly to collagen within exposed dentine<sup>10,15</sup> and has shown in *in vitro* studies to be resistant to daily physical and chemical oral challenges,<sup>9,14-17</sup> such as toothbrush abrasion<sup>16</sup> and acidic food and drink.<sup>14-17</sup>

**In vitro studies show that a hydroxyapatite-like layer forms over exposed dentine and within the dentine tubules.<sup>7,9,10,12,13</sup>**



Hydroxyapatite-like layer **over** exposed dentine

Hydroxyapatite-like layer **within** the tubules at the surface

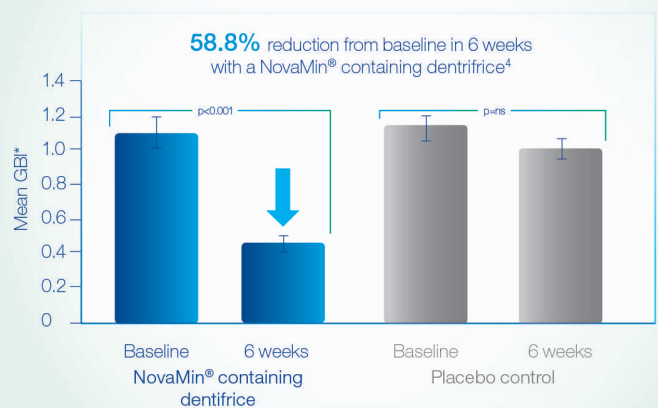
Adapted from Earl et al, 2011 (A).<sup>13</sup> *In vitro* cross-section SEM image of hydroxyapatite-like layer formed by supersaturated NovaMin® solution in artificial saliva after 5 days (no brushing)<sup>13</sup>

### Sensodyne® Complete Protection helps to maintain good gingival health<sup>4-6</sup>

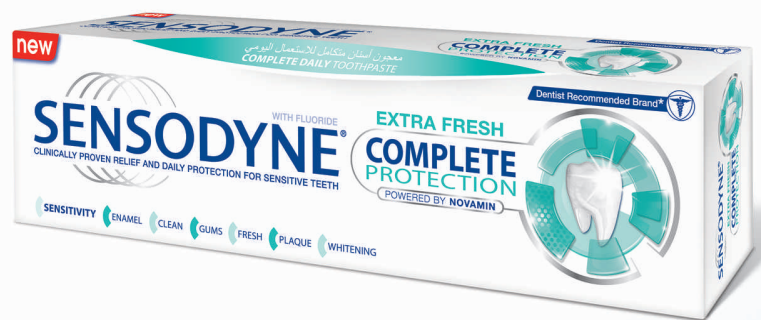Good brushing technique can be enhanced with the use of a specially designed dentifrice to help maintain good gingival health.<sup>18,19</sup>

In clinical studies, NovaMin® containing dentifrices have shown up to 16.4% improvement in plaque control as well as significant reduction in gingival bleeding index, compared to control toothpastes.<sup>4-6</sup>

#### Significant reduction in gingival bleeding index (GBI) over 6 weeks with a NovaMin® containing dentifrice<sup>4</sup>



Adapted from Tai et al, 2006.<sup>4</sup> Randomised, double-blind, controlled clinical study of 95 volunteers given NovaMin® containing dentifrice or placebo control (non-aqueous dentifrice containing no NovaMin®) for 6 weeks. All subjects received supragingival prophylaxis and polishing and were instructed in brushing technique.<sup>4</sup> \*GBI scale ranges from 0–3.



**References:**

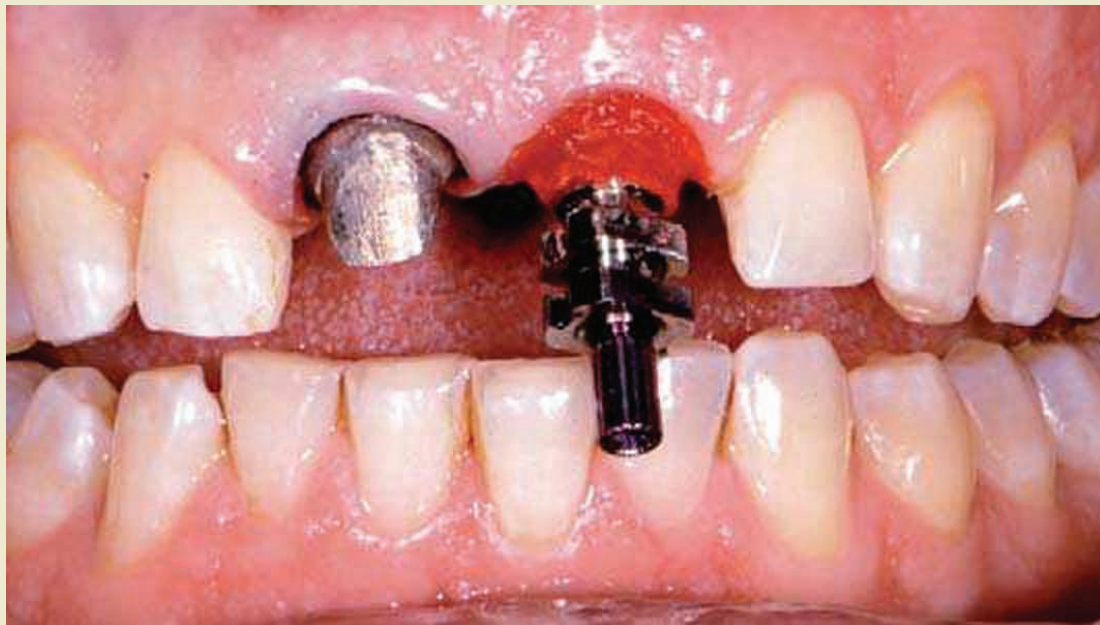- Du MQ et al. Am J Dent 2008; 21(4): 210–214.
- Pradeep AR et al. J Periodontol 2010; 81(8): 1167–1173.
- Sallian S et al. J Clin Dent 2010; 21(3): 82–87.
- Tai BJ et al. J Clin Periodontol 2006; 33: 86–91.
- Devi MA et al. Int J Clin Dent Sci 2011; 2: 46–49.
- GSK data on file (study Z3690864)
- LaTorre G, Greenspan DC. J Clin Dent 2010; 21(3): 72–76.
- Edgar WM. Br Dent J 1992; 172(8): 305–312.
- Burwell A et al. J Clin Dent 2010; 21(3): 66–71.
- Efflandt SE et al. J Mater Sci Mater Med 2002; 13(6): 557–565.
- de Aza PN et al. J Mat Sci: Mat in Med 1996; 399–402.
- Arcos D et al. A J Biomed Mater Res 2003; 6(3): 344–351.
- Earl JS et al. J Clin Dent 2011; 22(3): 62–67. (A) 14. Parkinson CR et al. J Clin Dent 2011; 22(3): 74–81. 15. West NX et al. J Clin Dent 2011; 22(3): 82–89. 16. Earl JS et al. J Clin Dent 2011; 22(3): 68–73. (B) 17. Wang Z et al. J Dent 2010; 38(5): 400–410. 18. "Dentifrices" Encyclopedia of Chemical Technology 4th ed. vol 7, pp. 1023–1030, by Morton Poder Consumer Products Development Resources Inc. 19. Van der Weijen GA and Hioe KPK. J Clin Periodontol 2005; 32 (Supp 1.6): 214–228. Date of Preparation: September 2013. GCSAE/CHSENSO/0231/12

GSK is committed to the effective collection and management of human safety information relating to our products and we encourage healthcare professionals to report adverse events to us on +92 (21) 111-475-725 or pk\_pharmasafety@gsk.com

### All-round care for dentine hypersensitivity patients<sup>1-6</sup>

# Periodontal and peri-implant tissue management in the aesthetic zone

by Dr Riccardo Verdecchia, Italy



Dental and skeletal asymmetries, as well as bone defects at the implant site, can interfere with good aesthetic outcomes and thus pose surgical and prosthetic challenges for dentists in clinical cases. In this article, Dr Riccardo Verdecchia (Italy), an experienced dentist with a focus on periodontology, implant dentistry and fixed prosthodontics, describes treatment planning and implant placement in a patient with a vertical fracture of the maxillary left central incisor who showed a number of risk factors that had led to the fracture.

## Initial situation

A 38-year-old male patient with a non-contributory medical history presented owing to a vertical fracture of the maxillary left central incisor (tooth #21). The patient showed a combination of risk factors that together had led to the fracture: the absence of the ferrule effect, short posts, bruxism, and occlusal overload due to premature contacts during protrusive movements (Figs. 1–3).

## Treatment plan

Based on the clinical and radiographic examination, the aesthetic risk profile was determined to range from medium to high on the International Team for Implantology's aesthetic risk assessment guidelines. Horizontal and vertical bone defects were detected, with a distance of 6 mm from bone level to the contact points (Fig. 4). A delayed implant placement (Type 2) was planned in order to achieve complete healing of the soft tissue before the guided bone regeneration procedures and implant placement. In order to minimise the number of surgical appointments and reduce the overall morbidity, a simultaneous approach of periodontal and implant surgery was preferred. The periodontal tissue of tooth #11 was modified along with implant surgery on region #21 with two different objectives: (a) to increase the ferrule effect and move the mid-facial soft-tissue margin slightly upwards to improve the harmony of the scalloped mucosal line (Fig. 5); and (b) to hide the dark underlying appearance of the root with a connective tissue graft (Fig. 2). The initial phase involved the removal of the

fractured tooth #21 utilising a periosteal elevator. The extraction socket was filled with a collagen plug to achieve stabilisation of the blood clot during the initial healing of the soft tissue. A Maryland bridge was cemented on the same day and modified to avoid interferences during protrusive movements (Fig. 6).

## Procedure

### First surgical procedure

Six weeks later, periodontal and implant surgery were performed. A mid-crestal incision was executed on the implant site. At this stage, scalloped incisions were applied on the palatal and buccal sides of tooth #11. Afterwards, buccoral osteotomies on the root were performed for the previously described goals. The tiny interproximal bone peak was treated with due respect and left untouched (Fig. 7).

Subsequently, a Straumann Bone Level implant (? 4.1 mm, SLActive 12 mm) was inserted in the correct 3-D position to replace tooth #21 (Fig. 8). Shortly afterwards, autogenous bone chips were harvested locally and applied to cover the dehiscence-type defect. A layer of Straumann BoneCeramic (400–700 µm) was placed to overcontour the external surface of the facial bone. The grafting material was covered with a non-cross-linked collagen membrane in accordance with guided bone regeneration principles (Fig. 9). A double-layer technique was used to improve the stability of the membrane. Once perfused with blood, the membrane could be easily adapted to the alveolar bone crest and did not require any additional fixation. Tension-free primary wound closure was achieved with horizontal mattress sutures after splitting the periosteum at the base of the flap (Fig. 10). The ovate pontic was ground to avoid pressure on the tissue below. The provisional bridge was then recemented (Fig. 11).

### Second surgical procedure

The stability of the provisional bridge allowed an extended interval (four months) for the final flattening of the ridge contour due to remodelling of the alveolar bone. A roll flap technique was then regarded as adequate to compensate for a

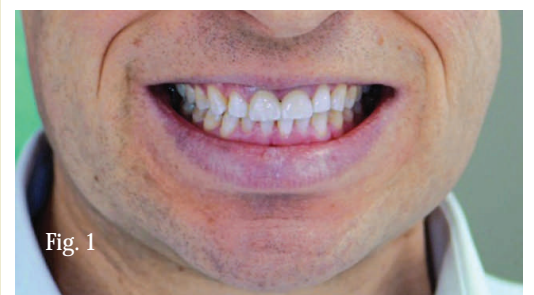

Fig. 1

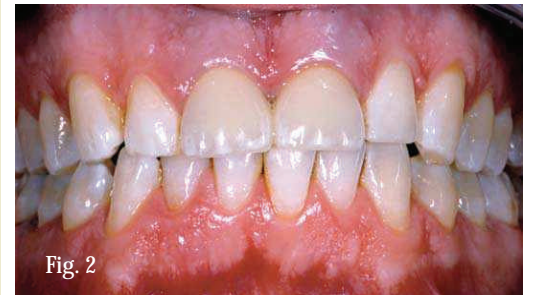

Fig. 2

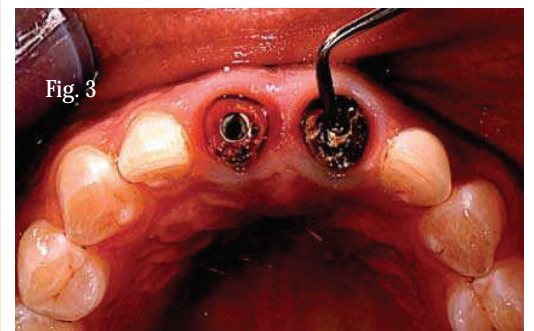


Fig. 3

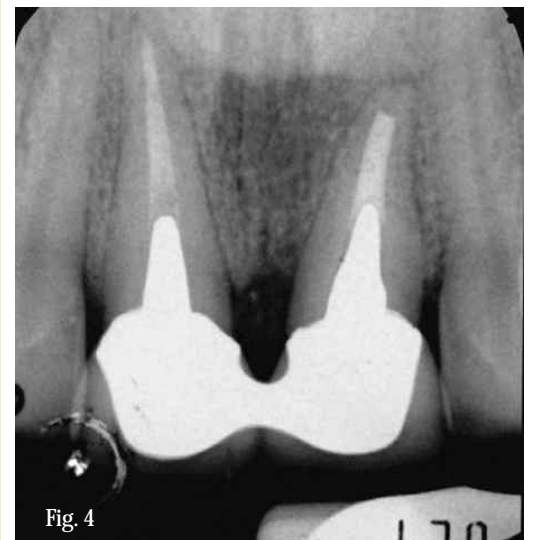


Fig. 4

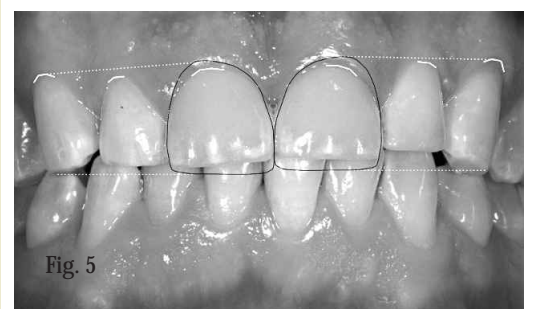

Fig. 5

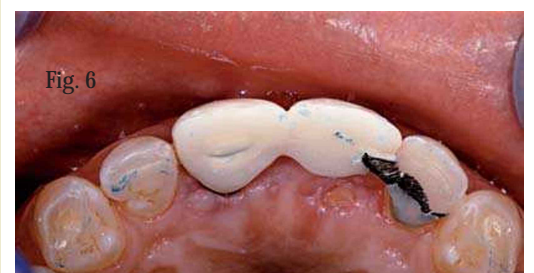

Fig. 6

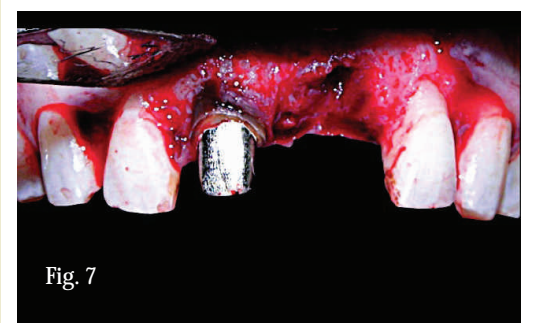

Fig. 7

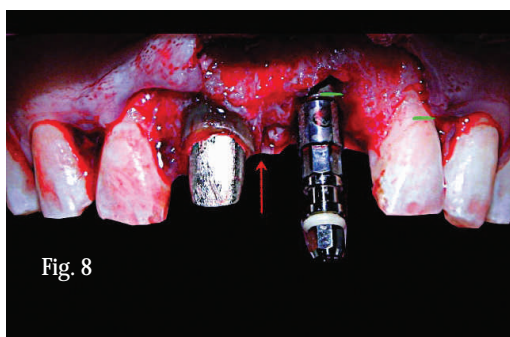


Fig. 8

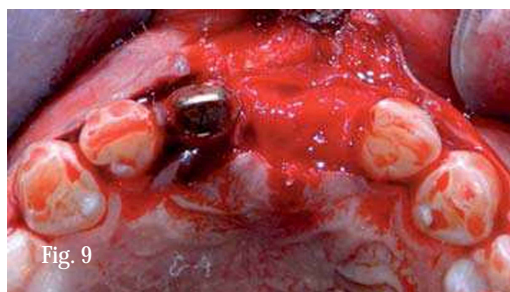


Fig. 9

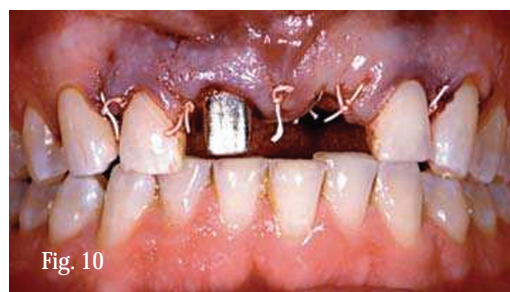

Fig. 10

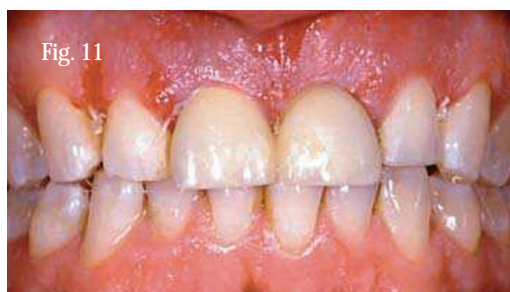

Fig. 11

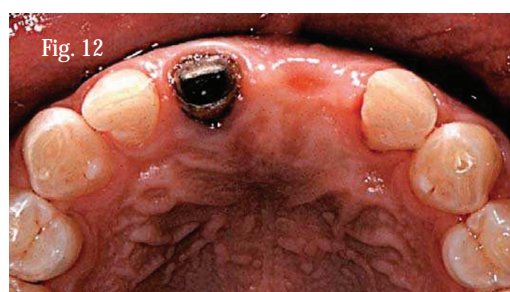


Fig. 12

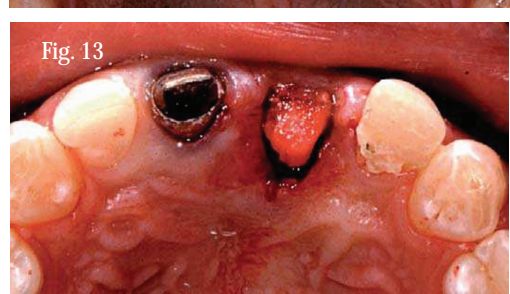


Fig. 13

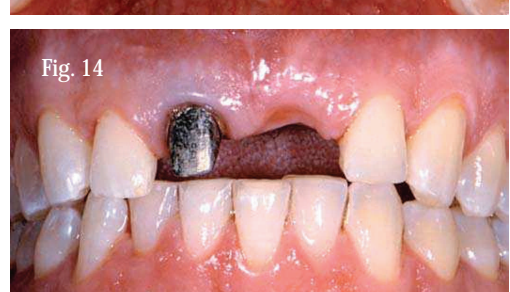

Fig. 14

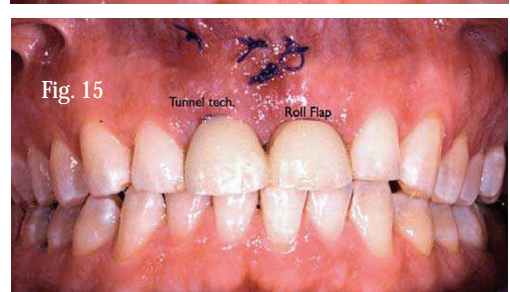


Fig. 15

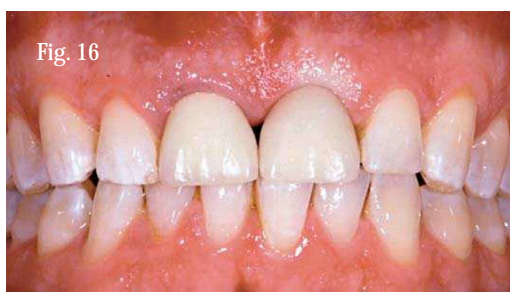

Fig. 16

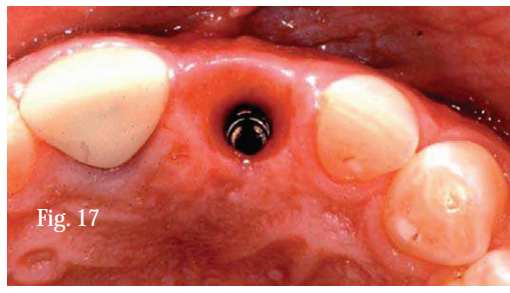


Fig. 17

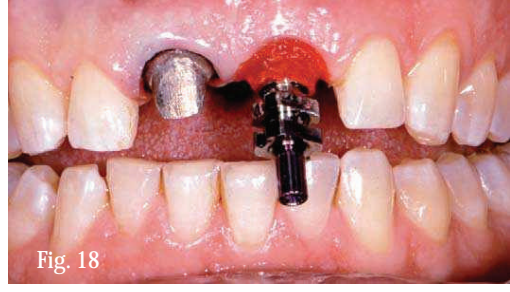

Fig. 18

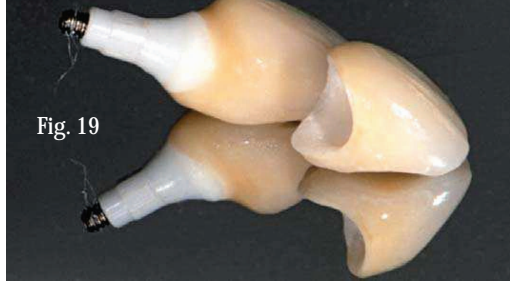

Fig. 19

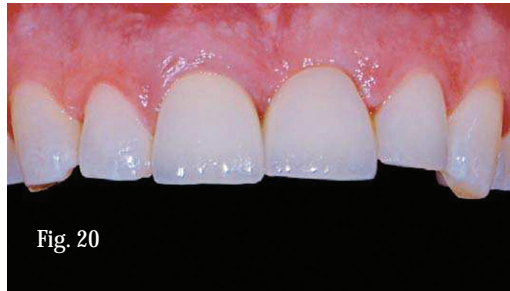

Fig. 20

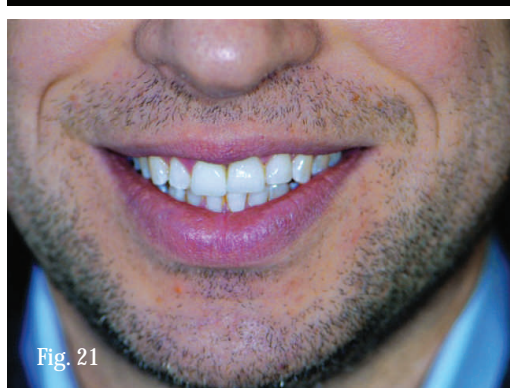


Fig. 21

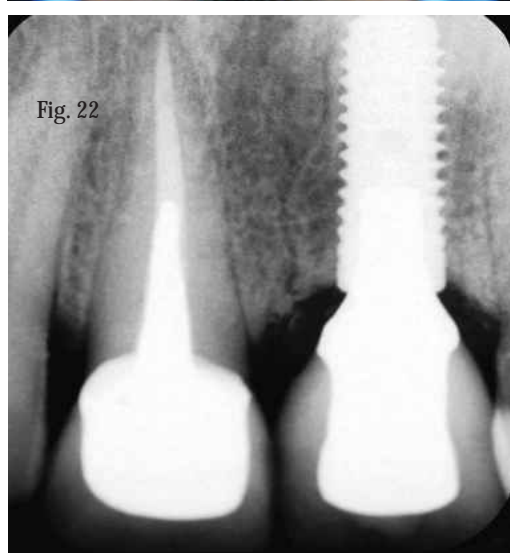


Fig. 22

mild horizontal discrepancy at region #21 (Figs. 12 & 13). Meanwhile, a very thin (= 1 mm) connective tissue graft was harvested from the premolar area of the palate and inserted with a tunnel technique in a supra-periosteal pouch, with the purpose of hiding the dark aspect of the nearby root of tooth #11 (Figs. 14 & 15). In both surgical appointments, vertical papillary incisions, which had been deemed not necessary, could be avoided.

**Prosthetic procedures**

A screw-retained provisional crown remained in situ for six months on the implant while maturation and stabilisation of the peri-implant soft-tissue contours were established. During this period, modifications in form, contour and outline were effected to improve the aesthetic outcome using a light-curing composite material (Fig. 16). Proper implant placement allowed the establishment of an optimal final subgingival contour (Fig. 17). A customised impression coping was then fabricated to capture the transition zone contour created by the provisional restoration. For the final restoration, a CAD/CAM zirconia abutment was selected and Straumann CARES CAD/CAM was used to fabricate the frameworks (Figs. 18 & 19). The screw access position allowed the use of a one-piece restoration. The abutment was veneered using a pressable ceramic system. After the try-in and colour correction by the laboratory, the final crown was delivered to the patient and tightened at 35 N cm. The access hole was sealed with gutta-percha and a light-curing composite resin. The prosthetic procedures on the root of tooth #11 involved the delivery of a longer golden post in order to reduce the risk of root fracture. For the same purpose, it was essential to perform prosthetic preparation of the palatal aspect of the gold abutment to create 1.5–2.0 mm of space for the zirconia framework and pressable ceramic. The final goal was to avoid interference during protrusive movements.

**Conclusion**

The surgical and prosthetic challenge in this clinical case was to develop a natural scalloped mucosal line on the maxillary central incisors and to obtain a good aesthetic outcome with the prosthetic crowns, despite the various existing dental and skeletal asymmetries and the bone defects at the implant site.

Of utmost importance was knowledge of the hard- and soft-tissue remodelling around the implant in region #21 and around the root of tooth #11 after the surgical steps.

A benefit resulting from the conservation of the root of tooth #11 was the maintenance of the interproximal height of the tiny bone peak, which provided support to the papilla mesial to the implant. Furthermore, this approach was highly beneficial to the natural appearance of the prosthetic crowns (Figs. 20 & 21). The periapical radiograph (two-year follow-up) shows the stable crestal bone levels around the implant (Fig. 22).

**About the Author**

**Riccardo Verdecchia, DMD,** maintains a private practice in Rome (Italy) specializing in periodontology, implant dentistry and fixed prosthodontics.



He is a member of the International Team for Implantology and the Società Italiana di Parodontologia e Implantologia (Italian society of periodontology and implantology). He can be contacted at [riccardo.verdecchia@hotmail.com](mailto:riccardo.verdecchia@hotmail.com).

## PDA Congress 2015 Green dentistry is environment friendly and economical

### DT Pakistan Report

**K**ARACHI - Pakistan Dental Association recently organized their 12th International and 32nd National Dental Congress at Karachi Expo Center in collaboration with Dental Trade & Manufacturers with active international support of APDF and ICCDE. The successful congress was attended by over three thousand delegates from all over Pakistan.

Asia Pacific Dental Federation organized a successful session on "Green dentistry" devoted exclusively to promote environmentally sound dental



practices. A number of professionals from the field, including; Dr. Ayyaz Ali Khan shared valuable information regarding the massive production of toxic and non-toxic waste from the daily dental practices, environmental hazards, their solutions and implementation.

Dr. Kulsoom Fatima Rizvi, Principal Dental Section and Head of Community Dentistry Department at Bahria University Medical and Dental College Karachi, spoke on the topic of "Lifestyle and Dentistry". She said that practicing green dentistry is not only environment friendly but also economical. Adopting eco-friendly practices can help dentists reduce their operator cost, in addition to preserving natural resources. Green dentistry reduces waste and pollution; conserves energy together with incorporation of technology and supports a wellness lifestyle. Her lecture emphasized the best practices in dental office that are cost effective, customer centric and reduce the negative impact on environment and general health. At the end of the session, speakers were appreciated for their insightful lectures and were acknowledged with memento shields presented by Dr. Anwar Saeed- Chairman Dental Public Health at APDF, Dr Asif Arain - Vice President of APDF and Chairman PDA Congress 2015, Dr. Saqib Rasheed - President PDA Central, and Dr Mehmood Shah - President PDA Sindh

## Dr Rafia Khanum Malik Passes Away

### DT Pakistan Report

**I**t was sad to know that Dr Rafia Khanum Malik died on 18th January, where her funeral was held to days later on 20th of January, 2015 in London.

Dr Rafia Malik graduated from deMontmorency College of Dentistry, Lahore. In 1970, She got the license to practice in England where she got the diploma in Dental Public Health, from Royal College of Surgeons, England in 1984. She returned to Pakistan in 1985 to help Lever Brothers Pakistan run "Lever Dental Hygiene Service". In Karachi, She did 800 Schools where she gave "dental health education" to promote prevention of Dental Diseases. In July, 1987, she laid the foundation stone of "Institute of Preventive

Dentistry and Dental Public Health" to train the para dental staff. She started a dental surgery and worked as Consultant Dental Surgeon in Karachi.

In November, 1988, she appointed as "project director" to help set up Baqai Dental College. Two new subjects-Community Dentistry and "Pre-clinical Training"- were introduced in the curriculum of BDS syllabus by Dr Rafia Khanum Malik.

She wrote lots of books on Prevention of Dental Diseases for general public.

She was appointed Vice Principal of Baqai College of Dentistry for three years.

She gave "dental health education" through Radio programmes and Pakistan Television. She did lots of welfare work in Karachi, under the umbrella of an NGO "Amin Wadee". She started School of Dental Hygienists, affiliated with Sindh Medical Faculty in 1995 to train 'Dental Surgery Assistants' and 'Dental Hygienists'. She attended many courses and seminars in London.

*Continued on page 11*



## DTI Media Lounge - Where movers and shakers in the dental market meet

### DT International Report

**C**OLOGNE, Germany: Over the past week, the International Dental Show (IDS) drew thousands of people from all over the world to Cologne. As an IDS tradition, Dental Tribune International (DTI) invited its partners to a number of cocktail receptions to the DTI Media Lounge. During the receptions, attendees received business updates on international markets and had the opportunity to connect with their peers and leaders from the dental industry.



The traditional Russian Night was celebrated at the DTI booth on the first day of IDS. The event was organised in collaboration with the Russian Dental Association, the Moscow Dental University, and Dentalexpo. Ilya Brodetski, General Director of Dentalexpo, provided some insights into the Russia dental market and its importance for the global dental industry. Currently, there are 85,000 dentists and 25,000 dental technicians in Russia. The market has a yearly supply turnover of US\$ 1 billion.

On the second day of IDS, DTI hosted the CHANNEL3 Night, which was organised together with Exit Strategies, for the first time. About 80 key opinion leaders from 15 countries gathered on Wednesday at DTI's MEDIA Lounge for their annual meeting. As part of the event, Harvard professor Myron Nevins received the first annual PI Brånemark Award. The number three in CHANNEL3 signifies the three channels of sales in the dental industry: sales by dealer, direct sales and sales resulting from the work of key opinion leaders. The group consists of leaders from all three areas.

On 12 March, industry partners of DTI gathered for the DDS World and Chinese Night in Hall 4.2. In 2014, DTI launched its Digital Dentistry Show, the first exhibition to focus solely on digital products and applications for dentistry, in Milan in Italy as part of

International Expodental. The show will travel around the world and be present in all major dental markets. Participants of the night were informed that the next DDS World show will take place in Athens from 22 to 24 May 2015 and will be organised in collaboration with OMNIPRESS. Further shows in 2015 are planned in Moscow, Budapest, Shanghai and New York. The event on Wednesday was also attended by representatives of the Chinese Stomatological Association.

The Brazilian Night on 13 March attracted many people. The event was a joint project of DTI and Associação Paulista de Cirurgiões-Dentistas (APCD), the São Paulo association of dental surgeons, with which DTI entered into an international media agreement in 2013. Under the contract, DTI's today trade show newspaper became the official and exclusive publication at the Congresso Internacional de Odontologia de São Paulo (CIOSP), one of the leading congresses worldwide.

## Structured lifestyle helps prevent dental caries in children

### DT International Report

**L**EIDEN, Netherlands: Dental caries is one of the most common chronic childhood diseases worldwide and can affect a child's quality of life significantly. Several studies have identified a correlation between caries and lifestyle factors, such as physical activity and meal frequency. A team of researchers has now found that, especially for younger age groups, regularity and a structured lifestyle are very important for preventing caries.



The researchers at the Netherlands Organisation for Applied Scientific Research examined the impact of such factors on caries experience at different ages. They based their study on the data collected in a previous study on oral health in children and adolescents in the Netherlands that aimed to describe the oral health status and the preventive dental behaviours of 9-, 15- and 21-year-olds. The scientists used the existing data, collected through questionnaires and clinical oral examinations, to study the probability of caries and the degree of caries experience in relation to several lifestyle factors. The lifestyle factors included were the frequency of toothbrushing per day, the frequency of having breakfast per week, and the frequency of food and drink consumption per day. The 21-year-olds examined in the study did not show significant differences in caries experience in relation to the lifestyle factors studied. For the 9- and 15-year-olds, however, the lifestyle factors had a significant effect on their dental caries experience.

For the two younger age groups, not having breakfast and not brushing their teeth twice a day were associated with a significantly higher caries experience.

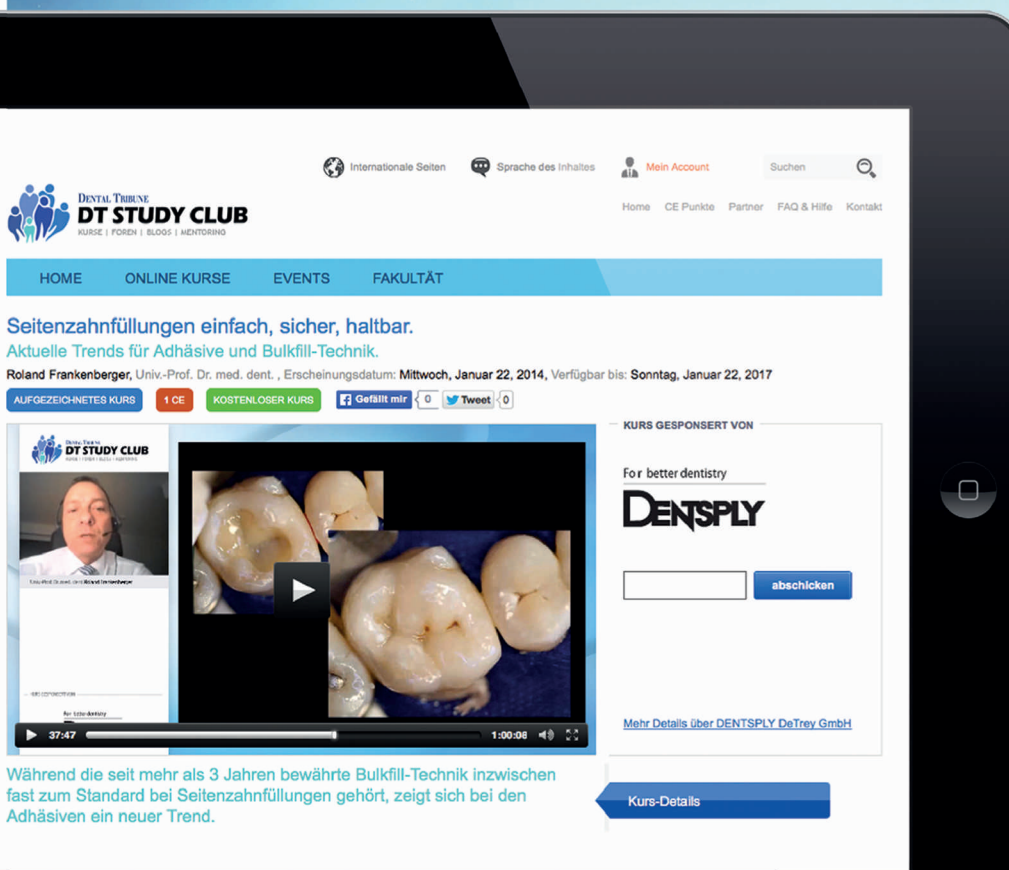
*Continued on page 11*

# Join the largest educational network in dentistry!



[www.DTStudyClub.com](http://www.DTStudyClub.com)

- education everywhere and anytime
- live and interactive webinars
- more than 500 archived courses
- a focused discussion forum
- free membership
- no travel costs
- no time away from the practice
- interaction with colleagues and experts across the globe
- a growing database of scientific articles and case reports
- ADA CERP-recognized credit administration



Register for  
**FREE!**

**ADA CERP**® | Continuing Education Recognition Program

ADA CERP is a service of the American Dental Association to assist dental professionals in identifying quality providers of continuing dental education. ADA CERP does not approve or endorse individual courses or instructors, nor does it imply acceptance of credit hours by boards of dentistry.





CROIXTURE

PROFESSIONAL MEDICAL COUTURE



THE NEW 2014-2015 COLLECTION

EXPERIENCE OUR ENTIRE COLLECTION ON [WWW.CROIXTURE.COM](http://WWW.CROIXTURE.COM)






Bio-Emulation™



Tribune CME



# Bio-Emulation™ Colloquium 360°

4-5 July, 2015, Berlin, Germany

## Mentors



Ed McLaren



Michel Magne



Pascal Magne

## Emulators



Akinobu Ogata (guest)



Andrea Fabianelli



Antonio Saiz-Pardo Pinos



August Bruguera



David Gerdolle



Fernando Rey



Gianfranco Politano



Jason Smithson



Javier Tapia



Jungo Endo



Leandro Pereira



Marco Gresnigt



Oliver Brix



Panos Bazos



Sascha Hein



Stephane Browet



Thomas Singh

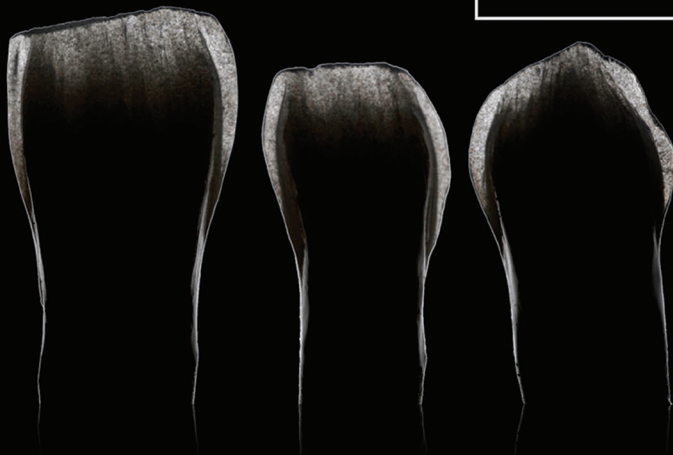

Walter Gebhard (guest)

Details & Online Registration

[www.BioEmulationCampus.com](http://www.BioEmulationCampus.com)

Registration fee: 599 EUR +VAT



**ADA CERP®**  
Continuing Education Recognition Program



Tribune Group is an ADA CERP Recognized Provider. ADA CERP is a service of the American Dental Association to assist dental professionals in identifying quality providers of continuing dental education. ADA CERP does not approve or endorse individual courses or instructors, nor does it imply acceptance of credit hours by boards of dentistry.

Tribune Group GmbH is designated as an Approved PACE Program Provider by the Academy of General Dentistry. The formal continuing dental education programs of this program provider are accepted by AGD for Fellowship, Mastership, and membership maintenance credit. Approval does not imply acceptance by a state or provincial board of dentistry or AGD endorsement.

Main Sponsor

