

CAD/CAM

international magazine of digital dentistry

1 2016



| opinion

The 3-D difference:
CBCT diagnostics to enhance treatment

| case report

Immediate screw-retained CAD/CAM
provisionalisation with an integrated digital approach

| feature

Your dental lab needs
CAD/CAM technology or else...

INSPIRATION, BUYING AND NETWORKING

- welcome to the leading annual dental fair in Scandinavia



SCANDEFA invites you to exclusively meet the Scandinavian dental market and sales partners in wonderful Copenhagen.

Why exhibit at SCANDEFA?

SCANDEFA is a leading, professional branding and sales platform for the dental industry.

In 2016 we are pleased to present Scandefafa with two fair days and a more flexible course programme at the Annual Meeting. In addition to sales, branding and customer care, the new format gives you the opportunity for networking, staff care, professional inspiration and competence development.

SCANDEFA is organised by Bella Center and held in collaboration with the Annual Meeting organised by the Danish Dental Association (tandlaegeforeningen.dk).

How to exhibit

Please book online at scandefafa.dk or contact Sales- & Exhibition Manager Mia Clement Rosenvinge mro@bellacenter.dk / +45 32 47 21 33.

Who visits SCANDEFA?

In 2015 over 7,500 dentists, dental hygienists, dental assistants and dental technicians visited SCANDEFA. For further statistical information please see scandefafa.dk

Where to stay during SCANDEFA?

Two busy fair days require a lot of energy, and therefore a good night's sleep and a delicious breakfast are a must.

We offer all of our exhibitors a special price for both our hotels, AC Hotel Bella Sky Copenhagen – Scandinavia's largest design hotel – and Hotel Crowne Plaza – one of the leading sustainable hotels in Denmark.

We also offer free and easy shuttle service transport between the airport, the two hotels and Bella Center.

SCANDEFA
SCANDINAVIAN DENTAL FAIR

28 - 29 APRIL 2016

scandefafa.dk

Dear Reader,

_Welcome to this year's first issue of **CAD/CAM** magazine! The year 2015 was very successful for us and I would like to thank our readers, authors, guest editors and supporting companies for their involvement and collaboration.

With increased media coverage on smile makeovers and dental cosmetic treatment, clinicians are often faced with the need to follow and combine CAD/CAM technology, smile design and implant restorations in their daily practice.

High-end procedures demand perfection, and perfection in dental restorations cannot be achieved without unstinted dedication, commitment and passion. For success in this field, one should try to keep abreast with the newest trends and continue to enhance knowledge of treatment options, in terms of principles, procedures, materials, and the latest techniques.

In this issue of the **CAD/CAM** magazine, you will find well-documented articles on diagnosis and treatment planning for implant dentistry, guided implant surgery, smile design software and CAD/CAM-supported aesthetic restorations, as well as new product information and events previews.

Dr Anthony Ramirez describes his experience with 3-D imaging, and Dr Christian Mertens explains principles of backward planning and digital workflow using SIMPLANT. Aki Lindén, a dental technician from Finland, presents an example of utilising smile design software and CAD/CAM for creating a mock-up and final restorations, and, in a very convincing interview, Matthew Roberts encourages dentists and dental technicians to explore the digital environment.

I hope you will enjoy reading our first issue of 2016!

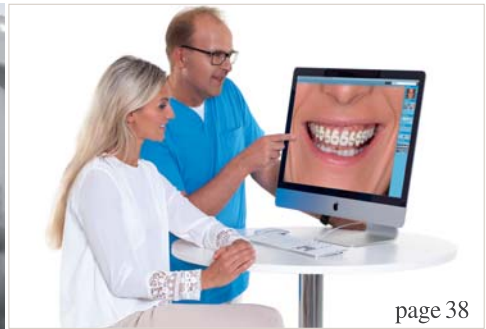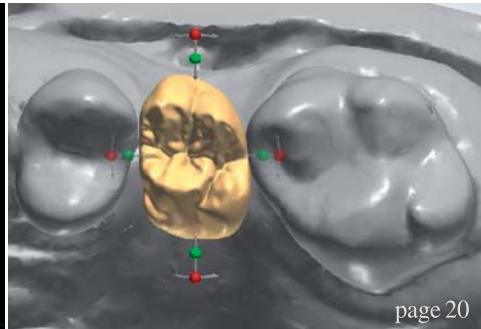
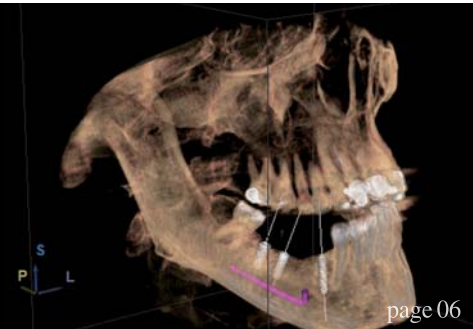
Yours faithfully,



Magda Wojtkiewicz
Managing Editor



Magda Wojtkiewicz
Managing Editor



| editorial

03 **Dear Reader**
| Magda Wojtkiewicz, Managing Editor

| opinion

06 **The 3-D difference:**
CBCT diagnostics to enhance treatment—Part 1
| Dr Anthony Ramirez

| case study

20 **Thinking backwards—digital workflow using SIMPLANT with ASTRATECH Implant System EV**
| Dr Christian Mertens

| case report

24 **Immediate screw-retained CAD/CAM provisionalisation with an integrated digital approach**
| Dr Sepehr Zarine & Jerome Vaysse

30 **Complete reconstruction for a patient with chronic tooth decay—The damage undone**
| Dr Ara Nazarian

38 **Utilising smile design software and CAD/CAM for creating a mock-up and final restorations**
| Aki Lindén

| feature

42 **Your dental lab needs CAD/CAM technology or else...**
| Interview with Matthew Roberts, founder of CMR Dental Laboratory

| industry news

46 **Straumann Original Quality label: Show that your lab does not compromise on quality and precision!**
| Straumann

48 **CAD/CAM implant bars on demand with NobelProcera Services**
| Nobel Biocare

50 **Schick Dental—innovation and premium products**
| Schick Dental

| industry events

52 **MIS Global Conference:**
Company calls for clinical case submission
| MIS

54 **Nobel Biocare Global Symposium: Where innovation comes to life**
| Nobel Biocare

| meetings

56 **International Events**

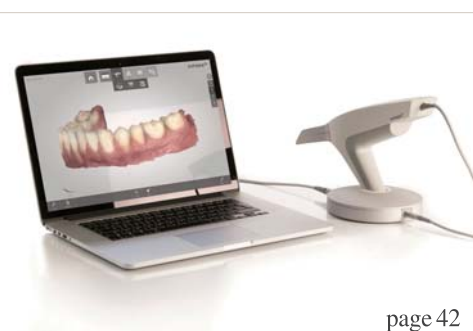| about the publisher

57 | submission guidelines

58 | imprint



Cover image courtesy of Schick Dental (www.schick-dental.de)





BARCELONA DREAM TEAM MAKE IT SIMPLE

MIS is proud to introduce the Global Conference Speakers Team: Alexander Declerck • Anas Aloum • Andrea Pilloni • Arndt Happe • Björn-Owe Aronsson • Carles Martí-pagés • Carlo P. Marinello • Christian Coachman • David García Baeza • Eduard Ferrés-padró • Eli Machtei • Eric Van Dooren • Federico Hernández Alfaro • Florian Schober • France Lambert • Gabi Chaushu • Galip Gürel • Giulio Rasperini • Guillermo J. Pradies Ramiro • Gustavo Giordani • Hilal Kuday • Ignacio Sanz Martín • José E. Maté-sánchez De Val • José Nart • Juan Arias Romero • Korkud Demirel • Lior Shapira • Marco Esposito • Mariano Sanz Alonzo • Miguel Troiano • Mirela Feraru-Bichacho • Mithridade Davarpanah • Moshe Goldstein • Nardi Casap • Nelson Carranza • Nitzan Bichacho • Nuno Sousa Dias • Pablo Galindo-Moreno • Stavros Pelekanos • Stefen Koubi • Tommie Van de Velde • Victor Clavijo • Vincent Fehmer • Yuval Jacoby. To learn more about the conference visit: www.mis-implants.com/barcelona

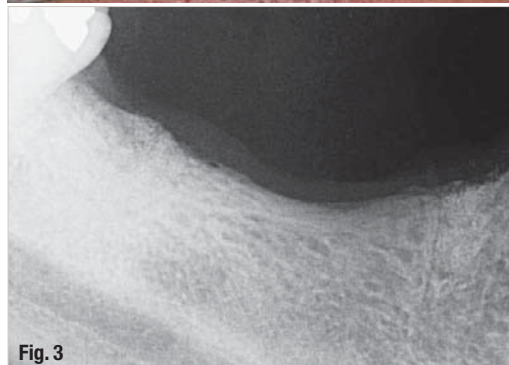
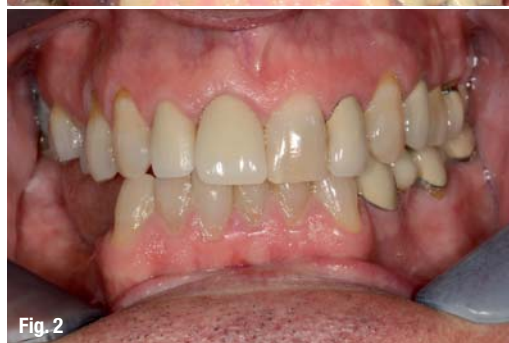
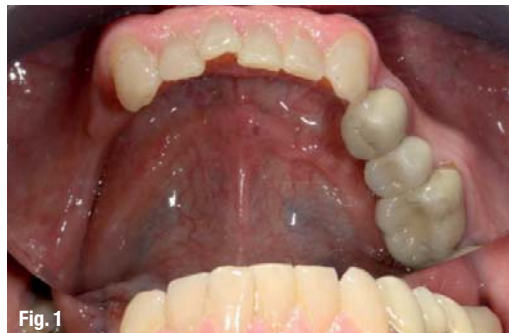
The 3-D difference: CBCT diagnostics to enhance treatment—Part 1

Author | Dr Anthony Ramirez, USA

3-D digital dentistry and the complete picture

We can't treat what we can't see. A widely used axiom in the dental imaging industry has served me well for years. Any treatment plan devised must be preceded by a proper diagnosis and 3-D imaging is the foundation for that diagnosis. The following examples I put forth will illustrate how important

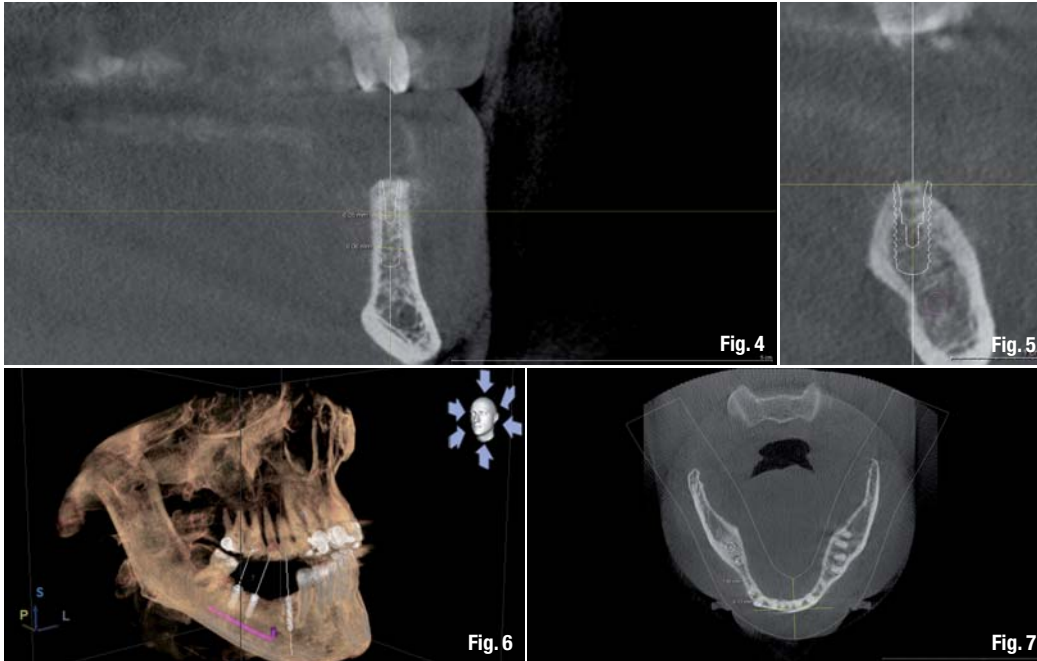


cone beam computed tomography (CBCT) is for the premier digital dental practice.

The knowledge one obtains from a CBCT data set is invaluable when constructing a proper treatment plan. My experience has been that very often a periapical X-ray does not reveal a complete picture of the patient's anatomy, and many times vital information can go overlooked and result in an incorrect diagnosis. A fundamental component of my complete dental examination is to utilize the advanced technology of CBCT to enhance my diagnostic ability and become familiar with the complete picture. I will review clinical findings, periodontal charting and a full volume of CBCT data and use my clinical and professional judgment to evaluate and formulate a customised treatment approach to solve or correct the dental problems each patient presents. Unless the patient declines a complete examination or an emergency exists (which requires immediate attention), my experience is that it is optimal to first provide a thorough diagnosis.

I marry multiple digital dental technologies—Schick 33 X-rays, Canon 6D digital camera, GALILEOS CBCT 3-D imaging and CEREC CAD/CAM—to provide a global view of the disease process and understand the maxillofacial anatomy and dentition associated with each patient's conditions.

I have incorporated the concept of Co-Diagnosis, fostering a clinical environment where my patients become part of their own dental care. The patient is responsible for their problems and we are responsible for the diagnosis and removal of disease, replacement of missing teeth, and management of their new teeth or dentition. I obtain a quick, comprehensive scan of the entire oral and maxillofacial region which I will review to customise their diagnosis and virtual treatment plan during their initial visit. Although caries as



a whole have decreased in some segments of the population, my patient population exhibit extensive dental and periodontal breakdown necessitating extensive rehabilitation to return them to oral and dental health. Many cases are exacerbated by years of dental neglect and will take the total commitment of both the patient and the dental practitioner in any effort to rehabilitate the decimated dentition. I want my patients to receive the best dental care possible and that is why I have invested in the best technology available to aid me in diagnosing and treatment planning while assisting me in providing safety and certainty during surgery.

Why I love cone beam technology

What sets my practice apart from my colleagues' is my use of GALILEOS CBCT imaging (Sirona). My GALILEOS machine is, in conjunction with my clinical assessment, all that is necessary to evaluate and treatment plan any dentition or edentulous situation. I practice at a higher diagnostic level, which I use to return my patients to optimal dental health and improve the quality of their lives.

With this state-of-the-art 3-D imaging technology I can identify, reveal and propose a treatment plan and treat my patients efficiently and effectively. With these images I can see vital anatomical structures without distortions in real dimensions, which improves my diagnostic ability, surgical planning and patient communication. I will use the results of CBCT imaging to confirm or alter my prescribed treatment.

Digital dental technologies

I have utilised GALILEOS CBCT imaging on a daily basis since it arrived in my office in March 2009. A streamlined digital workflow gives me the ability to access my patients' anatomy, identify vital structures, reveal unseen pathology, analyse bone volume and bone density and place realistic virtual implants and abutments. The result is that I provide the optimal treatment plan customised for each patient. Practicing with the benefit of GALILEOS CBCT technology, patients have come to understand their problems quickly thanks to the dynamic interaction that 3-D imaging and the GALAXIS software has afforded me. Do not underestimate this technology as it is an important communication tool which facilitates patient education, improves diagnosis and treatment planning and increases case acceptance.

This manuscript will illustrate the distinct advantages of 3-D imaging versus 2-D imaging. CBCT views allow me to interpret maxillofacial anatomy in a superior approach that is not possible with the 2-D periapical or panoramic radiographs. Pathologies are revealed in the three-dimension making a correct diagnosis possible.

Better clinical decisions are the result of having a complete set of data in real dimensions available to the practitioner. I would like to show you how I utilize 3-D imaging on my patients to diagnose and treat various conditions that existed. I am always more confident that my definitive diagnosis will be proper when I diagnose from a CBCT volume of data.

The examples presented will clearly display the powerful advantages that 3-D images give the clinician and in my opinion they cannot be underestimated when diagnosing oral and maxillofacial disease. Patients are better informed and better educated with CBCT imaging and a visual presentation with virtual implants in the patients' own anatomy increases case acceptance. I rely on 3-D technology to plan and place safe, precise implants. With the benefit of CBCT imaging I have been able to expand the scope of services I provide and increased the geographic reach giving our patients access to the advanced technologies and producing optimal treatment outcomes.

I have become proficient in Guided Bone Regeneration, Computer Assisted Guided Implant Surgery and, along with CEREC CAD/CAM technology, gained complete control over the prosthetic replacement of missing teeth. Restoring implants have been a part of my practice since 2000 but I added the surgical phase of treatment in 2009 with the purchase of my GALILEOS in-office CBCT unit.

I do treatment planning and treatment differently since implementing the use of these technologies and this shift in approach has resulted in positive patient experiences. Patients benefited with correct diagnosis and treatment plans with safer, less invasive treatment experiences. I have grown to greatly appreciate the powerful tool that CBCT imaging is and its impact on my practice.

CBCT and the 3-D difference advance the multifactorial approach to treating the decimated dental patient. I have been fortunate to invest in my patients' and my personal wellbeing as an early

adopter of the use of 3-D imaging. Each member of our team brings a unique skill set and we provide a level of care unmatched in the traditional dental practice.

When constructing a treatment plan it is imperative to interview the patient to verify their desires as opposed to their needs. I will educate while obtaining informed consent and thoroughly assess all risk factors that could impact the treatment outcome. Psychological evaluation for unrealistic expectations and the ability to comprehend their existing condition and what is necessary to improve their dentition can impact whether or not to treat the patient. The imaging and interview will help me decide whether or not I accept the case for treatment. I make each patient my first priority and spend as much time as necessary to explain findings, present options and answer any questions.

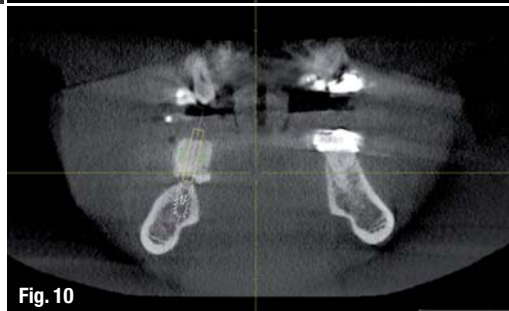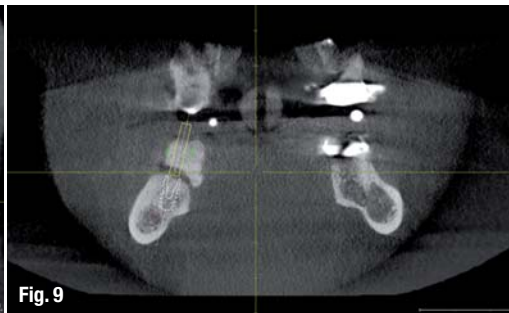
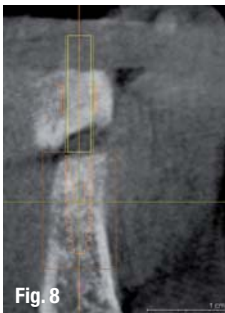
The following cases are examples that clearly illustrate the 3-D difference and how this technology can benefit all dental practices. What is significant is that prior to obtaining an in office GALILEOS CBCT scanner I did not have the confidence to provide these services in my office and had to refer these cases to specialists.

Case 1—The reluctant patient

This case is an example of a case that I would have been foolish to treat without the benefit of 3-D imaging and would have placed an unnecessary risk of injury to the patient due to the anatomical limitations present and the desires of this patient. A 52-year-old male patient, presented to my office for an implant consultation on the 5th of November 2013. He was in good health and his medical history revealed he has controlled hypertension. There were no contraindications for dental treatment.

Patient made it clear that he would like to replace multiple missing teeth in a fixed manner only but he is very anxious about having dental surgery to replace these four missing lower right quadrant teeth. His last dental treatment was for the removal of tooth #27 (over 6 months before) and concomitant bone graft to preserve alveolar ridge and prepare for its replacement. In addition he was reluctant to be 'knocked out' to facilitate any surgery and declined additional bone grafting procedures.

We began by completing the conventional clinical and radiographic examination. Clinically his ridge appeared narrow in the area of tooth #28 and #29, but crestal tissue was keratinised (Figs. 1–3). The patient travelled well over an hour to visit our



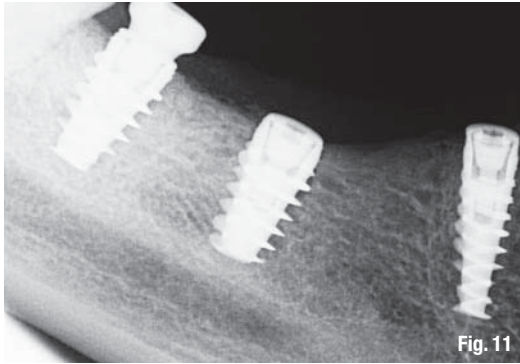


Fig. 11

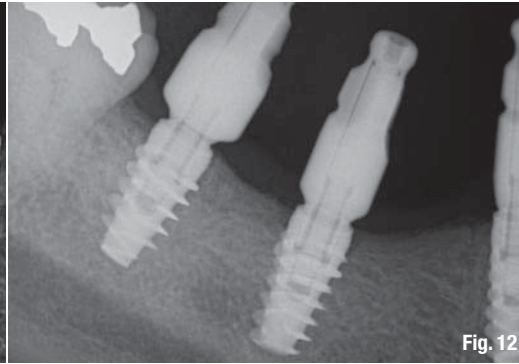


Fig. 12




Fig. 13

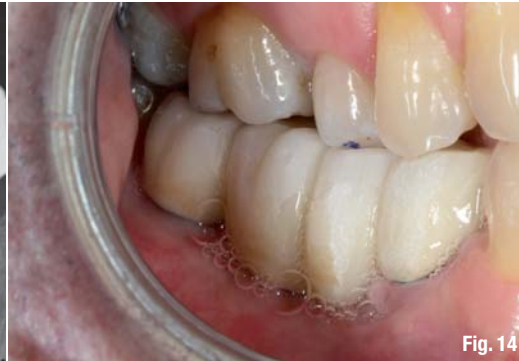

Fig. 14

office and he was aware that we are a proponent of performing flapless guided implant surgery when possible. I explained the benefits and risks associated with this type of implant surgery. The advantages include fast, safe, accurate implant placement with a minimally complicated post-op healing period. Digital 2-D periapical X-rays taken were limited in their diagnostic value. There was no way to be certain as to the exact location of the inferior alveolar nerve or the lingual concavity in the molar area. With that in mind we discussed, and he agreed to accept a CBCT scan to fully evaluate his current condition and determine if enough bone volume existed to perform a guided implant surgery.

This is where my in office CBCT unit becomes invaluable as the information cannot be obtained by any other in office radiographic modality. A medical CT could be requested which exposes the patient to a much larger dose of radiation and could only be taken at a different imaging center. Obviously I could not treat the patient if the existing bone anatomy was deficient and could not accept a properly positioned root form dental implant in solid bone. He was thinking that he could replace four teeth with two implants and a bridge. But that was not appropriate due to the large mesial distal edentulous span of missing teeth. The crest in the area of tooth #29 and #30 exhibited height and labial bone loss. Due to his occlusion, number of missing teeth and the position in the lower right dental arch, I felt it would be necessary to place a minimum of three fixtures to retain a 4-unit fixed bridge.

Capturing 3-D anatomy

Sirona's GALILEOS scan travels around the patients' head in a single revolution that takes 14 seconds to complete the capture of the maxillo-facial anatomy and a full volume of data is reconstructed and becomes available to assess within minutes. My patient and I reviewed the 3-D images together on a large computer monitor in my conference room. I was able to place three virtual implants into the residual bone avoiding the IAN, mental foramen and lingual concavity. Patient could clearly visualise this procedure being performed in his jaw. In this case the bone appeared adequate to receive 3 endosseous implants that could be restored with a 4 unit fixed bridge (Figs. 4-7). So to recap, this patient was reluctant to be treated with conventional flapped implant surgery and declined additional bone grafting to improve any bone volume, but was a candidate for flapless or minimally flapped guided implant surgery which gave him the confidence to accept treatment based upon our initial consultation and treatment plan which was developed during this visit. This first step is essential to gain the patient's trust and gain acceptance to the treatment plan at his initial visit as he would not return to us if he wasn't convinced that I could perform his treatment as I described and under local anesthesia and without further bone grafting.

In preparation for guided implant surgery it is necessary to fabricate a computer generated surgical guide based upon the restoratively driven