

July-August 2016 | No. 4, Vol. 6

► Insertion

► Insertion

► Insertion

► Insertion

► Insertion

Dentistry and dental technology delivered with passion

Robert Ganley, CEO of Ivoclar Vivadent AG,

underlined his desire to advance dentistry through intense dialogue. Sonia Gómara, Managing Director of the company's subsidiary for the Iberian Peninsula, was delighted to provide the attendees with an opportunity to get to know the work of some of the world's most renowned dental experts.

Several speeches revolved around minimally invasive treatment options: Dentists talked



Opening speech by Robert Ganley, CEO Ivoclar Vivadent AG

about outcome-oriented approaches to preparation and impression-taking methods using trays and intraoral scanning devices. Dental technicians discussed the effects of limited oral

space on their choice of materials and procedures. Adhesive cementation came to the fore

►Page 29



AMD LASERS®
EFFECTIVE. PRACTICAL. AFFORDABLE. **WORLD CLASS LASERS.**

#1 Lasers in the World



NEW! Picassolite+

NEW! Picasso+



GLOBE
step into the future

GLOBE
ADDRESS: 11, EL OBOUR BUILDINGS,
OROUBA AV. HOLIOPOLIS, CAIRO, EGYPT
TELEFAX: +2024045621 - +2024010579
MOB: +2 01000 99 6265
WEBSITE: WWW.GLOBEEGYPT.NET
EMAIL: INFO@GLOBEEGYPT.NET



TAMER DROGUERIE

TAMER DROGUERIE
ADDRESS: BEIRUT-LEBANON
WEBSITE: WWW.TAMERHOLDING.COM
E-MAIL: DENTAL@TAMERHOLDING.COM
PHONE: 961.1.694 000
FAX: 961.1.694 777



دبي للمعدات الطبية ذ.م.ك.
Dubai Medical Equipment L.L.C.

DUBAI MEDICAL EQUIPMENT
UNITED ARAB EMIRATES
TEL. NO: +971 6 5308055
FAX NO: +971 6 5308077
MOB : +971 50 7370011
MOB : +971 55 4417490
DT_UAE@EMIRATES.NET.AE






866.999.2635 AMDLASERS.COM

Most sugar-free chewing gums in Middle East lack clear labelling on xylitol

By DTI

KUWAIT CITY, KUWAIT: The majority of sugar-free chewing gums containing xylitol that are sold in the Cooperation Council for the Arab States of the Gulf (GCC) countries do not have clear labelling regarding xylitol content, a new study has found. According to the researchers, the product labels mention neither the recommended daily dose of xylitol for caries prevention nor the actual amount of xylitol the chewing gum contains. They also found that the majority of gums do not provide the necessary amount of xylitol for caries prevention.

The aim of the study, conducted by Dr Abrar al-Anzi, assistant profes-

sor at the Department of Developmental and Preventive Sciences of the Faculty of Dentistry at Kuwait University and her colleagues, was to identify sugar-free chewing gums available in the GCC region that provide the recommended daily dose of xylitol for the prevention of dental caries.

The daily dose recommended by various dental associations around the world ranges between 3 and 10 g of xylitol, available in the form of gums or lozenges, three to seven times a day. Taken regularly, xylitol can contribute to the prevention of caries by inhibiting the growth of *Streptococcus mutans*, one of the main bacteria associated with tooth decay. Moreover, the sugar substi-

tute has been found to enhance remineralisation and reduce the quantity of dental plaque, as most plaque bacteria are not able to ferment xylitol into cariogenic end-products.

The researchers examined the concentration of xylitol in 21 brands of chewing gum (from Kuwait, Bahrain, Qatar, Saudi Arabia, the UAE and Oman), using a special enzymatic kit. They found a xylitol content of less than 0.3 g per piece of gum in nine products, of 0.3–0.5 g in seven and of more than 0.5 g in five products. According to the scientists, the majority of gums analysed did not provide the necessary amount of xylitol for caries prevention.

Moreover, most of the products tested lacked accurate label-

ling regarding their xylitol content. Of the 21 brands, only one clearly mentioned the amount of xylitol in grams on its label. Twelve products stated the percentage of xylitol (3.5–35 per cent). The rest did not specify the amount.

"Looking at the percentage, it is not easy for the consumer to calculate the actual amount of xylitol in grams. A consumer should be informed of the contents and the amount used in the product so that he can make an informed decision," al-Anzi told the Middle Eastern newspaper Muscat Daily.

The researchers have therefore recommended clear, accurate labelling of all xylitol-containing gums sold in the GCC countries and advised dental associations in the Middle Eastern region to adopt the general recommendations for labelling of current xylitol products.

The study, titled "Xylitol chewing gums on the market: Do they prevent caries?", was published online in the Oral Health and Preventive Dentistry journal on 12 May. [DTI](#)

IMPRINT

GROUP EDITOR
Daniel ZIMMERMANN
newsroom@dental-tribune.com
Tel.: +44 161 223 1830

CLINICAL EDITOR
Magda WOJTKIEWICZ

ONLINE EDITOR
SOCIAL MEDIA MANAGER
Claudia DUSCHKE

EDITORIAL ASSISTANTS
Anne FAULMANN
Kristin HÜBNER

COPY EDITORS
Sabrina RAAFF
Hans MOTSCHMANN

PUBLISHER/PRESIDENT/CEO
Torsten OEMUS

CHIEF FINANCIAL OFFICER
Dan WUNDERLICH

CHIEF TECHNOLOGY OFFICER
Serban VERES

BUSINESS DEVELOPMENT MANAGER
Claudia SALWICZEK-MAJONEK

JUNIOR MANAGER BUSINESS DEVELOPMENT
Sarah SCHUBERT

PROJECT MANAGER ONLINE
Tom CARVALHO

EVENT MANAGER
Lars HOFFMANN

EDUCATION MANAGER
Christiane FERRET

INTERNATIONAL PR & PROJECT MANAGER
Marc CHALUPSKY

MARKETING & SALES SERVICES
Nicole ANDRA

EVENT SERVICES
Esther WODARSKI

ACCOUNTING SERVICES
Karen HAMATSCHEK
Anja MAYWALD
Manuela HUNGER

MEDIA SALES MANAGERS
Matthias DIESSNER (Key Accounts)
Melissa BROWN (International)
Antje KAHNT (International)
Peter WITTECZEK (Asia Pacific)
Weridiana MAGESWKI (Latin America)
Maria KAISER (USA)
Hélène CARPENTIER (Europe)
Barbora SOLAROVA (Eastern Europe)

EXECUTIVE PRODUCER
Gernot MEYER

ADVERTISING DISPOSITION
Marius MEZGER

DENTAL TRIBUNE INTERNATIONAL
Holbeinstr. 29, 04229 Leipzig, Germany
Tel.: +49 341 48 474 302
Fax: +49 341 48 474 173
www.dental-tribune.com
info@dental-tribune.com

DENTAL TRIBUNE ASIA PACIFIC LTD.
Room A, 20/F
Harvard Commercial Building
105–111 Thomson Road, Wanchai, HK
Tel.: +852 3113 6177
Fax: +852 3113 6199

THE AMERICA, LLC
116 West 23rd Street, Ste. 500, New York
N.Y. 10011, USA
Tel.: +1 212 244 7181
Fax: +1 212 244 7185

DENTAL TRIBUNE MEA EDITION EDITORIAL BOARD
Dr. Aisha SULTAN ALSUWAIDI, UAE
Dr. Ninette BANDAY, UAE
Dr. Nabeel HUMOOD ALSABEEHA, UAE
Dr. Mohammad AL-OBAIDA, KSA
Dr. Meshari F. ALOTAIBI, KSA
Dr. Jasim M. AL-SAEEDI, Oman
Dr. Mohammed AL-DARWISH, Qatar
Prof. Khaled BALTO, KSA
Dr. Dobrina MOLLOVA, UAE
Dr. Munir SILWADI, UAE
Dr. Khaled ABOUSEADA, KSA
Dr. Rabiha ABI NADER, UAE
Dr. George SANOOP, UAE
Dr. Olivier CARCUAC, UAE
Dr. Ehab Heikal, Egypt
Aiham FARRAH, CDT, UAE
Retty M. MATTHEW, UAE

PARTNERS
Emirates Dental Society
Saudi Dental Society
Lebanese Dental Association
Qatar Dental Society
Oman Dental Society

DIRECTOR OF mCME
Dr. Dobrina Mollova
mollova@dental-tribune.me
Tel.: +971 50 42 43072

DIRECTOR
Tzvetan Deyanov
deyanov@dental-tribune.me
Tel.: +971 55 11 28 581

DESIGNER
Kinga Romik
k.romik@dental-tribune.me

PRINTING HOUSE & DISTRIBUTION
Al Nisr Printing
P.O. Box 6519, Dubai, UAE
800 4585/04-4067170

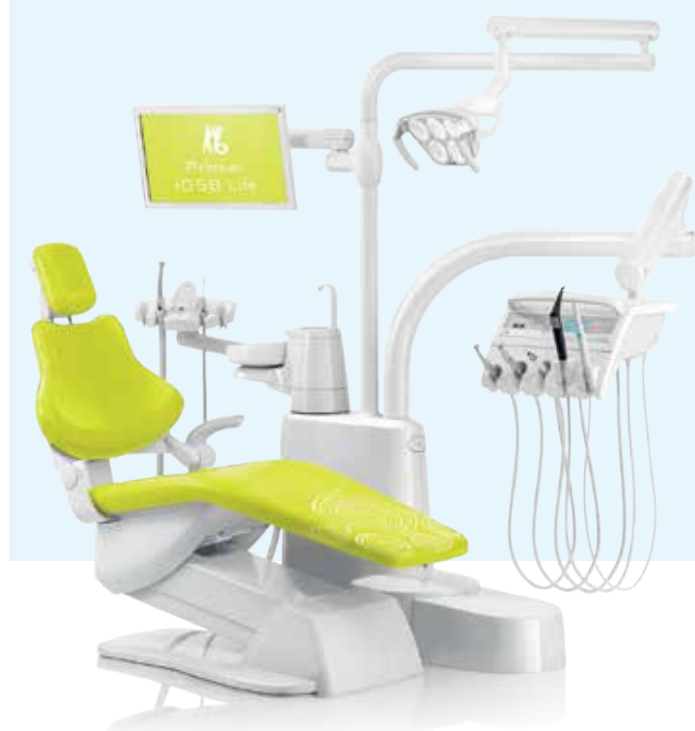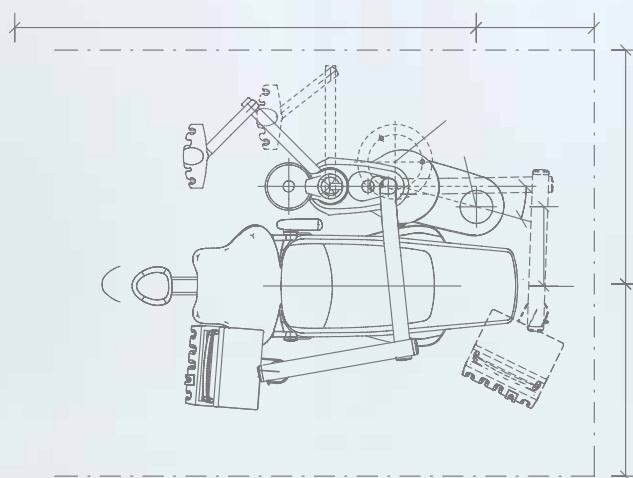
KaVo Primus™ 1058 Life



Andreas Schweiger,
Director Research and Development

Designed with passion.
Engineered with precision.
Built with perfection.

Discover the new Primus 1058 Life



The Primus 1058 has been the synonym for quality and reliability in the dental world for over 15 years. Consequently, our development team has passionately designed the new Primus 1058 Life around these core values whilst adding a significant number of improvements and innovations including:

- NEW intuitive dentist element
- NEW optimised ergonomics
- NEW contemporary design
- NEW AC chair motor

For More Information:
go.kavo.com/MEA



KaVo. Dental Excellence.

KaVo Dental GmbH · D 88400 Biberach/Riß · Telephone +49 7351 56-0 · Fax +49 7351 56-1488 · www.kavo.com

SMALL CHANGE. BIG DIFFERENCE.

The new imaging plate scanner XIOS Scan completes the intraoral family from Sirona. Whether you're taking the first steps into the digital world or establishing or updating a fully digital practice, XIOS Scan and XIOS XG Sensors offer perfectly synchronized solutions for every workflow. **Enjoy every day. With Sirona.**



THE NEW
IMAGING PLATE
SCANNER:
XIOS Scan

SIRONA.COM

The Dental Company

sirona.

Esthetic replacement of anterior class IV restorations

By Dr. Paulo Monteiro, Portugal

Initial Situation

Female patient 30 years old. Patient was not satisfied with current anterior restorations (maxillary central incisors). Patient also expressed dissatisfaction with shade and surface texture.

Challenge

Creating smooth and natural-looking restorations for patients who demand the highest level of esthetics can be challenging. Using materials that mimic shade and opacity of dentin and enamel is critical. ^{DT}



Dr. Paulo Monteiro obtained his degree as a Doctor of Dental Medicine at the Instituto Superior de Ciências da Saúde-Sul and his Master's Degree in Dental Medicine at the Instituto Superior de Ciências da Saúde Egas Moniz (ISCSEM) in Caparica, Portugal. He completed his specialization in Esthetic and Restorative Dentistry at the ISCSEM and obtained a Master's degree in Dental Medicine. Presently he is an Assistant Professor at ISCSEM for the Aesthetic and Restorative Dentistry Post-graduation program and for the Oral Rehabilitation Department at ISCSEM. He is also involved in research of new dental materials, including composite resins, dental adhesives, dental ceramics and new technologies.

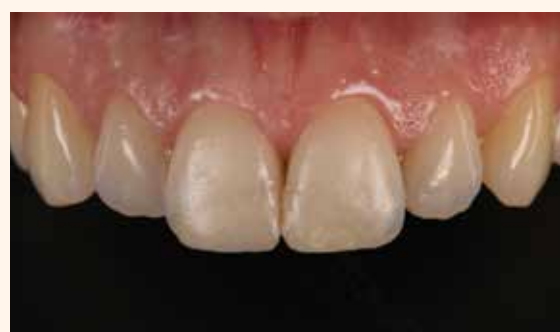

Fig. 1: Initial situation: patient was not satisfied with current restorations.

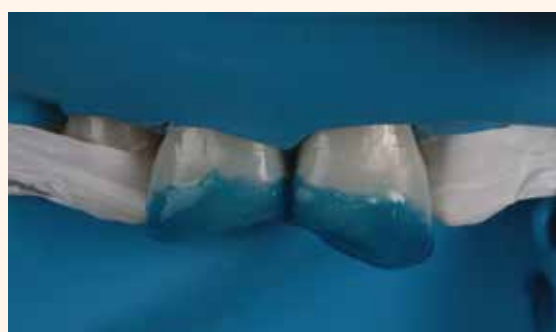

Fig. 2: Teeth were etched after preparation using Single Bond Universal Etchant.

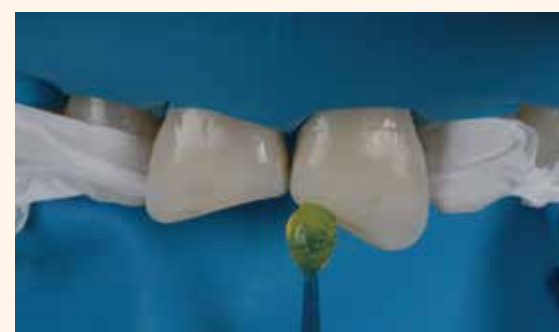

Fig. 3: Single Bond Universal Adhesive is scrubbed into the surface, air dried and light cured with Elipar™ DeepCure-S LED Curing Light.

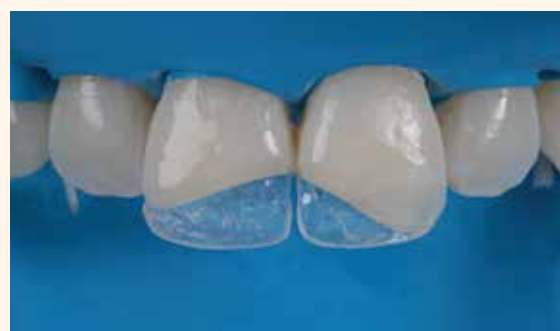

Fig. 4: A silicone matrix was used to create the palatal wall with Filtek™ Z350XT Universal Restorative, shade CT.

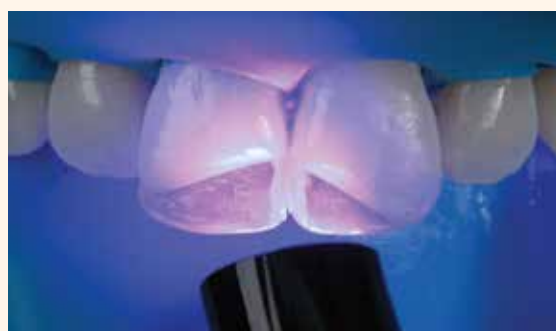

Fig. 5: The interproximal enamel layer was built with Filtek™ Z350XT Universal Restorative, shade A3E and light cured with Elipar™ DeepCure-S LED Curing Light. For the incisal halo, Filtek™ Z350XT Flowable Restorative, shade W was used.

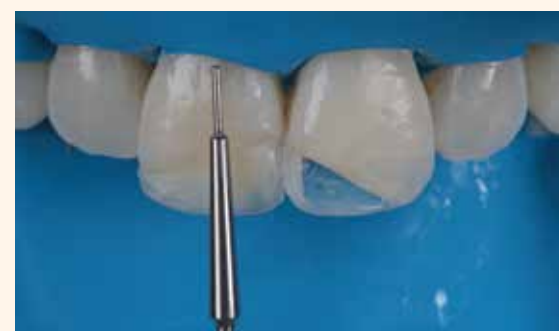

Fig. 6: Application of the dentin layer using Filtek™ Z350XT Universal Restorative, shade A1D. For volume control the Misura instrument (LM Arte by Style Italiano) was used to leave a 0.5mm space for the facial enamel.

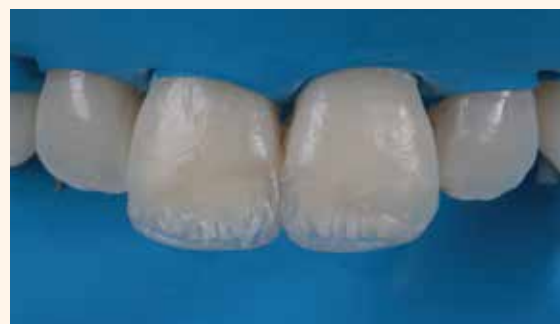

Fig. 7: Creation of mamelons and application of a small portion of Filtek™ Z350XT Universal Restorative, shade CT between the dentin layer and incisal halo to enhance translucency at the incisal edge.

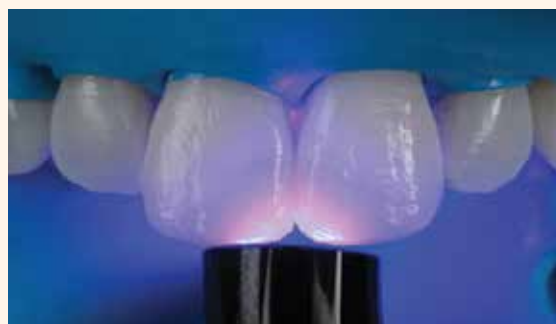

Fig. 8: The final enamel layer of Filtek™ Z350XT Universal Restorative, shade A3E was applied and light cured.

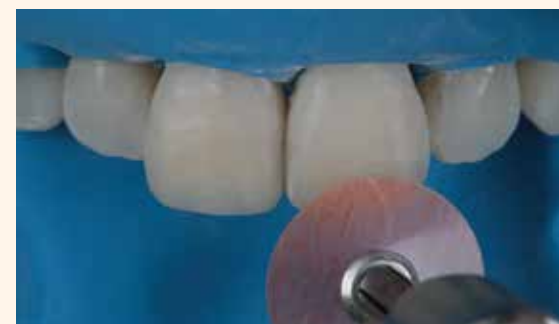

Fig. 9: Sof-Lex™ Discs are used to define the outline of the restoration and create secondary anatomy

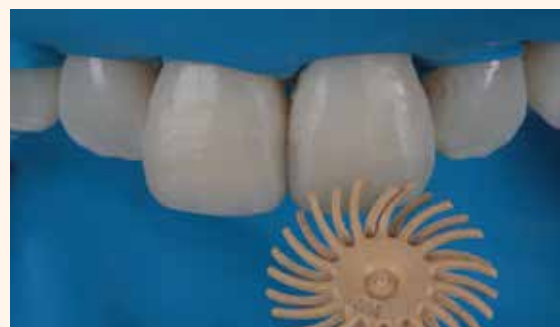

Fig. 10: Pre-polishing of restoration with Sof-Lex™ Pre-Polishing Spiral.

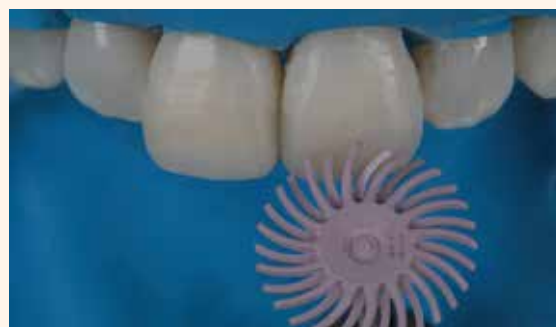

Fig. 11: Polishing with Sof-Lex™ Diamond Polishing Spiral to create a final smooth and high-gloss polish.

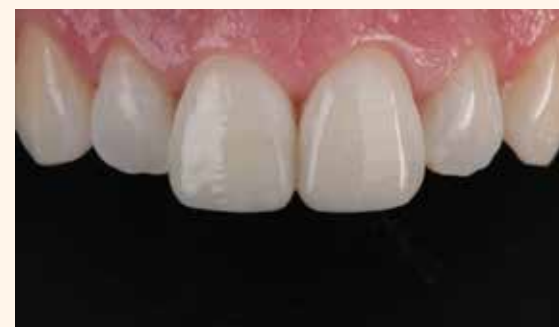

Fig. 12: Final restoration is very natural-looking.

Legacy of Innovation Continues for 3M Oral Care

The Anaheim Group acknowledges 3M's contributions to the dental industry for an 11th consecutive year

By 3M ESPE

With 95 innovations launched in 2015, 3M's designation as the Most Innovative Company in the Dental Industry was earned through a relentless commitment to science-based innovation. Honored with its 11th consecutive win, 3M's rank on The Anaheim Group's "Innovation Index" has once again placed the

company in the top spot with 25 percent more innovations than any other dental company.

The Anaheim Group's index combines the number of EC/WIPO patents, U.S. patents and U.S. 510(k) clearances, and is the dental industry's best measure of overall technical strength and capability.

With its commitment to improving lives through science, 3M continues to improve on its own innovations. The maker of countless award-winning products under such brands as Filtek™, RelyX™ and Scotchbond™, 3M's breakthrough innovations are often sourced from within its own walls. Interdisciplinary collaborations have inspired many of 3M's greatest innovations in the dental

industry, including pioneering the use of zirconia restorative materials and introducing nanotechnology for enhanced esthetics and strength in universal restorative material.

"Receiving the Most Innovative honor for more than a decade is a testament to what 3M excels at—applying science to help keep people healthy," said James D. Ingebrand, vice presi-

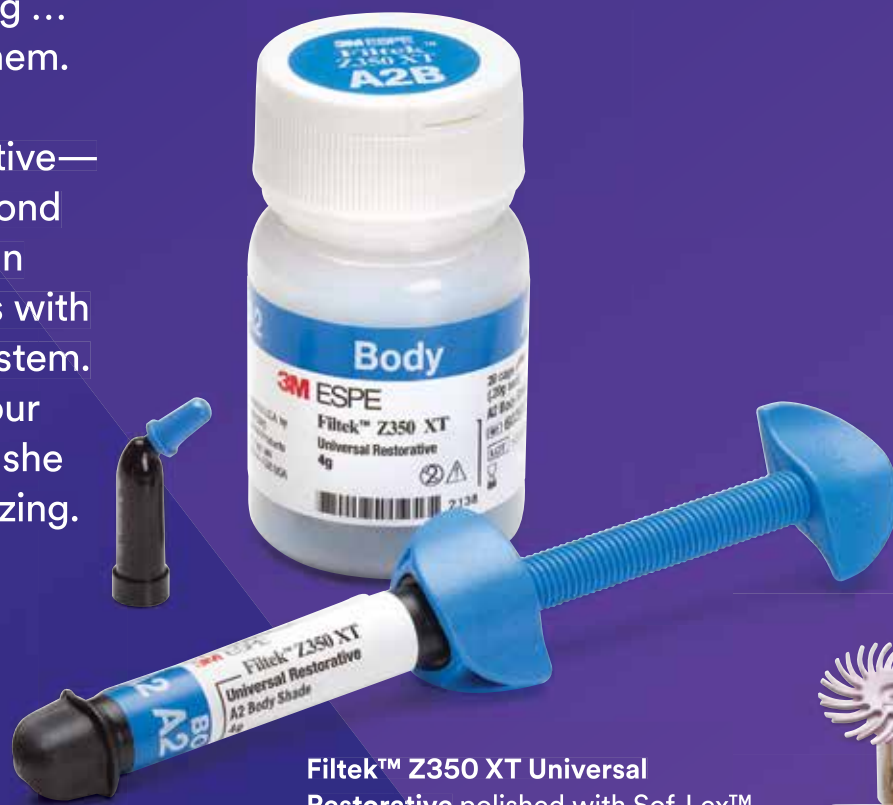
dent & general manager, Oral Care Solutions Division of 3M. "Every day, we explore new ways to impact lives, as we consistently pursue new product and process innovations with a focus on promoting lifelong oral health for all.

To learn more about 3M, visit www.3MGulf.com/espe ^{DT}

A beautiful smile she can't wait to share.

There are things in life worth sharing ... and now, her smile can be one of them. Restore with beautifully strong Filtek™ Z350 XT Universal Restorative—and polish with the Sof-Lex™ Diamond Polishing System. Together, they can produce a diamond paste-like gloss with the convenience of a rubberized system. Oh, don't be surprised if word of your great work gets around ... because she shares everything she thinks is amazing.

www.3MGulf.com/espe



Filtek™ Z350 XT Universal Restorative polished with Sof-Lex™ Diamond Polishing System (left) vs. TPH Spectra® Universal Composite polished with Enhance® Finishing System and PoGo® Polishing System (right).

Red & White Aesthetic Harmony

By Shofu

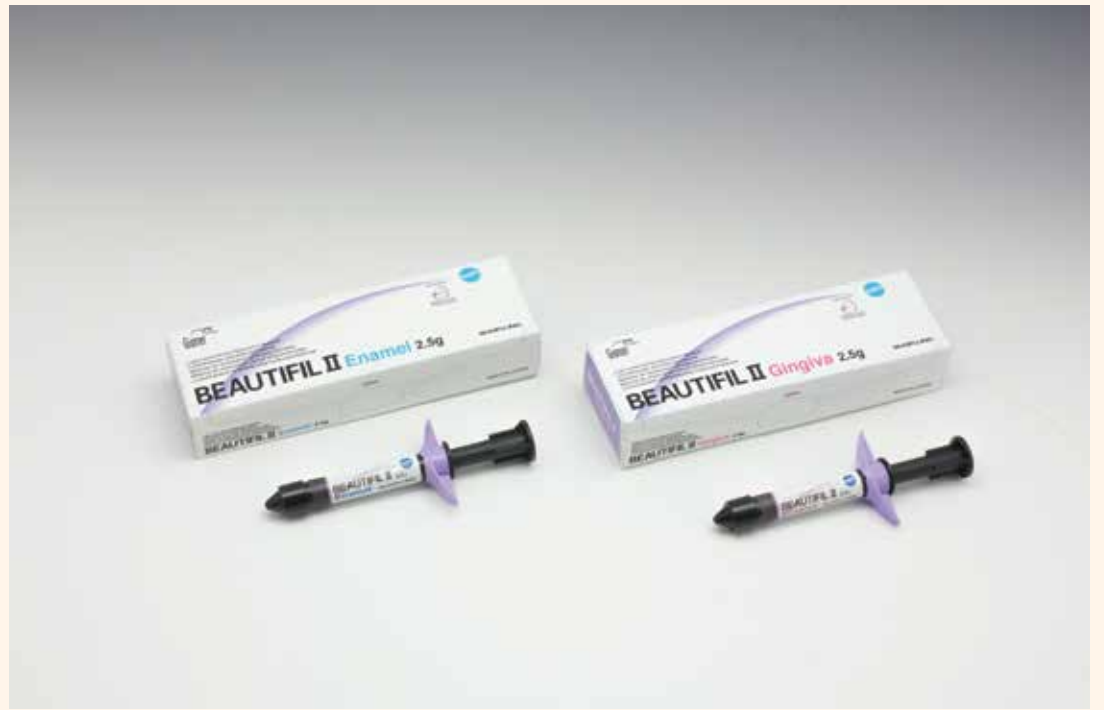Beautifil II Enamel and GINGIVA from Shofu are developed as a complementary line extension of Beautifil II to create life-like direct resin restorations. A special one-push syringe ensures controlled dispensing of the smooth and creamy material that is easy to sculpt into fine details and recreate the surface textures seen in natural teeth & gum.

Inclusion specially modified multi-functional organic fillers and nano-fillers impart Beautifil II Enamel and Gingiva with exceptional handling characteristics, longer working time, high abrasion/wear resistance, stable shades, effortless and superior polish with sustained polish retention for lasting aesthetics. Shofu's proprietary S-PRG fillers offer additional fluoride benefits and anti-plaque effect on the restoration surface.

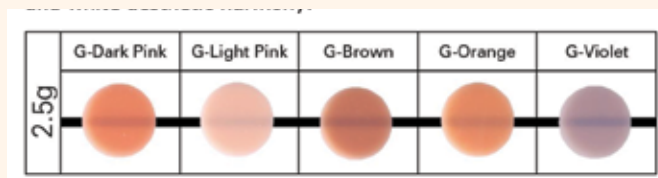
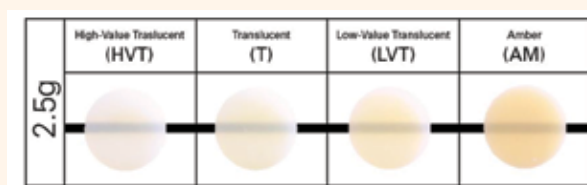
Beautifil II Enamel is available in 4 naturally translucent and opalescent shades that facilitate life-like shade

reproduction and value adjustment in the final restoration to meet individual clinical needs.

Beautifil II GINGIVA is available in 5 natural shade variations of pink to easily mimic patient's individual gum while restoring areas with receded or missing gums/papilla, cervical defects, root caries/erosion, exposed PFM margins and abutments to achieve red and white aesthetic harmony. **DTI**



Beautifil II Enamel and GINGIVA



TRIOS scans most accurate and consistent



3Shape's intra-oral scanner TRIOS delivered the most accurate results when compared with other leading scanning systems in a recent study. (Photograph: 3Shape)

By DTI

BALTIMORE, USA/FREIBURG, Germany: A new study evaluating the accuracy of six leading intra-oral scanners in the dental market has found 3Shape's TRIOS to be both the most accurate and consistent performer of the scanners tested.

The study, which was conducted jointly by the University of Maryland in Baltimore and the University of Freiburg in Germany, aimed to compare the ability of intra-oral scanning systems of different brands to accurately scan a single molar abutment tooth in vitro. The analyses included the following six scanners: iTero (Align Technology), 3M True Definition (3M ESPE), PlanScan (Planmeca), CS 3500 (Carestream Dental), TRIOS and CEREC AC Omnicam (Sirona Dental Systems).

In order to compare the accuracy of each system, the investigators used an industrial-grade, highly accurate reference scanner to create a digital reference dataset for an acrylic dental model. A single trained, experienced dentist then scanned the acrylic model on three separate occasions using each of the six intra-oral scanning systems.

Trueness (accuracy) was defined by superimposing the three digital datasets over the reference dataset, with 3-D comparisons then performed. Precision (consistency) was defined by superimposing each dataset over the other two datasets obtained and then evaluating for 3-D deviations.

Of the 18 datasets analysed, the smallest deviations for the trueness measurements (\pm standard deviation) between the reference dataset and the various intra-oral scanner datasets were obtained from TRIOS ($6.9 \pm 0.9 \mu\text{m}$), followed by CS 3500 ($9.8 \pm 0.8 \mu\text{m}$), iTero ($9.8 \pm 2.5 \mu\text{m}$), 3M True Definition ($10.3 \pm 0.9 \mu\text{m}$), PlanScan ($30.9 \pm 10.8 \mu\text{m}$) and CEREC AC Omnicam ($45.2 \pm 17.1 \mu\text{m}$).

As for precision values, here too 3Shape's TRIOS was identified as the most accurate ($4.5 \pm 0.9 \mu\text{m}$), followed by 3M True Definition ($6.1 \pm 1.0 \mu\text{m}$), iTero ($7.0 \pm 1.4 \mu\text{m}$), CS 3500 ($7.2 \pm 1.7 \mu\text{m}$), CEREC AC Omnicam ($16.2 \pm 4.0 \mu\text{m}$), and PlanScan ($26.4 \pm 5.0 \mu\text{m}$).

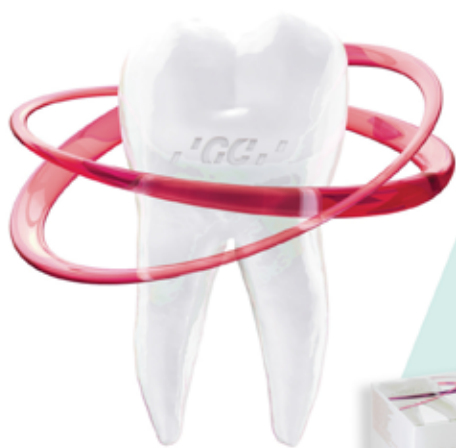"The TRIOS scanning technology, in combination with the wand design, seems to be beneficial for capturing high quality datasets with excellent trueness and precision values," the investigators said.

However, the results obtained do not provide any information about the quality of a fabricated restoration based on these digital datasets, the researchers stressed. Moreover, in an in vivo design, the outcomes might be different owing to the presence of blood, saliva, and patient movements, they concluded.

The study, titled "Evaluation of the accuracy of six intraoral scanning devices: An in-vitro investigation", was published in Volume 10, Issue 4, of the ADA Professional Product Review. **DTI**

The glass hybrid revolution

EQUIA
FORTE



EQUIA Forte
from GC

Easy and quick to use.
Wet-field compatibility.
High flexural strength,
outstanding resistance to wear
& acid erosion.
High Fluoride release at interface
and over time with recharge.
No post-operative sensitivity



GC



DUBAI
MEDICAL
EQUIPMENT
www.dme-medical.com
+971-6-5308055

SIDEXIS 4 update gives users many new functions and technical improvements

By Dentsply Sirona

Improving performance, integrating SICAT Suite or connecting an external camera: the software update gives users many new functions. With a new SQL server, compatibility with Windows 10 and other operating systems, the technical functions have also been expanded.

At the end of last year, the SIDEXIS 4 imaging software received the internationally renowned Red Dot Award Best of the Best in the "Communication Design" category for its outstanding user friendliness. The new 4.1.3 software update from Dentsply Sirona Imaging now combines additional functions for users with technical modifications that

further optimize the practice workflow. Especially in combination with the ORTHOPHOS SL, the SIDEXIS 4 software forms a highly functional and efficient unit. The update also offers advantages for networking with practice management systems and implantology planning or orthodontic analysis programs.

New functions make it easier to use

The software update now makes it possible to connect intraoral cameras from other manufacturers, as well as via Windows Driver Model. When imported images without an imaging date are provided, the user can enter the information manually to have the images displayed chronologically in the timeline. The user is provided with a complete patient history from all intraoral, panoramic, and 3D X-rays, digital camera images, and face scan data. The update also provides additional image information: The anatomical region and external image type are displayed for every image. To facilitate work for users, it will now be possible to use copy and paste to insert images into another application, such as image processing or patient management. The program also allows images to be moved retroactively to allocate them to another patient.

No more switching between SICAT Suite applications

The integration of the SICAT Suite software package with the SICAT Function and SICAT AIR applications into the SIDEXIS 4 interface represents a considerable added value for users. SICAT Function allows the three-dimensional visualization of

jaw movements for the diagnosis and treatment of craniomandibular dysfunction (CMD). Users can use SICAT Air to order protrusion appliances to treat obstructive sleep apnea. Planning data created by the two software applications are displayed in the timeline and from there can be opened again directly in the SICAT Suite. The package is integrated into the phase bar of SIDEXIS 4 with its own "Plan&Treat Phase." The applications can therefore be selected directly and treatment planning can be started. The loading times for the required 3D image data were reduced by 50 percent.

SIDEXIS 4 – state-of-the-art technology

The technical aspects of the SIDEXIS 4.1.3 software version were expanded to Windows 10 and other operating systems. Instead of the previously used SQL Server 2008 R2 database managing system, the SQL Server 2014 is now installed both during initial installation of SIDEXIS 4 and in the case of an update. [DT](#)

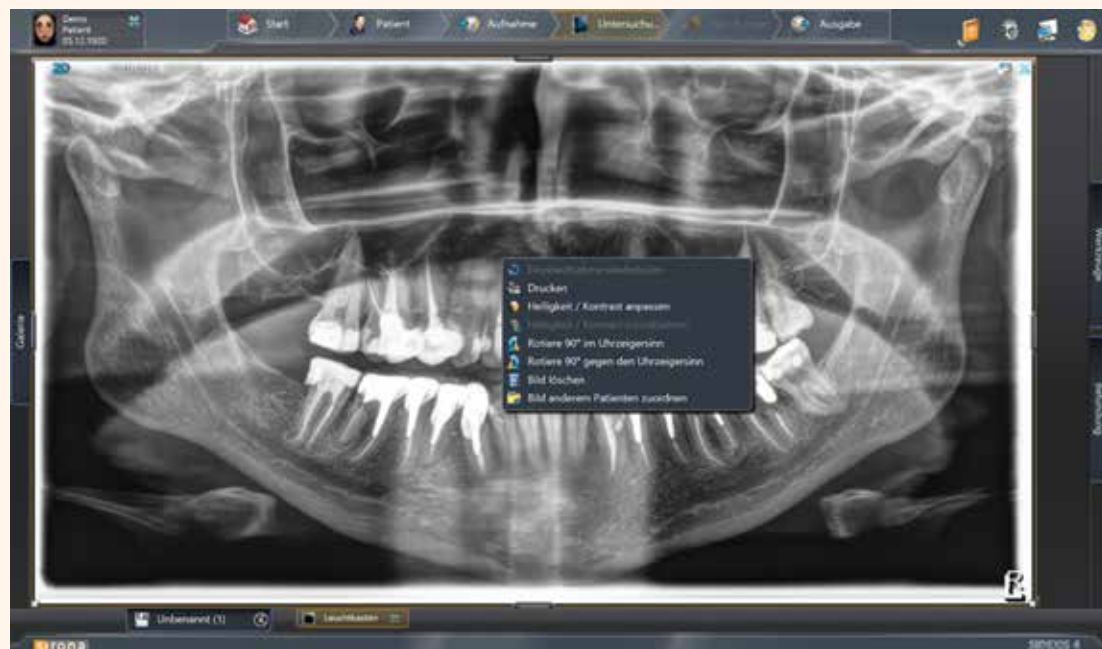

Fig. 1: With SIDEXIS 4.1.3 images can be allocated to another patient.

Dentsply Sirona

Sirona Straße 1
5071 Wals bei Salzburg, Austria
T +43 (0) 662 2450-588
F +43 (0) 662 2450-540
www.dentsplysirona.com

The glow
of the art

BRILLIANT EverGlow™

Universal Submicron Hybrid Composite

Outstanding polishability and gloss retention ←

Brilliant single-shade restorations ←

Ideal handling through a smooth consistency ←

Good wettability on the tooth surface ←



COLTENE

everglow.coltene.com | www.coltene.com

Esthetic replacement of maxillary premolar with immediate implant placement and metal ceramic crown over CAD/CAM abutment

ADA C.E.R.P.® | Continuing Education Recognition Program

Centre for Advanced Professional Practices (CAPP) is an ADA C.E.R.P. Recognized Provider. ADA C.E.R.P. is a service of the American Dental Association to assist dental professionals in identifying quality providers of continuing dental education. ADA C.E.R.P. does not approve or endorse individual courses or instructors, nor does it imply acceptance of credit hours by boards of dentistry.

CAPP designates this activity for 2 CE Credits



mCME articles in Dental Tribune have been approved by:
HAAD as having educational content for 2 CME Credit Hours
DHA awarded this program for 2 CPD Credit Points

By Dr. Larry R. Holt, USA

This article describes treatment to solve a common dental complication (loss of tooth due to vertical root fracture). Contemporary implant therapy and subsequent CAD/CAM laboratory procedures provide an elegant solution to this patient's dental emergency. Treatment was accomplished during a period of approximately six months.

The patient is a healthy, 52-year-old female with an unremarkable medical history. Her dental history and general dental health are excellent. Unfortunately, she suffered a vertical fracture of tooth #5, which necessitated its extraction (Fig. 1).

The treatment plan was for extraction and immediate implant placement with concurrent bone grafting as required. A temporary partial was planned to provide esthetic replacement and to support and shape tissue during the healing process. Final restoration was to be a cemented PFM crown supported by an Atlantis gold hue abutment.

Material selection was based on patient's cross bite occlusion that transitions from normal to cross bite across this particular tooth's occlusal table. Crown and abutment could potentially be subject to occlusal stress due to this transitional relationship.

A restoration that provides maximum strength was desirable for long-term stability of the restoration.

The patient has a thin biotype, and the gold hue abutment provides both strength and the gold color that provides a more natural tissue color.¹ The gold color provides "warmth" of color in the critical transmucosal region. Titanium abutments provide strength but can telegraph a greying affect on thin tissues.

Treatment began with a preoperative appointment to take necessary records (impressions of both arches, facebow transfer, shade taking, bite registration and clinical photography).

Prescription to lab was provided ordering a partial denture fabricated from duracetyl resin and to develop a tooth born surgical guide. Lab was instructed to simulate the extraction site by removing the tooth from the study cast provided. This model was duplicated for fabrication of the two appliances.

Laboratory product was provided to surgeon. Atraumatic extraction was accomplished and immediate implant (Legacy Three, Implant Direct) placed with facial bone grafting (Figs. 2-3).

There was a healing screw placed and site was closed with appropriate membrane and suturing techniques. The unilateral partial was not delivered at time of surgery. Patient was

seen in restorative office, and the partial (Duratek, Drake Precision Laboratories) was modified to provide tissue support and begin development of an ovate tissue site. Partial was delivered uneventfully. These appliances are extremely retentive and not subject to dislodgement or pressure over the implant site during function. Patient was seen at one week for postoperative check and adjustment of temporary appliance (Fig. 4).

Patient was instructed to return to surgical clinic in approximately four months for final evaluation prior to restorative procedures.

Four months after surgery, the patient was seen by surgeon to uncover the implant, remove the healing screw and place a temporary abutment. The temporary partial was adjusted to accommodate the added height of the healing abutment (Fig. 5). Patient was instructed to return to restorative office for definitive restoration of the implant in approximately three weeks.

Patient was appointed with restorative office for evaluation and to develop necessary records for laboratory fabrication of the definitive restoration. Implant site was evaluated and deemed adequately healed to proceed with restorative procedures (Fig. 6).

Healing abutment was removed and a closed tray impression coping was fitted onto the implant (Fig. 7). Radiograph was taken to confirm complete seating of the impression coping. A full-arch impression was taken with heavy body PVS impression material (Panasil Tray Soft, Heavy Body Regular Set, Kettenbach GmbH) (Fig. 8).

Healing abutment was replaced once impression was taken. A bite registration (Futar D Fast Set Kettenbach GmbH), new opposing impression (Silginate plus Panasil Light Body Fast Set, Kettenbach GmbH) and shade map were taken. All clinical product was sent to laboratory along with shade photography and a complete written prescription. A PFM high noble crown and Atlantis gold hue custom abutment were prescribed. The abutment was ordered as tissue contouring with 1 mm deep margin placement circumferentially (Atlantis, Dentsply Implants).

The use of a custom abutment allows modification of transmucosal tissue profile and to ideally position margins. Tissues were previously shaped with the ovate pontic of the temporary partial. The final crown was planned to be chairside custom stained. Lab was cautioned that occlusion on this restoration was in the path of patient's crossbite transition from normal to crossbite.

The laboratory (Drake Precision Dental Laboratories, Charlotte, N.C.) partnered with Atlantis (DENTSPLY

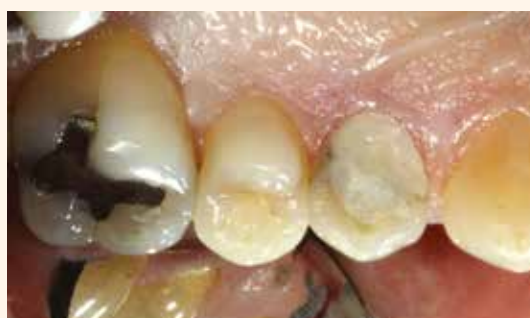

Fig. 1. Fractured tooth. (Photos/Provided by Dr. Larry R. Holt)

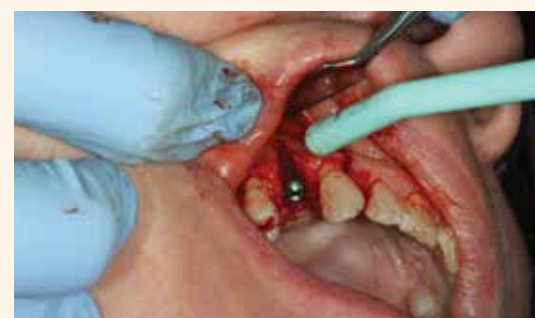

Fig. 2. Immediate implant placement.

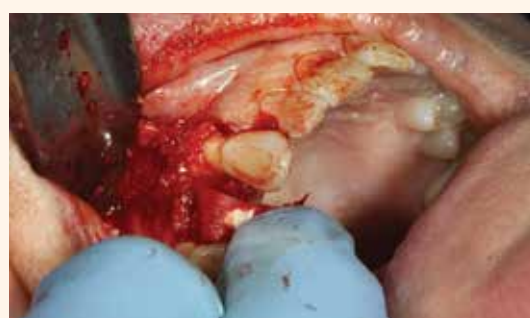

Fig. 3. Bone grafting and membrane placement.

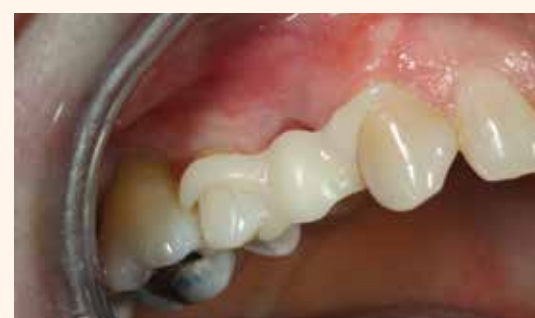

Fig. 4. Temporary Duratek partial.

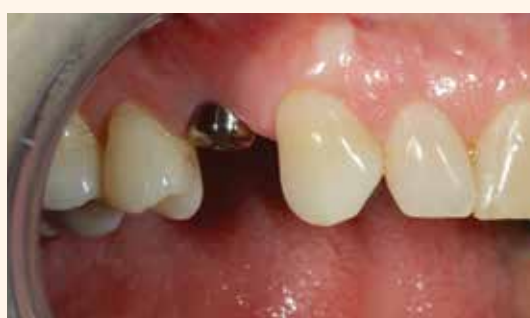

Fig. 5. Healed implant site with healing abutment.

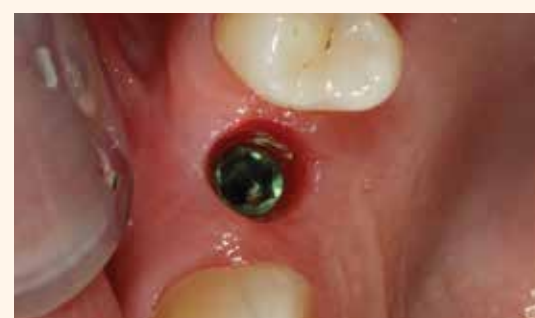

Fig. 6. Wellhealed mucosa.

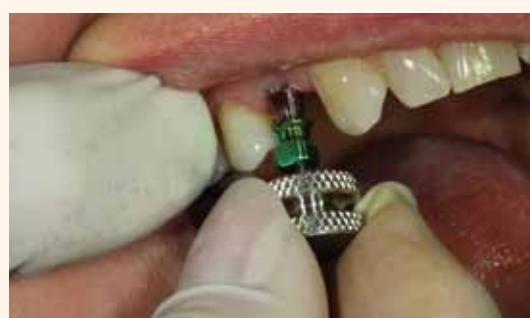

Fig. 7. Placement of impression coping.

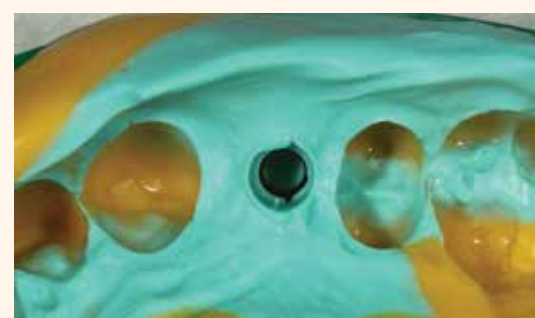


Fig. 8. Final PVS impression.

Implants) for abutment design and milling and then fabricated the PFM crown (Figs. 9-10). The patient was appointed for definitive restoration delivery.

Delivery appointment was uneventful. Healing abutment was removed and the Atlantis abutment was placed (Fig. 11). Because of positive tissue pressure from tissue contouring, the abutment was slowly placed with incremental turns of the retention screw. Tissue blanching was carefully observed.

The abutment was fully seated and, within five minutes, tissue blanching had disappeared. The

Atlantis abutment was torqued to manufacturer's specifications (30 Ncm). A radiograph was taken to confirm final seating of the abutment.

The PFM crown was tried on and interproximal contacts adjusted to allow complete seating of the crown.

Occlusion was marked with appropriate articulation ribbon and adjustments were accomplished, with particular attention to functional path and centric contacts.

The final occlusion respected the cross bite while providing a light occlusal contact that became normal in intensity upon biting force.² All func-

tional contact was adjusted to be in minimal contact during excursions. Adjacent teeth provided partial group function.

Once all clinical adjustments were done, a laboratory technician was consulted for final shade matching. The initial shade was very close to ideal.

The technician accomplished minor modifications (minimal characterization staining and reduction in final surface gloss). Proximal contacts and occlusal table were pol-

◀Page 8

ished after final glazing.

The crown was lined with silicone tape and then bite registration material was injected into the crown to fabricate a cementation jig (Fig. 12).³ This step is very important to avoid excess cement extrusion during final seating of the restoration.⁴

All pre-cementation procedures were completed, including approval by patient of both esthetics and bite comfort. Abutment screw access hole was sealed with silicone tape, respecting the external contours of the abutment to allow complete seating of the restoration. This is a critical step to maintain patency for future access to retention screw.

The crown was steam cleaned and thoroughly dried. Intraorally, the abutment was thoroughly cleaned and dried in preparation for cementation procedures. Attending dental assistant maintained cheek retraction and dry field.

The walls of the crown were lined with implant cement (Dental Implant Cement, radiopaque, Premier). The crown was then seated on the previously fabricated cementation jig to extrude excess cement.

Cement adaptation to internal walls of crown was confirmed and the crown was seated over the custom abutment. Excess cement was removed by combination of hand instrumentation and dental floss after initial cement setting.

The crown was left under biting pressure with cotton roll over occlusal table for five more minutes to allow for cement to fully set. Meticulous inspection of sulcus was accomplished to remove any vestige of implant cement. Postoperative radiograph was taken to evaluate complete seating of crown and to confirm removal of any excess radiopaque cement. Occlusion was confirmed and patient was dismissed. One-week recall was accomplished to confirm occlusion and to reevaluate soft-tissue response to the restoration.

This case study reveals the potential for implant supported tooth replacement. Esthetic result was excellent, and final gingival contours were consistent with adjacent denti-

tion. The tissue color was natural and did not reveal any hint of the underlying implant or abutment. Restoration margins were concealed within the gingival sulcus. This treatment provided an elegant solution for this all-too-common dental emergency. The patient was extremely pleased with the result (Figs. 13-15).

Note: The author would like to express gratitude to Drake Precision Dental Laboratories (Charlotte, N.C.) for all services provided for this treatment. In addition, Dr. Todd Engle, DDS, (Charlotte, N.C.) provided extraordinary care during extraction and immediate placement of implant.

References

- 1) Priest, Optimal Results in the Esthetic Zone with CAD/CAM Implant Abutments: A Patient Example Inside Dentistry; 2006;2(3):70-73.
- 2) Weinberg LA. Reduction of implant loading with therapeutic biomechanics. Implant Dent. 1998;7:277-285.
- 3) Wadhwani, Pineyro, Technique for controlling the cement for an implant crown, J Prosthet Dent, 2009; 102: 57-58.
- 4) Chee, Duncan, Afshar, Moshaverinia Evaluation of the amount of excess cement around the margins of cement-retained dental implant restorations: the effect of the cement application method. J Prosthet Dent. 2013 Apr;109(4):216-221. [DOI](#)



Larry R. Holt, DDS, FICD has graduated from the UNC School of Dentistry in 1978. He was in private practice from 1978-2008. Since 2008, he has been the director of clinical education and research at Drake Precision Dental Laboratories in Charlotte, N.C.

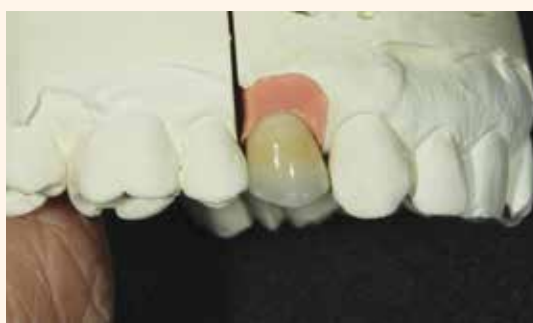

Fig. 9. Crown and abutment on analog model.

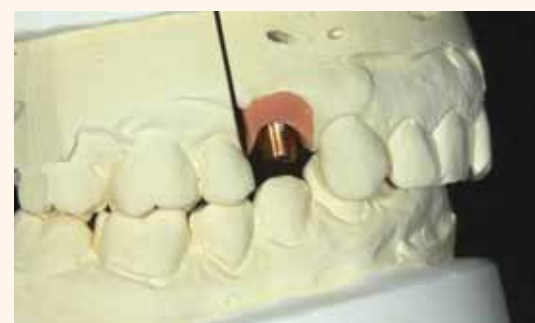


Fig. 10. Gold hue Atlantis abutment on analog model.

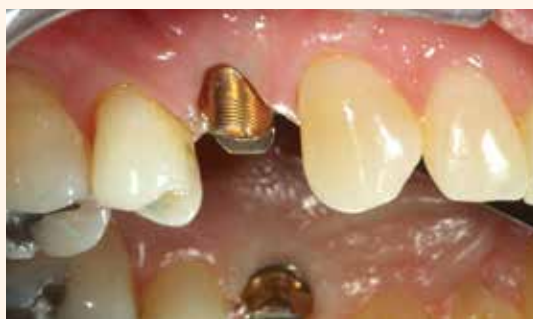

Fig. 11. Gold hue Atlantis abutment in place.

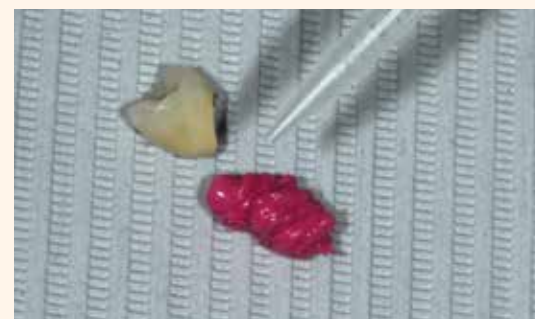

Fig. 12. Cementation jig.

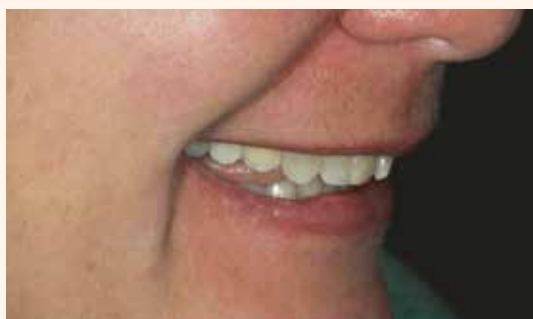

Fig. 13. Final patient lateral smile.

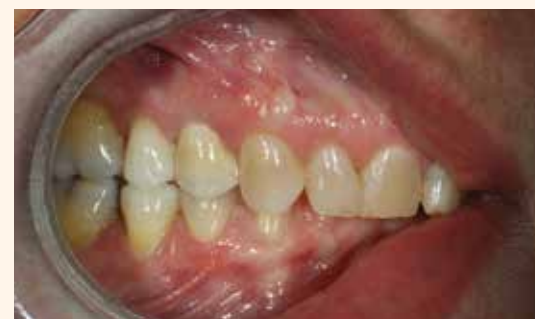

Fig. 14. Final restoration retracted.

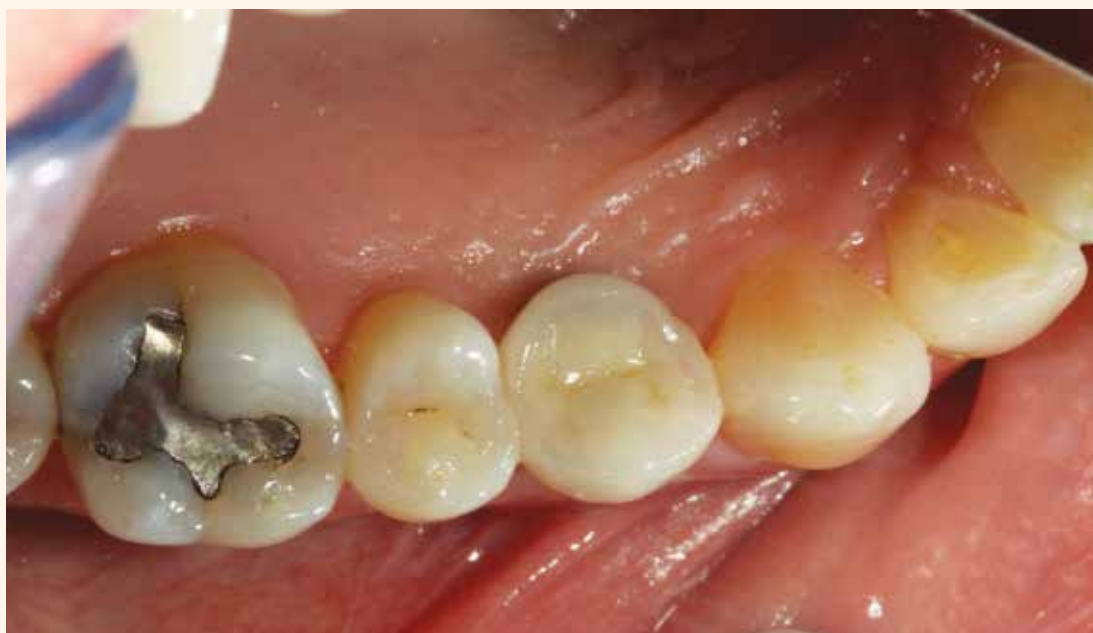

Fig. 15. Final restoration occlusal view.

mCME SELF INSTRUCTION PROGRAM

CAPPmea together with Dental Tribune provides the opportunity with its mCME - Self Instruction Program a quick and simple way to meet your continuing education needs. mCME offers you the flexibility to work at your own pace through the material from any location at any time. The content is international, drawn from the upper echelon of dental medicine, but also presents a regional outlook in terms of perspective and subject matter.

Membership

Yearly membership subscription for mCME: 900 AED

One Time article newspaper subscription: 250 AED per issue. After the payment, you will receive your membership number and allowing you to start the program.

Completion of mCME

- mCME participants are required to read the continuing medical education (CME) articles published in each issue.
- Each article offers 2 CME Credit and are followed by a quiz Questionnaire online, which is available on www.cappmea.com/mCME/questionnaires.html.
- Each quiz has to be returned to events@cappmea.com or faxed to: +97143686883 in three months from the publication date.
- A minimum passing score of 80% must be achieved in order to claim credit.
- No more than two answered questions can be submitted at the same time
- Validity of the article – 3 months
- Validity of the subscription – 1 year
- Collection of Credit hours: You will receive the summary report with Certificate, maximum one month after the expiry date of your membership. For single subscription certificates and summary reports will be sent one month after the publication of the article.

The answers and critiques published herein have been checked carefully and represent authoritative opinions about the questions concerned.

Articles are available on www.cappmea.com after the publication. For more information please contact events@cappmea.com or +971 4 3616174

FOR INTERACTION WITH THE AUTHORS FIND THE CONTACT DETAILS AT THE END OF EACH ARTICLE.



ذي مـول

ICONIC LOCATION,
BREATHTAKING VIEWS



THE MALL



جـربة فـريدة

WE ARE HERE

REFRESHINGLY DIFFERENT

Beautiful views of Burj Al Arab, facing Jumeirah Beach Hotel, located on the vibrant Jumeirah Beach Road

شارع شاطئ الجميرا ،
مقابل فندق جميرا بيتش
www.themall.co.ae

[f](#) [t](#) [i](#) TheMallJumeirah
+971 4 348 48 48 | info@themall.co.ae

Jumeirah Beach Road,
opposite Jumeirah Beach Hotel
www.themall.co.ae